Pathology I Images

Cell Injury

It is against copyright laws to make *electronic or printed* copies of these slides!!

1. Patient: central cyanosis
The patient on the left has a markedly cyanotic (blue) tongue compared to the normal patientï¿½s tongue on the right. Central cyanosis is due to an increased amount of unoxygenated hemoglobin (Hgb) in the blood (called deoxyhemoglobin). This translates into a decrease in the oxygen saturation of blood (percentage of the heme groups on Hgb occupied by oxygen). Central cyanosis is due to any cause of hypoxemia (e.g., respiratory acidosis, ventilation/perfusion/diffusion problems in the lungs, right to left shunting of blood in cyanotic congenital heart disease), since a low arterial PO_2 automatically lowers the amount of O_2 that diffuses into the RBC to bind to heme. Peripheral cyanosis refers to vasoconstriction of the blood vessels in the skin with central shunting of the blood (e.g., hypothermia). The skin is cyanotic, however the mucous membranes are pink. **(Ci001)**

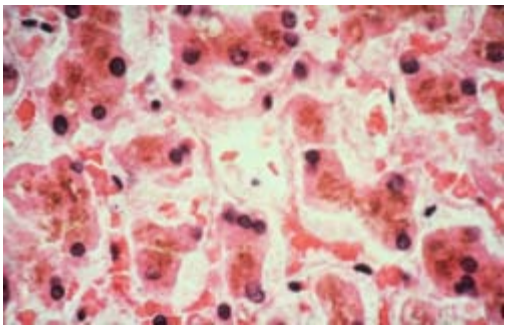

2. Liver biopsy: lipofuscin
The brown pigment noted in the hepatocytes (arrow) represents lipofuscin (wear and tear pigment). Lipofuscin is the end product of free radical injury of cells and autophagy (destruction of cell organelles and structural proteins in cells undergoing atrophy). Grossly, an excess of lipofuscin produces a brown discoloration, hence the term **brown atrophy**. Lipofuscin is commonly found at autopsy in elderly patients. **(Ci201)**

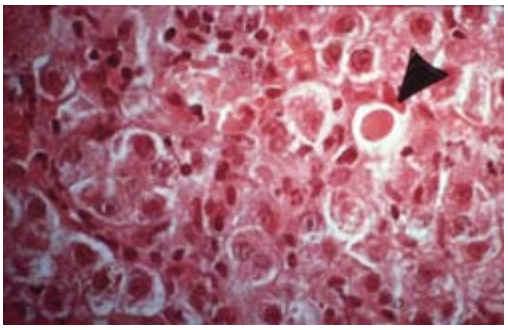

3. Liver: viral hepatitis with apoptosis
The arrow points to an anucleate, deeply eosinophilic staining cell that is retracted away from the other cells. The last phase of destruction of this cell will be fragmentation into apoptotic bodies containing bound packets of organelles which will be phagocytosed and destroyed in the lysosomes of macrophages and neighboring cells. Note that there is no inflammatory infiltrate around the cell. **(Ci202)**

4. Heart: pale infarction with coagulation necrosis
The anterior part of the heart is at the bottom of the slide. The left ventricle is on your left and the

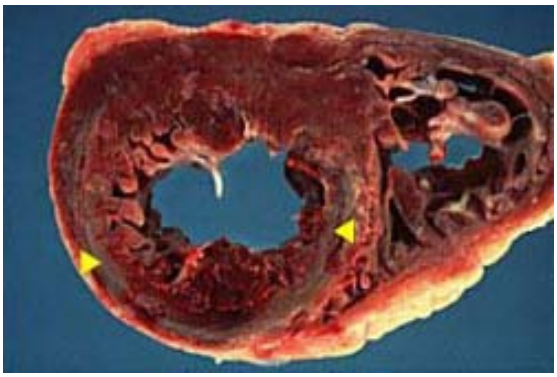

right ventricle on your right. The arrows point to a pale infarct in the entire anterior part of the heart and anterior two-thirds of the interventricular septum. The patient had a platelet thrombus in the left anterior descending coronary artery, which supplies blood in the same distribution outlined by the infarction. **Coagulation necrosis** is the underlying pathologic process. The infarct is pale owing to the dense consistency of muscle so that extravasated RBCs from necrotic vessels remain localized and are unable to percolate through the tissue. **(Ci002)**

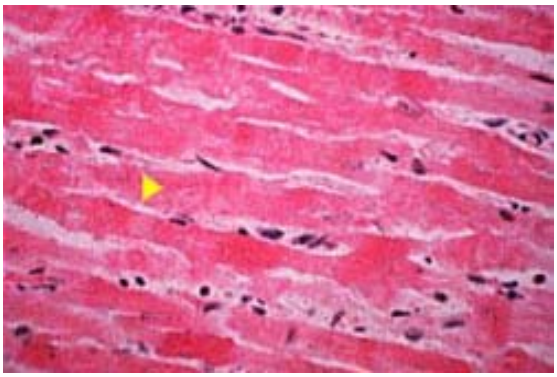

5. Heart: coagulation necrosis
Recall that in coagulation necrosis, the accumulation of lactic acid in the hypoxic tissue causes denaturation of the proteins and enzymes in the cell. Hence, the cells retain their basic outline but cannot be autodigested owing to the denaturation of their enzymes. Neutrophils from outside the area of infarction will have to destroy the tissue, which will eventually be replaced by collagen in a scar. Note that the cells are deeply eosinophilic (see arrow). Nuclei and cross striations are not evident. **(Ci003)**

6. Toe: dry gangrene in a patient with diabetes mellitus (coagulation necrosis)
The big and little toe are blackened. A **pressure ulcer** is noted overlying the metatarsal head of the big toe. The cause of the gangrene is artherosclerotic occlusion of the popliteal artery. This is a **dry gangrene** with predominantly coagulation necrosis since there is no evidence of exudate indicating an anaerobic infection. In the latter case, the predominant type of necrosis is liquefactive necrosis, since infection with neutrophils is present. This is called **wet gangrene**. **(Ci206)**

7. Spleen: pale infarction
Note the roughly wedge shaped pale area of infarction extending to the surface of the splenic capsule (see arrow). The infarct is pale since the tissue texture of the spleen does not allow RBCs to diffuse easily through the tissue. Most causes of splenic infarctions originate from embolization of clot material or bacterial vegetations from the left heart into the aorta with eventual deposition in distal organs. If the splenic vein was thrombosed, the infarct would have been hemorrhagic. **(Ci004)**

8. Small bowel: transmural infarction (hemorrhagic infarction)
Note the dark red hemorrhage into the wall of the small bowel and the normal appearing proximal and distal bowel. The small bowel is the most common segment of bowel that infarcts owing to the single

blood supply- superior mesenteric artery. A thrombus overlying a proximal atherosclerotic plaque at the orifice of the artery or embolization from the left heart are common causes of infarction of the small bowel. **(Ci005)**

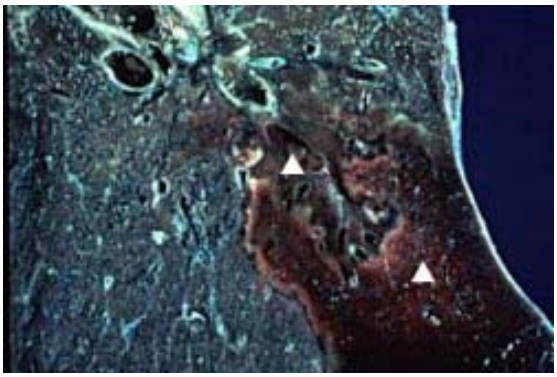

9. Lung: gross of a pulmonary infarction (hemorrhagic infarct)
Note the wedge-shaped area of hemorrhage extending to the pleural surface (see arrow). This is an example of a hemorrhagic infarction and is most often secondary to emboli originating from clots that developed in the femoral veins in the legs. Most venous clots initially develop in the deep veins of the calf, however, as they propagate proximally into the femoral venous system, they break off and embolize to the lungs. The embolized vessel is visible at the apex of the infarct (see arrow). Recall that hemorrhagic infarcts usually develop in tissues that have a loose texture, so that blood extravasating from necrotic vessels can percolate through the tissue. The wedge-shaped infarct is due to the parallel branching of the pulmonary vessels. Hence, a proximally located obstruction in the lumen of a pulmonary vessel affects the blood flow to a large cross-sectional area of branching vessels that are distal to the obstruction (perfusion defect). The same concept applies to a mucous plug in a terminal bronchiole. Recall that the small airways also branch in parallel, hence a proximally located plug affects a large cross-sectional area of distally branching airways. **(Ci006)**

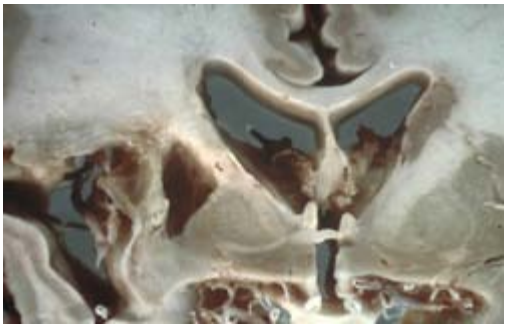

10. Brain: old artherosclerotic stroke with cystic cavity (liquefactive necrosis)
Note the cystic cavities in the brain. Recall that infarction in the brain is not coagulative but liquefactive necrosis owing to the lack of good structure in the brain and the abundance of lysosomes in neuroglial cells. **(Ci210)**

Previous | Next

Return to Top | Return to Image Index

Pathology I Images

Cell Injury

It is against copyright laws to make *electronic or printed* copies of these slides!!

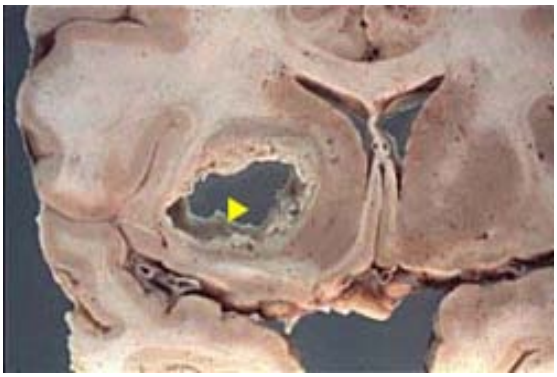

11. Brain: cerebral abscess
Note the cavitary lesion in the brain, which is lined by a shaggy, necrotic material (see arrow). Cerebral abscesses, like cerebral infarctions, are examples of liquefactive necrosis. Cerebral abscesses may be due to local extension of an infection (e.g., mastoiditis, sinusitis) or hematogenous spread of a bacteria.
(Ci007)

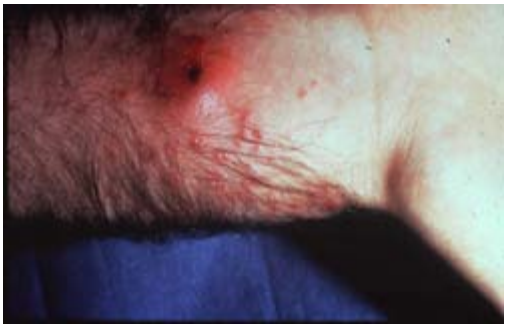

12. Wrist: abscess due to *Staphylococcus aureus* (liquefactive necrosis)
Note the raised, erythematous area on the wrist with a central area of draining from a **sinus tract**. Recall that *S. aureus* is a gram positive coccus that has coagulase. Coagulase converts fibrinogen into fibrin, which keeps the infection localized. This is an example of **liquefactive necrosis. (Ci209)**



13. Lung: gross of lung exhibiting bronchopneumonia
Note the patchy yellow, raised areas throughout the lung parenchyma (see arrow). These represent collections of neutrophils in the pulmonary parenchyma that first caused acute inflammation involving the small airways (acute bronchitis) and spilled over into the surrounding lung parenchyma causing bronchopneumonia. The progression of a bronchitis into the lung parenchyma is called bronchopneumonia. *Streptococcus pneumoniae*, a gram positive diplococcus, is the most common pathogen responsible for community acquired bronchopneumonia. Bronchopneumonia may cause liquefactive necrosis, since neutrophils are present in the tissue and producing enzymes which may destroy the tissue. **(Ci008)**

14. Lymph node: localized granuloma (caseous necrosis) in a patient with tuberculosis
Note the very well circumscribed eosinophilic staining granuloma. In the middle of the granuloma, the pink staining material is acellular. This

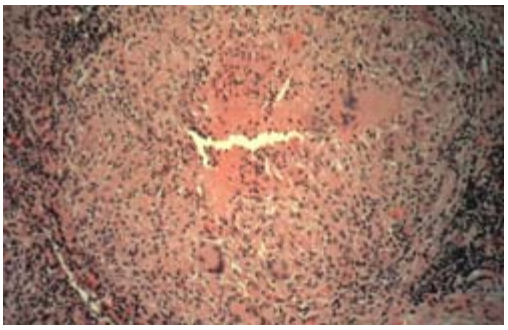

represents **caseous necrosis**. Note the multinucleated giant cells at 2 and 7 o'clock. The following slide is a high power view of the granuloma. **(Ci211)**

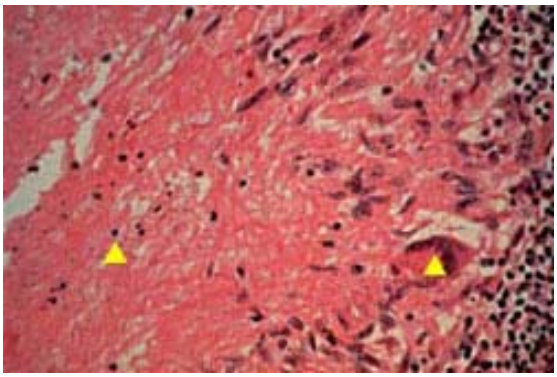

15. Lymph node: localized granuloma (caseous necrosis) in a patient with tuberculosis
Note the eosinophilic appearing necrotic center of the granuloma (see arrow) and the wall of the granuloma containing a multinucleated giant cell (see arrow). The pink staining cells in the wall represent activated macrophages (called epithelioid cells). The interaction of macrophages containing processed TB organisms causes the helper T cells to release gamma interferon, which activates the macrophage and allows it to kill the TB. The cell walls of TB are rich in lipid, which causes the necrotic debris to have a cheezy appearance, hence the term caseous necrosis. **Multinucleated giant cells** represent macrophages fused together. Granulomas are an example of type IV cellular immunity. **(Ci011)**

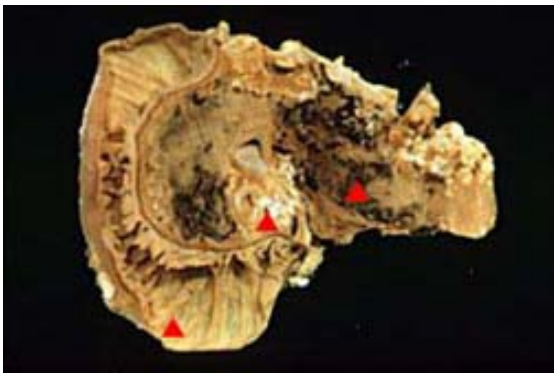

16. Pancreas: acute pancreatitis with enzymatic fat necrosis
Note the C shaped pancreas on the left of the slide. The duodenum encompasses the head of the pancreas and the body and tail extend to the right. Note the chalky white areas (see arrows) representing calcium interacting with fatty acids derived from breakdown of fat by pancreatic lipases. This is called **saponification**. The calcification is also an example of dystrophic calcification, which is calcification of damaged tissue. Pancreatic calcifications are visible on x-ray, ultrasound, or CT scans. The red areas in the pancreas (see arrows) represent hemorrhage due to rupture of vessels destroyed by elastases in the pancreas. Acute pancreatitis is most often due to alcohol and biliary tract disease. Serum lipase and amylase are both elevated. Pain radiates into the back since the organ is retroperitoneal. **(Ci010)**

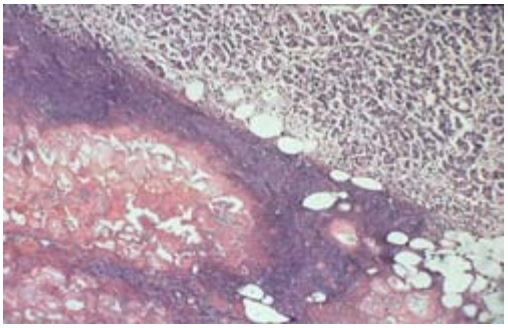

17. Pancreas: histologic section of enzymatic fat necrosis in an alcoholic with acute pancreatitis
The blue staining area represents enzymatic fat necrosis where calcium has bound with fatty acids to form a calcium salt. These can be visualized on x-ray, particularly after repeated attacks of acute pancreatitis. Calcium deposits in necrotic tissue are called **dystrophic calcification**. **(Ci213)**

18. Arteriole: fibrinoid necrosis
Note the pink staining material in the wall of this

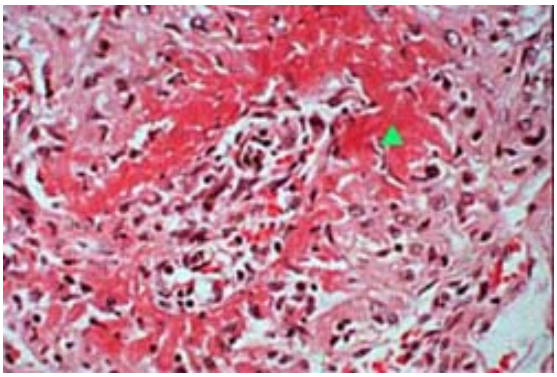

arteriole (see arrow) that has been totally destroyed. This is an example of small vessel vasculitis, the majority of which are due to type III immunocomplex disease. Immunocomplexes deposit in the vessel and activate the alternative complement system, which releases C5a, a chemotactic agent that attracts neutrophils. The neutrophils destroy the vessel. The pink staining material represents protein from the plasma in the vessel lumen. Fibrinoid necrosis is the **necrosis of immune disease** and is seen in the vegetations associated with acute rheumatic fever and inflammation associated with many collagen vascular diseases. **(Ci012)**

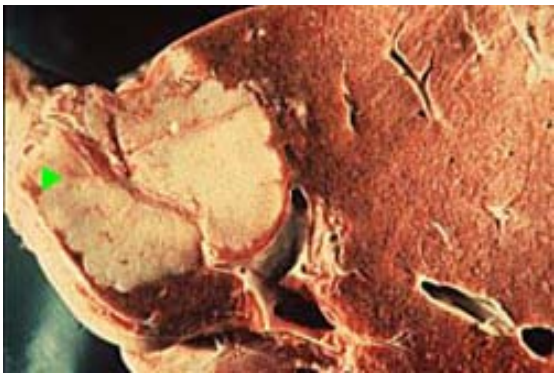

19. Liver: gumma in tertiary syphilis
Note the white nodular lesions in the liver parenchyma (see arrow). Gummas have a rubbery consistency. They are examples of **gummatous necrosis**, which is unique to **tertiary syphilis**. There is nothing on gross examination of these masses that would distinguish them from primary or metastatic cancer, hence a microscopic section and history would be necessary to make the correct distinction. **(Ci013)**

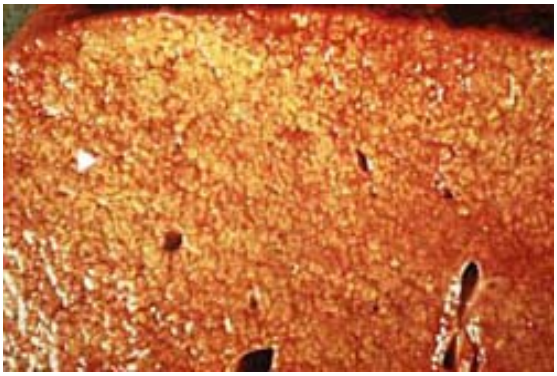

20. Liver: cirrhotic liver with fatty change
Note the diffuse nodularity of the liver and the yellowish discoloration representing fatty change. This patient was most likely an alcoholic, since alcohol is the most common cause of fatty change and cirrhosis of the liver. Refer to the class notes for the pathophysiology of fatty change. **(Ci017)**

Previous | Next

Return to Top | Return to Image Index

Pathology I Images

Cell Injury

It is against copyright laws to make *electronic or printed* copies of these slides!!

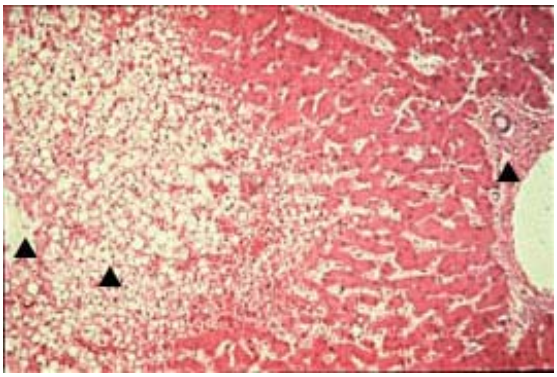

21. Liver: fatty change secondary to alcoholism

The accumulation of triglyceride (TG) in the liver or fatty change is a reversible reaction induced by a number of different agents, the most common of which is alcohol. Its favored location in hepatocytes around the **central veins** in the liver (see arrow on left side of the slide) is closely linked to the mechanics of blood flow from the portal triads to the central vein. Hepatic artery and portal vein tributaries in the portal triads (see arrow on the right side of the slide) discharge blood into the liver sinusoids, which are located in-between cords of hepatocytes. The sinusoidal blood drains into the central veins, which coalesce to form the hepatic vein. Hepatocytes located around the central veins receive less O_2 and other nutrients than those surrounding the more peripherally located portal triads, which benefit by having the first exposure to the blood. This structural arrangement renders the central vein-associated hepatocytes more susceptible to drugs or chemicals, whose metabolic products form free radicals or toxic substances, also fatty change secondary to alcohol and tissue hypoxia. Note how the fatty change (see middle arrow) is located around the central veins rather than the portal triad.

In general, the two primary mechanisms involved in the production of fatty change in the liver relate to (1) increased synthesis of TG secondary to an increase in key substrates, such as fatty acids and glycerol 3-phosphate, and (2) problems in the secretion of TG from

the hepatocyte into the plasma (e.g., deficiency of apolipoproteins). Sources of fatty acids include excess lipolysis of adipose tissue (e.g., corticosteroids, starvation, alcohol), increased production of acetate (a product of alcohol metabolism), and increased synthesis of fatty acids from acetyl CoA (a product of alcohol metabolism). **Refer to course notes for Biochemistry discussion. (Ci018A)**

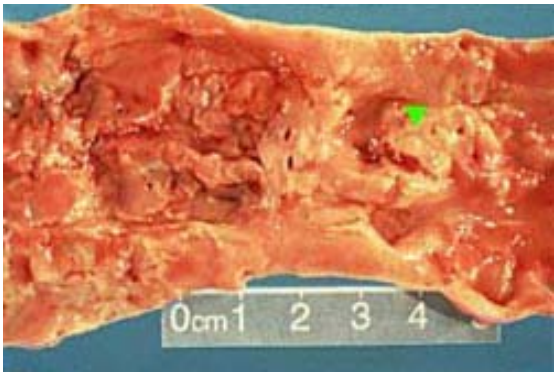

22. Aorta: aorta with complicated atheromatous plaques

Note the red clots, fissured endothelial surface, and raised plaque-like structures from the surface of the aorta (see arrow). This is an example of advanced atherosclerosis. This patient had an increase in **low-density lipoprotein (LDL)**, the lipoprotein fraction that carries the majority of **cholesterol**. In the cardiovascular lectures, you will be introduced to the reaction to injury theory of atherosclerosis that is ultimately responsible for the changes noted in this slide. The fibrofatty plaques that normally occur with the reaction to injury on the aorta and muscular arteries are commonly calcified. Calcification of damaged tissue is called **dystrophic calcification**. Calcification significantly impairs the elasticity of the aorta, hence it cannot expand with blood during systole nor can it contract and help send the blood distally. **(Ci019)**

23. Patientï¿½s with lipid deposits: collage of lipid deposits in the skin

In the left upper corner of the slide, note the papular yellow structures representing triglyceride (TG) deposited in the skin in a patient with an excess of very low density lipoprotein (VLDL). This commonly occurs in diabetic ketoacidosis. The patient in the right upper corner has deposits of cholesterol in the **Achilles tendons (tendon xanthoma)**. This lipid deposit is pathognomonic for the autosomal disease called **familial hypercholesterolemia**. In this fatal disorder, the LDL receptors are absent, hence LDL accumulates in the blood. The patient in the lower frame has cholesterol deposits in the eyelids

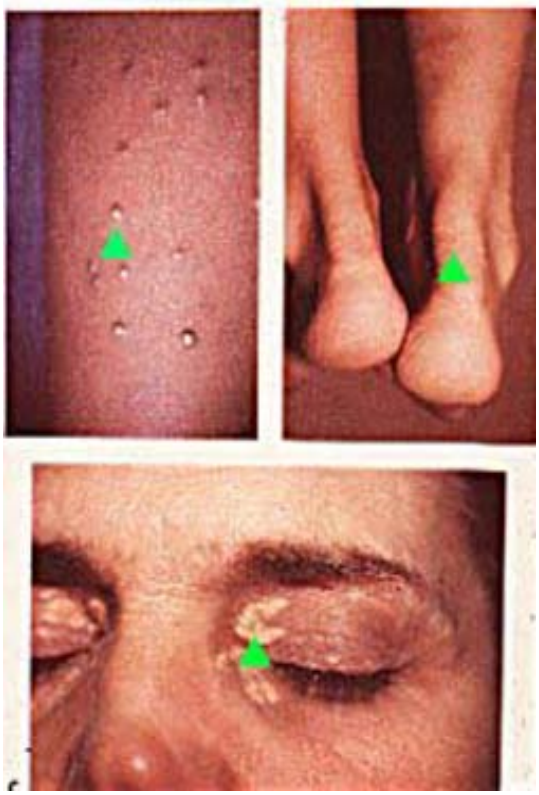

called **xanthelasmas**. These commonly occur in patients with very high cholesterol levels. **(Ci020)**

24. Patient: xanthelasma
This is a close-up of the patient in the previous slide.
(Ci021)

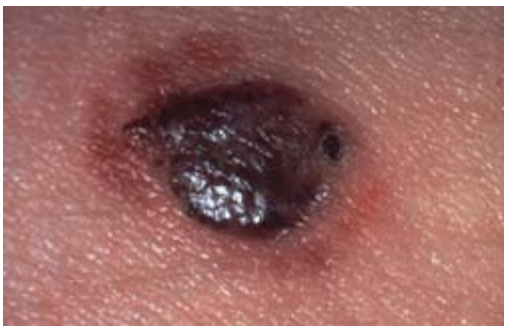

25. Skin: malignant melanoma
Malignant melanomas are malignancies of melanocytes, which contain melanin pigment. **(Neo203)**

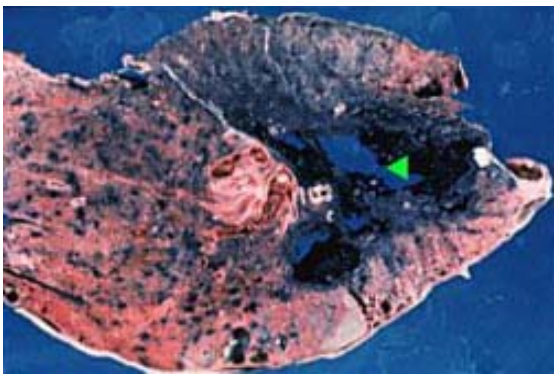

26. Lungs: anthracotic pigment in a patient with "black lung" disease
Note the heavy deposition of black pigment in this lung (see arrow) from a patient with coal workerï¿½s pneumoconiosis (dust-related pulmonary disease). The large spaces in the apex of this lung represent **emphysema** secondary to damage associated to the respiratory bronchioles from the excess anthracotic pigment. **"Black lung"**

disease is a crippling disease and is associated with an increased incidence of TB.
(Ci028)

27. Lymph nodes: anthracotic pigment deposition
Note the diffuse black pigmentation in the lymph nodes. This gross specimen could easily be mistaken for melanin pigment in a patient with metastatic malignant melanoma. Recall that **anthracotic pigment is coal dust** and is commonly found in coal miners or in inhabitants of cities that have a great amount of pollution. Pollutants that are in the air and breathed into the lungs often produce disease. **(Ci029)**

28. Pancreas: hemochromatosis
The pancreas at the top of the slide is stained with Prussian blue and the one on the bottom of the slide is its unstained appearance in this patient who had hemochromatosis. In the unstained pancreas, note the increase in fibrous tissue replacement of the gland, which is a reaction to injury secondary to free radicals generated by the excess iron. Both exocrine and endocrine deficiency eventually occur, the former leading to maldigestion and the latter to diabetes mellitus. **(Ci024)**

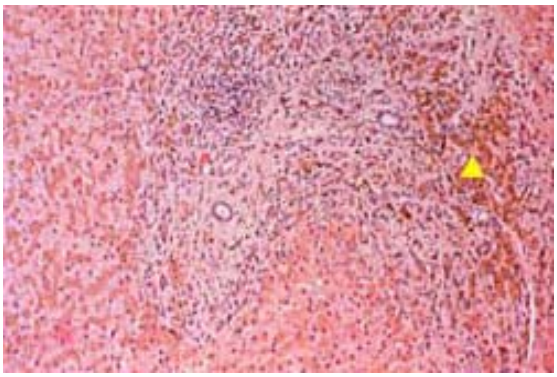

29. Liver: microscopic section of liver in hemochromatosis
Note the golden brown pigment in the liver parenchymal cells (see arrow) and the inflammatory infiltrate. Recall that iron enhances the synthesis of hydroxyl free radicals, which in turn damage the tissue. In this case, the damage is in the form of fibrosis, which results in cirrhosis of the liver. Hemochromatosis is the second most common genetic disease (AR inheritance) in the United States. It is due to an unrestricted reabsorption of iron from the duodenum. **(Ci023)**

30. Sputum: rusty colored sputum (left), hemoptysis (right)
Rusty colored sputum implies the breakdown of RBCs and their phagocytosis by alveolar macrophages (e.g., chronic pulmonary edema). Alveolar macrophages are normally in the respiratory unit in the distal airways. Hemoptysis, or coughing up blood, implies a bleeding event that is

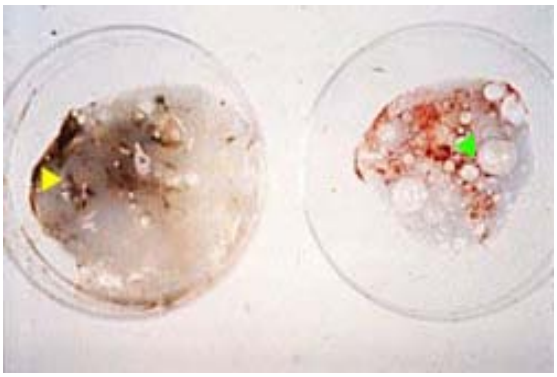

more proximal than the small airways (e.g., bronchogenic carcinoma). **(Ci026)**

Previous | **Next**

Return to Top | **Return to Image Index**

Pathology I Images

Cell Injury

It is against copyright laws to make
electronic or printed copies of these slides!!

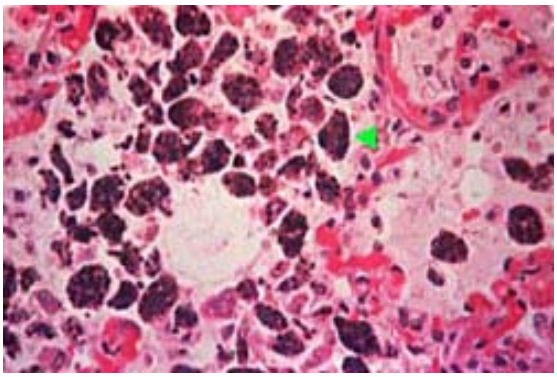

31. Lungs: chronic pulmonary congestion with hemosiderin laden alveolar macrophages
Note the rusty colored material in the alveolar macrophages. This patient had **chronic pulmonary edema** from left heart failure. The increased hydrostatic pressure in the pulmonary capillaries causes them to rupture, hence releasing RBCs into the alveoli. Alveolar macrophages phagocytose the RBCs and hemosiderin accumulates in the cytoplasm. In the setting of heart failure, these cells are called **heart failure cells**, which are frequently expectorated and produce a rusty colored sputum. **(Ci025)**

32. Patientï¿½s lower legs: stasis dermatitis of the left lower leg and secondary varicose veins
In the lower extremities, the venous blood flows from the superficial varicose veins through penetrating branches into the deep veins of the leg and back to the heart. Valves prevent reflux of blood back to the superficial system and keep the blood moving back towards the heart. However, around the ankles, the flow of blood is from the deep veins through penetrating branches back into the superficial system. In this patient, note the brownish discoloration of the lower leg (see arrow), ulceration of the skin, and the dilated superficial saphenous veins proximal to the discoloration (top arrow). The series of events that produced these changes began with a deep vein thrombosis with a backup of venous blood under pressure into the small penetrating branches around the ankles. Initially, the increased hydrostatic pressure produces swelling of the tissue. This is followed by rupture of the blood vessels with extravasation of blood into the surrounding tissue. With the eventual breakdown of RBCs in the subcutaneous tissue, hemosiderin is left behind, hence the brown discoloration of the tissue. The stagnated venous blood in the ankle also leaves very little oxygen and nutrients for the tissue, hence the eventual ulceration of the skin surface as noted in the area of discoloration. The back up of venous pressure also increases the blood flow back into the superficial saphenous system leading to dilatation of these veins and eventual

impairment of their valves. This is called secondary varicose veins (secondary implying that the disease did not begin in the superficial system but in the deep venous system). **(Ci022)**

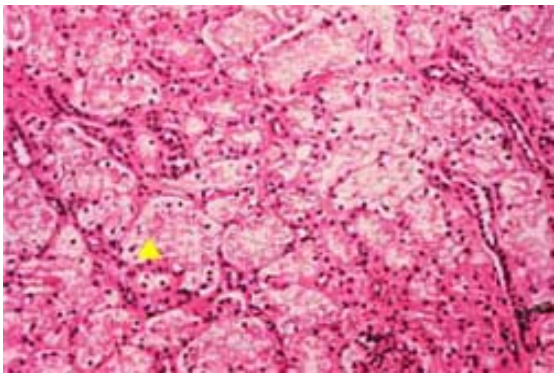

33. Kidneys: increased glycogen deposition in the renal tubules

Note the clear spaces in the renal tubules due to increase in glycogen (see arrow). That the clear spaces represent glycogen must be documented with a PAS stain, since cellular swelling in early tissue hypoxia can also produce this change. This patient has von Gierkeï¿½s disease, an autosomal recessive disease where glucose 6-phosphatase, a gluconeogenic enzyme, is deficient. Deficiency of the enzyme leads to a low glucose (fasting hypoglycemia) and a distal buildup of glucose 6-phosphate, which is the substrate from which glycogen is synthesized. Since gluconeogenic enzymes are in the liver and kidney, the glycogen accumulation primarily occurs in these organs. **(Ci030)**

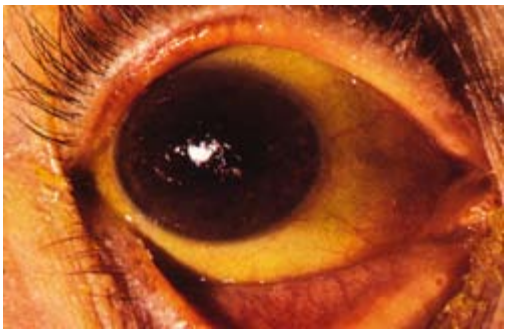

34. Patient eyes: Scleral icterus

Note the yellow discoloration of the sclera. Either unconjugated on conjugated bilirubin can produce this change. The sclera contains abundant elastic tissue, which has a high affinity for bilirubin. Bilirubin is primarily a breakdown product of macrophage destruction of senescent RBCs. **(Hep200)**

35. Aortic valve: bicuspid aortic valve with dystrophic calcification leading to aortic stenosis

Note that the aortic valve has two rather than three cusps. This is a **congenital bicuspid aortic valve**. Since two cusps are doing the job of three cusps, they are damaged over time and develop dystrophic calcification (see arrow), which narrows the orifice of the valve leading to stenosis. **Aortic stenosis** results in problems with opening of the valve and the ejection of blood during systole. **Left ventricular hypertrophy** with concentric pathologic hypertrophy is a response to the valve stenosis. **(Ci031)**

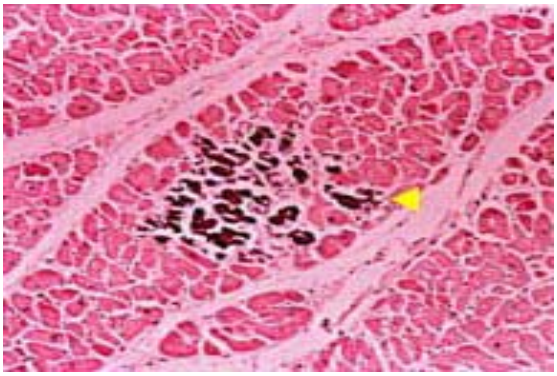

36. Muscle: metastatic calcification

Note the blue-black deposits of calcium in apparently normal muscle (see arrow). This patient had **primary hyperparathyroidism** with an increase in calcium leading to metastatic calcification of normal tissue. If metastatic calcification occurred in the heart or the basement membrane of the tubules, the patient could develop heart block or renal failure **(nephrocalcinosis)**, hence metastatic calcification may be dangerous. **(Ci032)**

37. Peripheral blood smear: spherocytes

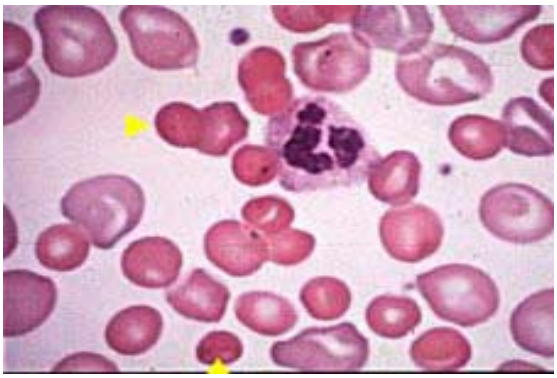

Note the **dense RBCs** without a central area of pallor (see arrow). Since normal RBCs are biconcave discs with a thin central region containing less hemoglobin than the thicker edges of the RBC, an RBC that is a sphere is completely filled with hemoglobin, hence the **absence of a central area of pallor**. Spherocytes have less RBC membrane than a normal RBC due to a **defect in spectrin** in the cell membrane. There are many causes of spherocytes in the peripheral blood besides congenital spherocytosis, such as autoimmune hemolytic anemia, ABO hemolytic disease of the newborn, to name a few. The blue staining RBCs in the peripheral blood represent young RBCs with residual RNA (reticulocytes). **(Ci034)**

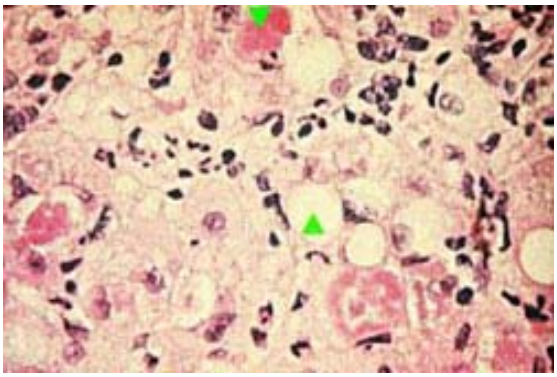

38. Liver biopsy: Mallory bodies in alcoholic hepatitis

Note the spaces in the liver biopsy representing **fatty change** (see arrow) and the pink staining material in the hepatocytes (see arrow) representing Mallory bodies. Mallory bodies represent damaged **keratin intermediate filaments** that have been **"ubiquinated"** by ubiquitin, hence marked for destruction. An acetaldehyde-protein complex is responsible for the damage. Mallory bodies are most commonly seen in the setting of an alcoholic with fever, neutrophilic leukocytosis, and painful hepatomegaly, the latter representing alcoholic hepatitis. **(Ci033)**

39. Brain: atrophy

Note the loss of brain mass, which causes separation of the gyri and sulci. This is most commonly caused by **atherosclerosis** of the internal carotid artery. Chronic tissue hypoxia causes the neurons in layers 3, 5, and 6 of the cerebral cortex to undergo **apoptosis**. Drop out of these neurons causes a loss in brain mass, which is evident in this slide. Other causes include degeneration of the neurons in Alzheimer's disease or destruction of neurons by infection. **(Ci035)**

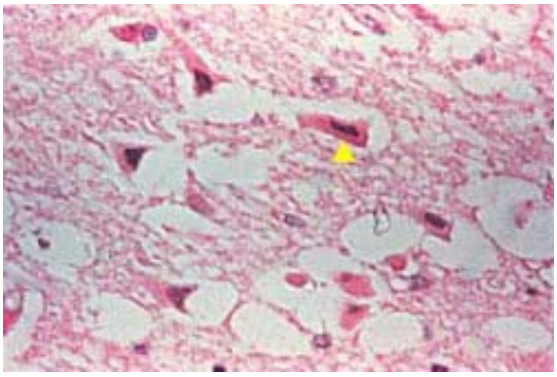

40. Cerebral cortex: "red neurons"

Note the spaces in the cerebral cortex tissue representing cerebral edema. The neurons are the cells with the eosinophilic staining cytoplasm and pyknotic nuclei (see arrow). The pathologic process causing the changes in the neurons is called **apoptosis**. Recall that apoptosis refers to activation of programmed cell death with individual cell necrosis. The cytoplasm of apoptotic cells becomes intensely eosinophilic and the nucleus condensed. Neurons, which are permanent types of cells that can no longer divide, are extremely sensitive to injury in tissue hypoxia. When they die, they undergo apoptosis and produce these "red neurons". **(Ci036)**

Previous | Next

Return to Top | Return to Image Index

Pathology I Images

Cell Injury

It is against copyright laws to make *electronic or printed* copies of these slides!!

41. Kidney: hydronephrosis with compression atrophy
Note the dilated renal pelvis and calyceal system and the thinning of the renal cortex related to the increased pressure. The **increased pressure** imposed on the renal cortex causes it to undergo atrophy (compression atrophy). Hydronephrosis always implies obstruction to urine flow, which may be secondary to prostate hyperplasia, a renal stone (most common), pregnancy, or cancer at the ureterovesical junction.
(Ci037)

42. Kidneys, renal arteries, aorta: renal atrophy owing to atherosclerosis of the proximal portion of the renal artery
The small kidney on your left (see arrow) has undergone atrophy owing to an atherosclerotic plaque partially blocking the opening of the renal artery. Note that the renal artery in the normal kidney is patent. Recall that reducing blood flow to the kidney leads to stimulation of the renin-angiotensin-aldosterone system. The juxtaglomerular apparatus located on the afferent arteriole is stimulated to release the enzyme (not hormone) renin. Renin cleaves angiotensinogen into AT-I. AT-I is converted into AT-II in the lungs by the enzyme, angiotensin converting enzyme (ACE). ATII is a potent vasoconstrictor and also stimulates the 18-hydroxylase enzyme in the zona glomerulosa to convert corticosterone into aldosterone. Aldosterone reabsorbs sodium in the distal and collecting tubules, hence increasing plasma volume. Hypertension, is the end-result of peripheral vasoconstriction of the arterioles by ATII and increased plasma volume by aldosterone. Hypertension secondary to renal artery atherosclerosis is called **renovascular hypertension**. As expected, the renal vein renin levels in the small kidney are increased. However, renal vein renin levels in the normal kidney should be suppressed, since the increased levels of ATII and aldosterone inhibit renin release from the normal kidney. **(Ci038)**

43. Muscle: atrophy

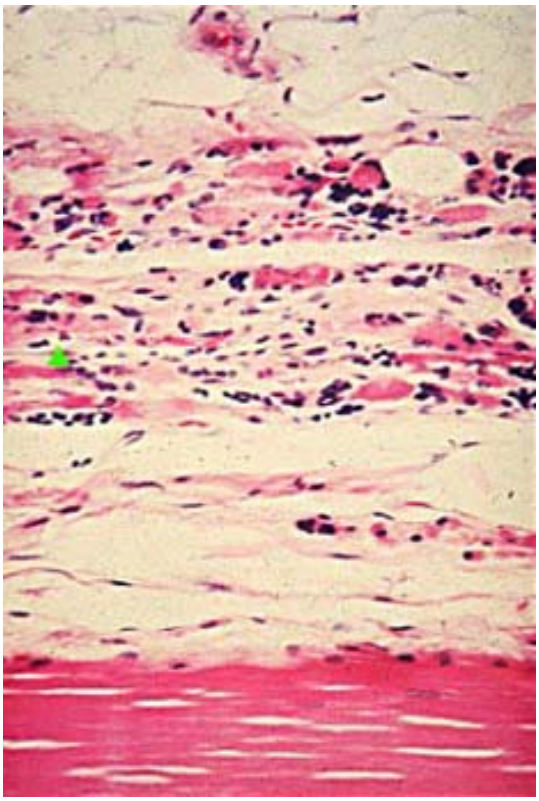

Note the markedly atrophic muscle fibers with eosinophilic cytoplasm and pyknotic nuclei (see arrow). Skeletal muscle atrophy may occur with disuse (e.g., cast on the leg), primary muscle disease (e.g., Duchenne's muscular dystrophy), or loss of nerve stimulation (e.g., amyotrophic lateral sclerosis, compression of a nerve by a ruptured intervertebral disc). **(Ci039)**

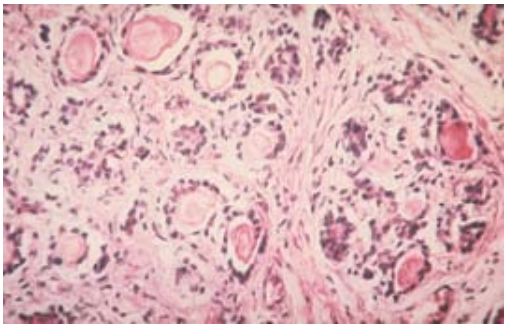

44. Pancreas: cystic fibrosis (atrophy)
Note the eosinophilic material blocking the ducts and the increase in connective tissue surrounding the ducts. Thick secretions in CF block the lumens and the pressure is transmitted back into the exocrine glands leading to atrophy via individual cell necrosis (apoptosis). Loss of exocrine secretions leads to malabsorption of fats, carbohydrates, and protein. **(Ci222)**

45. Hearts: normal on the left and concentrically hypertrophied on the right
The heart on the left is normal. The heart on your right has left ventricular hypertrophy (LVH) with concentric hypertrophy of the muscle (see arrow) leading to a diminished left ventricular chamber with very little space for blood. Concentric hypertrophy of cardiac muscle is due to an increased resistance against which the ventricles must contract to expel blood out of the ventricle (increased afterload). Examples include the increased peripheral resistance in the arterioles associated with essential hypertension (most common) and aortic valve stenosis (narrow opening to the valve). **(Ci042)**

46. Muscle: hypertrophy
Note the increased size of the individual muscle fibers and increased size of the nuclei representing hypertrophy (see arrow). Hypertrophy of a muscle increases the force of contraction of the muscle, since there are twice as many contractile fibers in the cytosol than a normal muscle. Recall the hypertrophied cells pass through the S phase but cannot mitose, hence they have twice the DNA (4N). **(Ci046)**

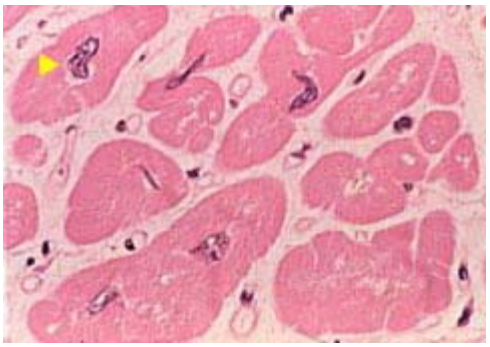

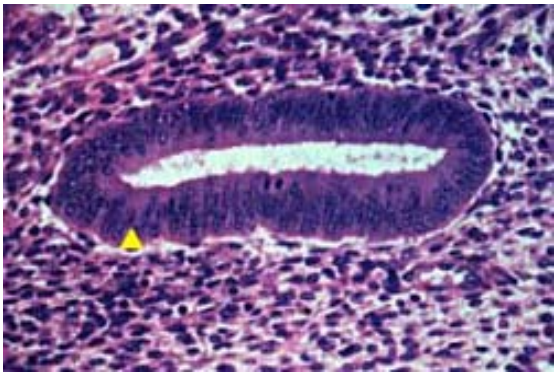

47. Endometrial mucosa: normal endometrial gland in the proliferative phase of the menstrual cycle

Recall that the proliferative phase of the cycle is an estrogen primed event. Estrogen is a growth promoter and causes the endometrial glandular cells to mitose and undergo mitotic divisions (see arrow), which cause the glands to increase in number. This is an example of **physiologic hyperplasia**. **(Ci047)**

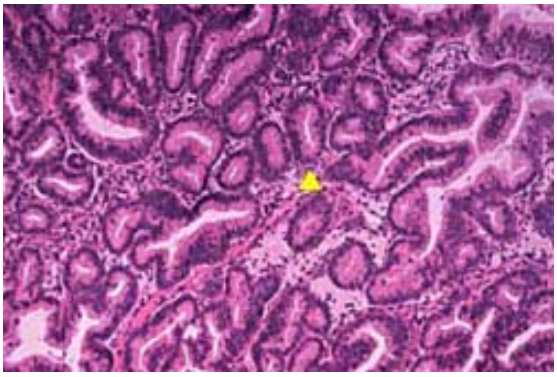

48. Endometrial mucosa: pathologic endometrial hyperplasia due to unopposed estrogen stimulation

When comparing this slide with 047, it is apparent that far more glands are present and they are crowded together. This occurs when a woman has too much estrogen and not enough progesterone, the latter a hormone that causes endometrial glands to undergo atrophy. Examples of unopposed estrogen include a postmenopausal woman who is taking estrogen without progesterone to prevent osteoporosis or an obese woman, who has increased aromatization of androgens into estrogens in the adipose. If endometrial gland hyperplasia persists, endometrial dysplasia, and eventually endometrial carcinoma may occur. **(Ci048)**

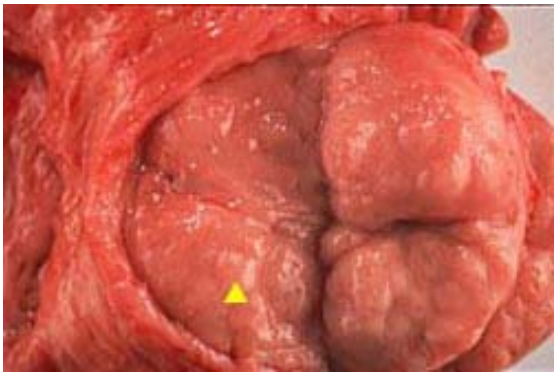

49. Prostate gland: prostatic hyperplasia

The prostate gland has an outer rim (peripheral zone), central zone, and transitional zone, the latter surrounding the prostatic urethra. The gland is under the control of dihydrotestosterone (DHT). Recall that DHT is normally responsible for development of the prostate in the fetus, hence an increase in DHT leads to benign prostatic hyperplasia (BPH). BPH primarily occurs in the transitional zone around the urethra. Note how the prostate gland literally bulges (see arrow) when sectioned. Nodular areas are noted throughout the gland and represent areas of hyperplasia. The surrounding hyperplastic tissue compresses the prostatic urethra in the center of the gland. Symptoms of BPH relate to urethral obstruction. Symptoms include delayed initiation of the urinary stream, narrow urinary stream, increased frequency of urination (patient often wakes up at night to urinate), dribbling at the end of urination, and the possibility of complete obstruction to urine flow. Complete obstruction of

urinary flow causes a back-up of urine into the bladder. This backup of urine dilates the bladder and causes hypertrophy of the smooth muscles in the bladder wall, since they are contracting against increased resistance. Furthermore, the urine backs up into the ureters (dilated) and renal pelvises causing dilatation. This is called **hydronephrosis**.
(Ci051)

50. Prostate and bladder: prostatic hyperplasia with subsequent hypertrophy of the muscle in the bladder wall
Normally, the prostate gland has an outer rim (peripheral zone), central zone, and transitional zone, the latter surrounding the prostatic urethra. The gland is under the control of dihydrotestosterone (DHT, recall that DHT is normally responsible for development of the prostate in the fetus), hence an increase in DHT leads to benign prostatic hyperplasia (BPH). BPH primarily occurs in the transitional zone around the urethra. Note how the cut surface of the prostate gland bulges (see arrow). Nodular areas are noted throughout the gland and represent areas of hyperplasia. The surrounding hyperplastic tissue compresses the prostatic urethra in the center of the gland. Symptoms of BPH relate to urethral obstruction. Symptoms include delayed initiation of the urinary stream, narrow urinary stream, increased frequency of urination (patient often wakes up at night to urinate), dribbling at the end of urination, and the possibility of complete obstruction to urine flow. Complete obstruction of urinary flow causes a back up of urine into the bladder. This backup of urine dilates the bladder and causes hypertrophy of the smooth muscles in the bladder wall, since they are contracting against increased resistance. Furthermore, the urine backs up into the ureters (dilated) and renal pelvises causing dilatation. This is called hydronephrosis.
(Ci052)

Previous | **Next**

Return to Top | **Return to Image Index**

Pathology I Images

Cell Injury

It is against copyright laws to make *electronic or printed* copies of these slides!!

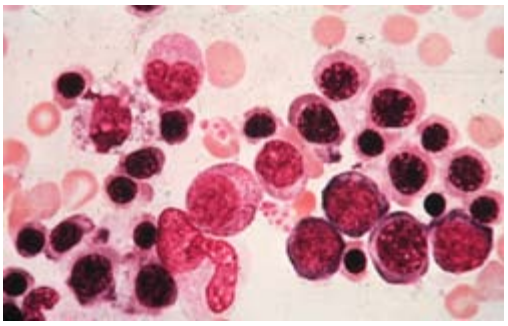

51. Bone marrow: RBC hyperplasia
Normally, there should be a 3:1 ratio of leukocytes to RBCs. However, most of the nucleated cells in this smear are erythroid precursors, hence RBC hyperplasia is present. The stimulus, in most cases, is tissue hypoxia with release of **erythropoietin** from the endothelial cells of the peritubular capillaries in the kidneys. If this smear was from a patient returning from a three-week trip in the Andes mountains, it would be an example of **physiologic hyperplasia**. However, if it was a smear from a smoker with obstructive lung disease, it would be **pathologic hyperplasia. (Ci225)**

52. Skin: psoriasis (pathologic hyperplasia)
Note the raised, erythematous skin lesion covered by silvery scales. This is the classic appearance and location for **psoriasis**. It is due to an unregulated hyperplasia of squamous cell proliferation in the epidermis. **(Ci226)**

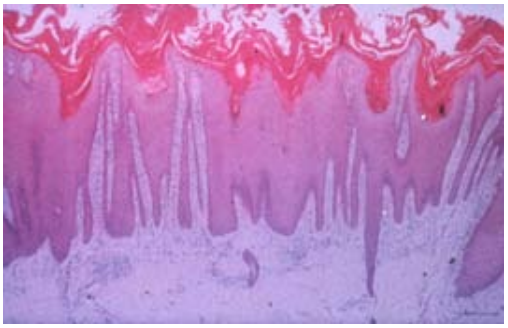

53. Skin: histologic section of psoriasis (pathologic hyperplasia)
Note the increase in stratum corneum surfacing the epidermis. This corresponds to the silvery scales in the previous slide. Also note the increased overall thickness of the epidermis owing to hyperplasia. Recall that the cells in the basal cell layer are stem cells (labile cells). **(Ci227)**

54. Uterus: gravid uterus
Note the marked enlargement of the gravid uterus. This is secondary to an equal amount of both hyperplasia and hypertrophy of smooth muscle cells under the stimulation of estrogen. Recall that smooth muscle cells are stable cells, hence they may undergo both hypertrophy and hyperplasia. Striated muscle and cardiac muscle are permanent cells and are only capable of undergoing hypertrophy. **(Ci053)**

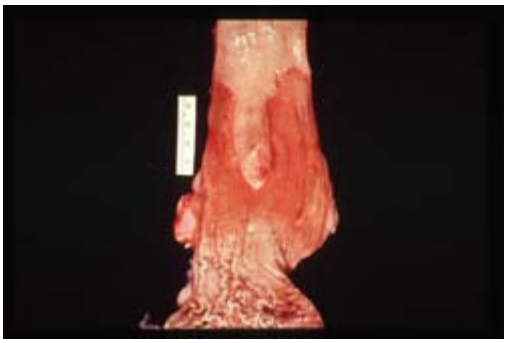

55. Distal esophagus and proximal stomach: gastroesophageal reflux disease (GERD) with ulceration
Subjacent to the ruler, note the extreme ulceration of the mucosal surface of the distal esophagus (reddened area) leaving only a midline tongue of residual esophageal mucosa. The ulceration is due to an incompetent lower esophageal sphincter and reflux of acid into the distal esophagus. Note the proximal stomach rugae at the bottom of the slide. **(Ci228)**

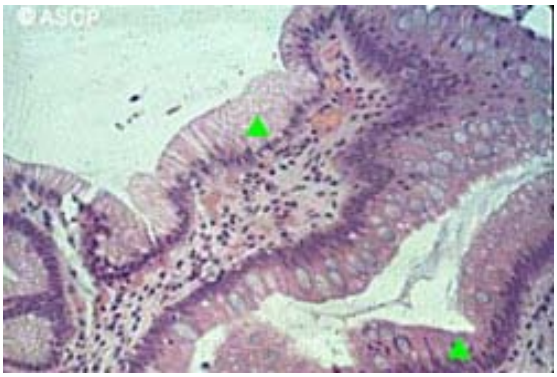

56. Distal esophagus: glandular metaplasia secondary to acid reflux (Barrettï¿½s esophagus)
The distal esophagus should be lined by squamous epithelium. However, due to acid reflux from the stomach into the distal esophagus (gastroesophageal reflux disease - GERD), the epithelium has undergone glandular metaplasia (called Barrett's esophagus) with mucin production as a reaction to acid injury. In GERD, the lower esophageal sphincter is relaxed which allows for acid reflux into the distal esophagus. The arrows point to glandular tissue synthesizing mucin (top arrow) and glandular tissue that has differentiated into goblet cells (bottom arrow). If left untreated with antacids (e.g., Mylanta) and drugs that prevent acid production (e.g., H_2 blockers of parietal cell, proton blockers), glandular metaplasia may progress into glandular dysplasia and adenocarcinoma. Distal esophageal adenocarcinoma due to a **Barrett's esophagus** has now replaced squamous carcinoma of the esophagus as the most common primary esophageal cancer. **(Ci054)**

57. Distal esophagus: special stain enhancing the presence of glandular metaplasia secondary to acid reflux (Barrettï¿½s esophagus)
Note the red staining mucous and blue-staining mucin in the goblet cells. **(Ci055)**

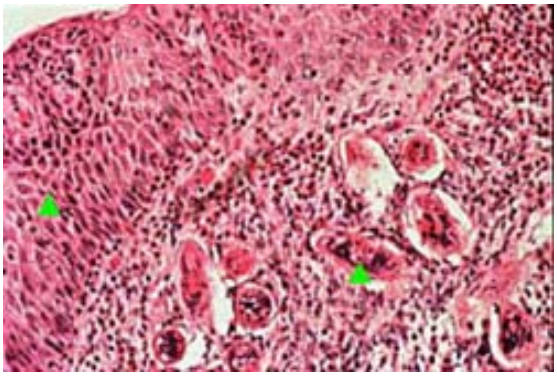

58. Bladder biopsy: squamous metaplasia secondary to *Schistosoma hematobium*
The overlying transitional epithelium has been replaced by squamous epithelium (see arrow). This is an example of squamous metaplasia and is due to the inflammatory reaction in the submucosa hosted against the eggs of *S. hematobium* (see arrow). Squamous metaplasia may progress to dysplasia and squamous cancer. Note the heavy eosinophil inflammatory infiltrate around the eggs. Eosinophils attach to IgE coating the surface of the eggs and degranulate with release of major basic protein (MBP). MBP destroys the eggs. This is an example of a **type II hypersensitivity reaction**. **(Ci057)**

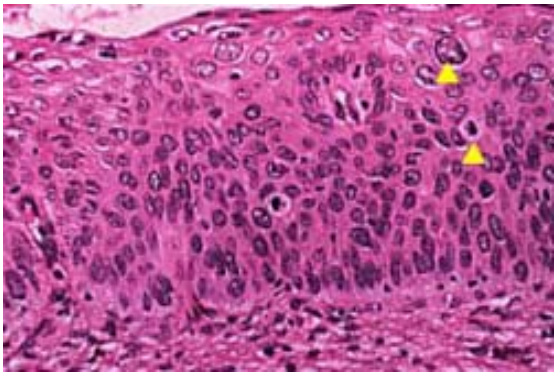

59. Cervical biopsy: severe dysplasia
Note the loss of orientation of the squamous epithelium throughout most of the thickness of the epithelium. Large cells with irregular nuclear contours are noted in the superficial layer of the epithelium (see arrow). Normally, only the basal cell layer or cells immediately above the basal cells contain mitotically active stem cells (labile tissue) that are responsible for cell division. As the cells mature, they progress to the surface of the epithelium and cease to undergo mitosis. Here mitoses are seen in higher layers. This atypical hyperplastic process is called dysplasia, which, in this case, could progress into squamous cancer. Recall that cervical squamous cancer is associated with human papilloma virus infections of the squamous cells. **(Ci056)**

Previous | **Next**

Return to Top | **Return to Image Index**

Pathology I Images

Fluids and Hemodynamics

It is against copyright laws to make *electronic or printed* copies of these slides!!

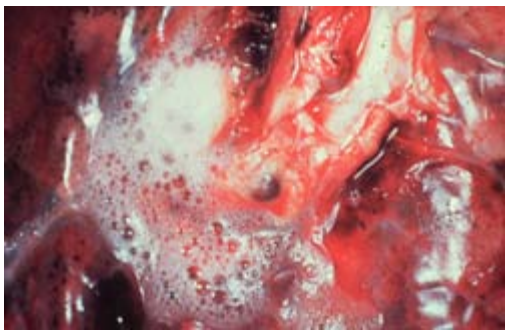

1. Lung: Pulmonary edema secondary to left heart failure (transudate)
Note the white, bubbly fluid exuding from the surface of the lungs. In left heart failure, the blood builds up behind the failed heart and leads to an **increase in left ventricular end-diastolic volume/pressure**. The pressure is further transmitted back into the left atrium and pulmonary vein. When the hydrostatic pressure in the pulmonary capillaries overrides the oncotic pressure, a **transudate** leaks into the alveoli causing **pulmonary edema**. **(flh200)**

2. Face: Swelling due to an anaphylactic reaction to a bee sting (exudate)
The patient was stung by a bee on the arm and within minutes developed swelling of the arm and left side of her face. This is an example of a **type I hypersensitivity anaphylactic reaction** with release of histamine from mast cells leading to increased vessel permeability and swelling of tissue (exudate). She should be treated with **aqueous epinephrine 1:1000 injected subcutaneously** to thwart the reaction. **(flh201)**

3. Patient with cirrhosis: Ascites and dependent pitting edema of the legs (transudate)
Note the abdominal swelling on the left due to ascites. Ascites is due to a combination of an **increased portal vein hydrostatic pressure** (cannot empty blood easily into the liver sinusoids) and **decreased oncotic pressure**, due to **decreased synthesis of albumin**. In both alterations, a protein and cell poor transudate accumulates in the peritoneal cavity. The **dependent pitting edema** indicates an increase in TBNa and is due to the **decreased oncotic pressure (transudate)**. If this was a patient with right heart failure, the dependent pitting edema would be due to an increase in

hydrostatic pressure (transudate). **(flh202)**

4. Patient's arm: Lymphedema associated with radiation status post modified radical mastectomy of the left breast
Note the diffuse swelling of the entire left upper extremity. It is due to blockage of lymphatics related to axillary lymph node dissection followed by radiation. Lymphatic fluid leaks into the interstitial space causing **lymphedema**. It is typically a **non-pitting type of edema**. Long-standing lymphedema may lead to a **lymphangiosarcoma**. **(flh203)**

5. Patient with diabetic ketoacidosis: Volume depletion with decreased TBNa
Note the **dry tongue** in this patient. The patient's **skin turgor was also poor** (tenting of the skin when pinched) and he was **hypotensive**. These are all physical findings of a **decreased TBNa**, in this case due to a **mixed hypotonic loss of more water than salt in his urine from osmotic diuresis secondary to glucosuria**. Most patients in DKA have a deficit of approximately 6 liters of hypotonic fluid when they present. He should **first be treated with IV normal saline to bring his blood pressure back to normal** and then an IV should be started using 0.45% normal saline (hypotonic salt solution matching what he is losing in the urine) within which is regular insulin and potassium. Any patient could look like this patient if salt is lost: e.g., isotonic loss - lose equal amounts of TBNa and TBW, hypertonic loss - lose more TBNa than TBW, or hypotonic loss - lose more TBW than TBNa. **(flh204)**

6. Patient: Dependent pitting edema of the lower leg
Pitting edema indicates and increased TBNa. This patient has right heart failure as the cause, however, it could also have been a patient with cirrhosis (gain more TBW than TBNa), a patient receiving excess amounts of isotonic (normal) saline (equal gain in TBNa and TBW), or a patient with a hypertonic gain of salt (e.g., excess sodium bicarbonate, greater gain in TBNa than TBW). The patient should have salt and water restriction and be placed on a loop diuretic. **(flh205)**

7. Kidney: Ischemic acute tubular necrosis
Note the renal tubules to the right of the glomerulus which demonstrate varying stages of coagulation necrosis (vague

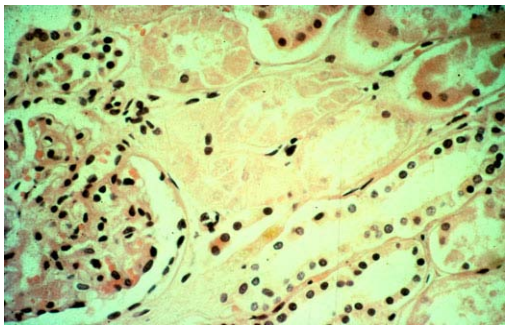

outlines of tubules). Recall that ischemic ATN is a common complication of shock and that the **renal medulla** is most susceptible to tissue hypoxia. The tubular cells will slough off and block the lumen. **Renal tubular casts** will form and be present in the urine sediment. **(flh206)**

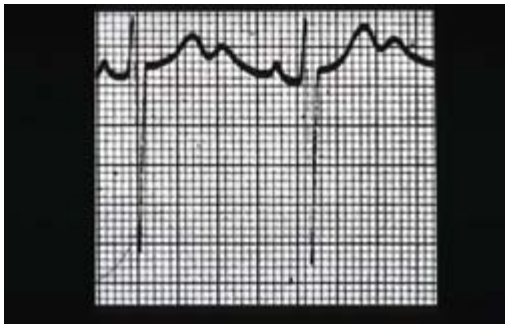

8. EKG with U waves in a patient with hypokalemia
Note the **positive wave after the T wave**. This is called a U wave and is associated with hypokalemia. **Diuretics are the MCC of hypokalemia. (flh207)**

9. EKG with peaked T waves in a patient with hyperkalemia
Note the **peaked T waves** after the QRS. These are associated with **hyperkalemia**. **Renal failure is the MCC of hyperkalemia**. **(flh208)**

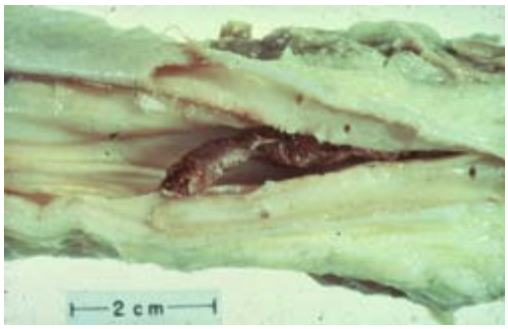

10. Deep vein of calf: Venous thrombosis
Note the deep purple colored thrombus in the vessel lumen. Recall that it is essentially a blood clot in the lumen containing coagulation factors, entrapped RBCs, and platelets. **Warfarin and heparin** can prevent these clots, since they inhibit the formation of fibrin clots generated by activation of the coagulation system. **Stasis of blood is the MCC of venous clots in the legs**. **Embolism** of a venous clot most commonly **originates from clots in the femoral vein** rather than the deep veins of the lower leg. **(flh209)**

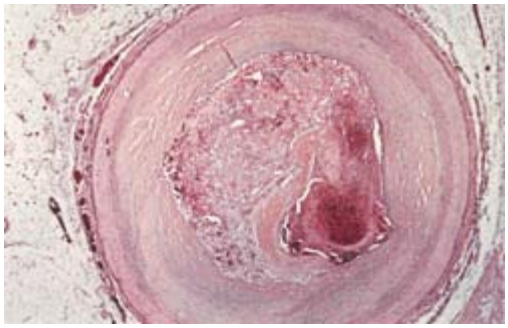

11. Coronary artery: Platelet thrombus overlying an atherosclerotic plaque
Note the red thrombus blocking the lumen of the coronary artery (5 o'clock). It is composed of aggregated platelet held together by fibrin strands. Aspirin prevents the formation of platelet thrombi by inhibiting platelet aggregation by thromboxane A2 via irreversible acetylation of platelet cyclooxygenase. **(flh210)**

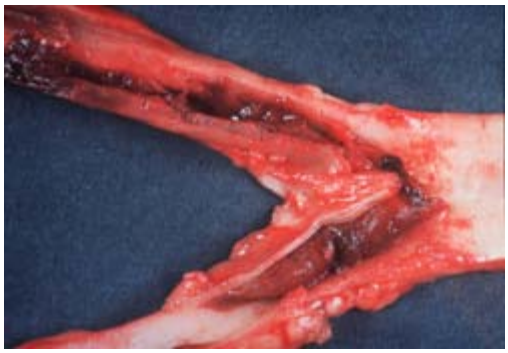

12. Bifurcation of the aorta: Arterial embolus
Note the pale red embolus draped over the bifurcation of the aorta. The **majority of arterial emboli originate in the left heart** (e.g., mural thrombus). **(flh211)**

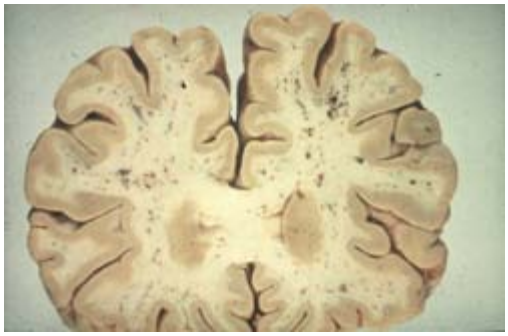

13. Brain: Fat embolism
Note the pinpoint areas of hemorrhage throughout the brain. The patient sustained multiple fractures of the pelvis and femoral bones from a car accident. Microglobules of marrow fat and fat in the surrounding tissue enter the injured vessels and embolize throughout the body. Symptoms of dyspnea usually develop with 2-3 days owing to plugged pulmonary capillaries. In the cerebral vessels, the microglobules of fat block the capillary lumens causing rupture of the vessels. **(flh212)**

Previous | Next
Return to Top | Return to Image Index

Pathology I Images

Inflammation

It is against copyright laws to make *electronic or printed* copies of these slides!!

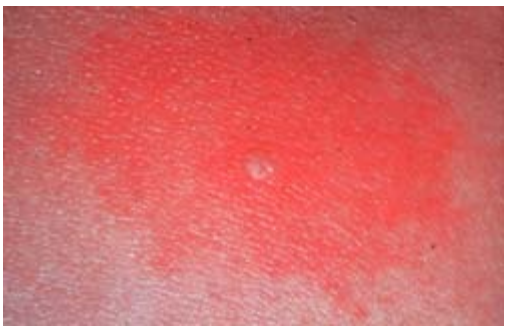

1. Skin: Bee sting with acute inflammation
Note the central raised area corresponding to the **tumor** of acute inflammation. It is due to histamine release by tissue mast cells. Histamine increases vessel permeability leading to an accumulation of protein rich fluid (exudate) in the interstitial tissue. The redness corresponds to the **rubor** of acute inflammation and is due to histamine-dependent arteriolar vasodilatation. The **calor** (heat) of acute inflammation is also due to histamine-dependent arteriolar vasodilatation. Pain (**dolor**) in acute inflammation is due to bradykinin and PGE2. **A bee sting is an example of a type I hypersensitivity reaction. (inf200)**

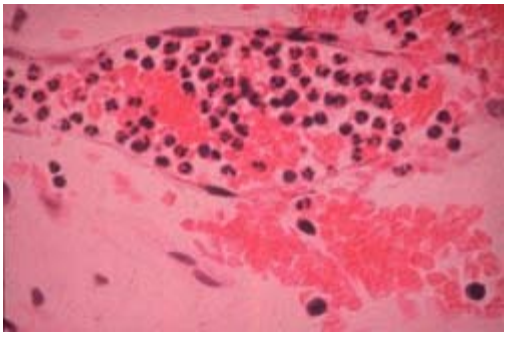

2. Acute inflammation-stasis
This slide shows a small venule filled with neutrophils and red blood cells. There are also red blood cells outside of the blood vessel which represents **diapedesis**. Fluid (edema) has also leaked out of the blood vessel which is the cause of "stasis" of the red blood cells and causes the neutrophils to begin to slow their passage through the blood stream. This process of vasodilatation and increased vascular permeability, due to histamine, facilitates the adhesion of the neutrophils to endothelial cells. **(inf003)**

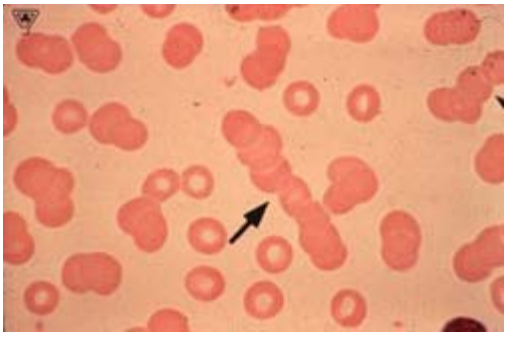

3. Red blood cells-rouleau
This is a peripheral blood smear demonstrating stacking of the red blood cells, a process called **"rouleau"** formation. This process is secondary to stasis of the blood flow and increased concentrations of plasma proteins which coat the red cells and cause them to stick together. Rouleau causes an increase in the erythrocyte sedimentation rate. **(inf004)**

4. Red blood cells-margination and pavementing
This blood vessel against represents stasis of blood flow with accumulation of red blood cells. Notice that some of the neutrophils are lined up

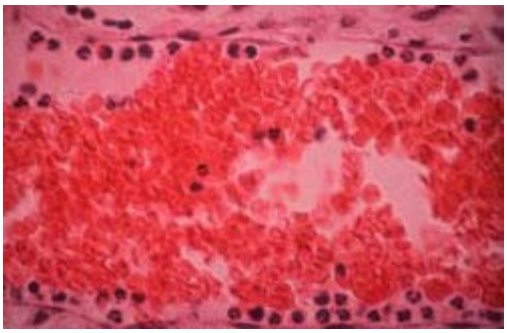

along the endothelial surface of the vessel. This is called "**pavementing**" and represents the **adhesion** of the neutrophils to the endothelial cells which is necessary prior to **emigration** of the neutrophils out of the vessel. **(inf005)**

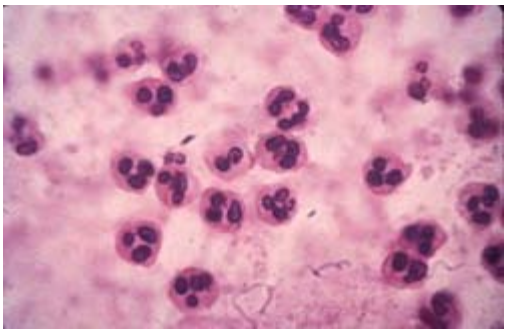

5. Neutrophils in acute inflammation
This is an area in the tissue where acute inflammatory cells are accumulating. Chemotactic substances (e.g. C5a, C3a, LTB4) draw these cells into an area of damage so they can undergo the process of phagocytosis. **(inf007)**

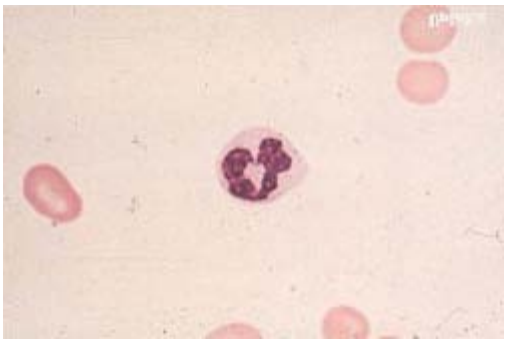

6. Peripheral blood smear-neutrophil
This slide shows a segmented neutrophil (polymorphonuclear leukocyte). Normal cells should have 3-5 lobes in the nucleus. Neutrophils are the primary cell of acute inflammation. **(inf002)**

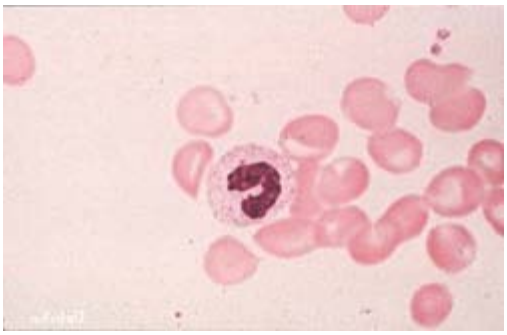

7. Band neutrophil
This peripheral blood smear shows a band neutrophil which is the precursor cell to the segmented neutrophil. If the stimulus for storage pool neutrophil release continues beyond a few days, the post-mitotic pool will become depleted (the production of acute phase reactants causes release of the post-mitotic pool of neutrophils). The mitotic pool will then increase production in an attempt to meet the demand for neutrophils. Greater than 10% band neutrophils or any neutrophil less mature than a band (metamyelocyte, myelocyte) in the peripheral blood count is a "shift to the left". **(inf013)**

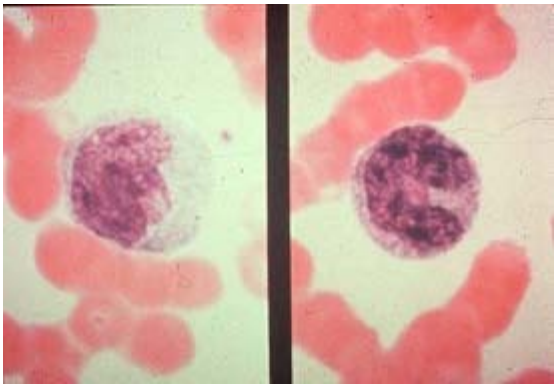

8. Monocytes
This slide shows two examples of monocytes in peripheral blood. Once monocytes become macrophages, they lose the 02 dependent MPO system. **(inf051)**

9. Electron microscopy of macrophage

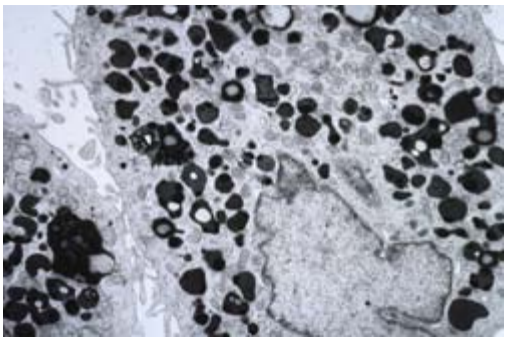

The nucleus is at the bottom of the slide. The dark granules represent lysosomes. Recall that macrophages used to be circulating monocytes. Monocytes and macrophages are the primary cells of chronic inflammation. **(inf201)**

10. Small lymphocyte
This slide shows a small lymphocyte with approximately 90% of the cell being nucleus. The chromatin in the nucleus is deeply condensed and lumpy. **(inf054)**

Previous | Next

Return to Top | Return to Image Index

Pathology I Images

Inflammation

It is against copyright laws to make *electronic or printed* copies of these slides!!

11. Electron microscopy of a small lymphocyte
Note the condensed chromatin of the nucleus surrounded by a thin rim of cytoplasm. Recall that the majority of peripheral blood lymphocytes are T cells (60-80%) with a 2:1 ratio of CD4 T helper cells to CD8 suppressor/cytotoxic T cells. The remaining lymphocytes are B cells. **(inf202)**

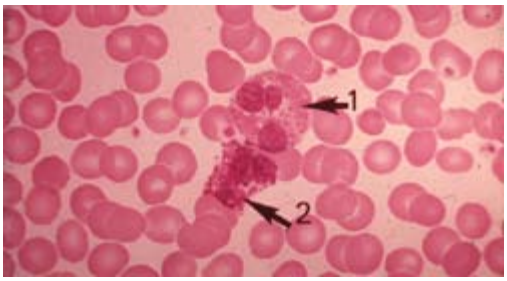

12. Peripheral blood: eosinophil and basophil
Cell number 1 is an eosinophil. Note that the red granules are the same color as the RBCs. Granules do not cover the nucleus. **Eosinophilia** is associated with type I hypersensitivity reactions- e.g., hay fever, allergic rhinitis, bronchial asthma, invasive helminthic infections. **Cell number 2 is a basophil**. Note that the granules are darker than the RBCs and they cover the nucleus. **(inf204)**

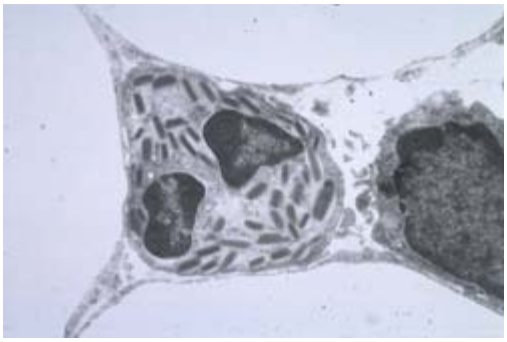

13. Electron microscopy of an eosinophil
Note the **rod-shaped crystals in the granules**. When eosinophils degenerate, the crystals may coalesce to form **Charcot-Leyden crystals**, a characteristic finding in the sputum of asthmatics. **(inf205)**

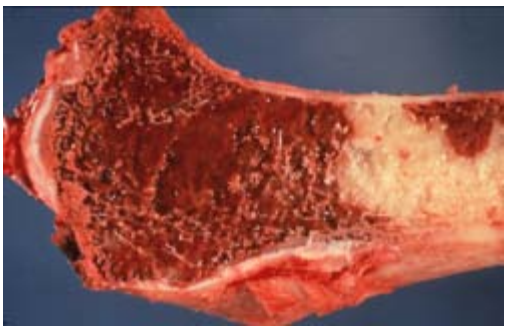

14. Bone: acute osteomyelitis (suppurative inflammation)
Note the yellow area in the metaphysis of the femur. This represents an area of **acute suppurative inflammation** (liquefactive necrosis) due to hematogenous spread of ***Staphylococcus aureus*, the MCC of acute osteomyelitis in children**. Neutrophils will lyse the bone and produce a radiolucent area that is visible on x-ray after one week. **(inf206)**

15. Face: erysipelas due to group A streptococcus (*Streptococcus pyogenes*,

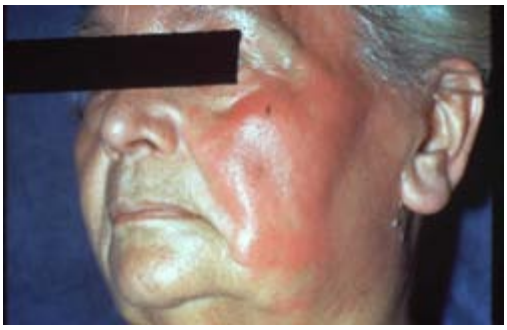

cellulitis)
Note the raised, erythematous area involving most of the left side of the face. **Cellulitis** is commonly seen in streptococcal infections owing to the production of **hyaluronidase**, which breaks down GAGs and allows the infection to spread through subcutaneous tissue. **(inf207)**

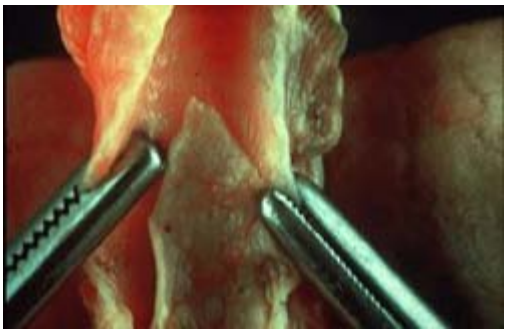

16. Pseudomembranous inflammation
This slide is from a case of diphtheria. Note the gray membrane in the upper airway (oropharynx). This membrane (pseudomembrane) is composed of neutrophils, necrotic tissue, and fibrinous exudate. It is characteristic of diphtheria. The causative organism is *Corynebacterium diphtheriae*, a gram positive rod. The organism produces an exotoxin which damages the myocardium and peripheral nerves. Another type of pseudomembrane formation is pseumembranous colitis which is caused by use of antibiotics such as ampicillin. **(inf028)**

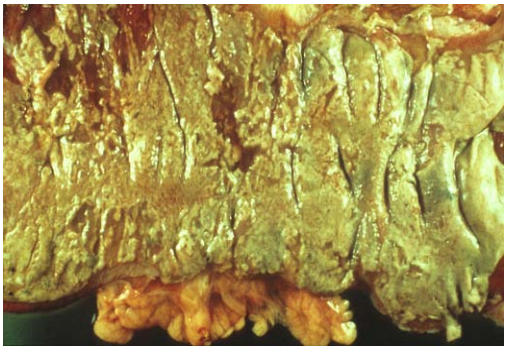

17. Colon: pseudomembranous colitis due to *Clostridium difficile* (pseudomembranous inflammation)
Note the gray-yellow pseudomembrane covering the entire mucosal surface. Damage is due to a **toxin produced by *C. difficile***. Similar to diphtheria, the toxin produces necrosis of the mucosa and submucosa without actual invasion by the bacteria. A **toxin assay of stool** is the best method for diagnosing the disease. **Ampicillin is the MC drug causing pseudomembranous colitis** and does so by destroying colonic bacteria that normally keep *C. difficile* in check. **(gi269)**

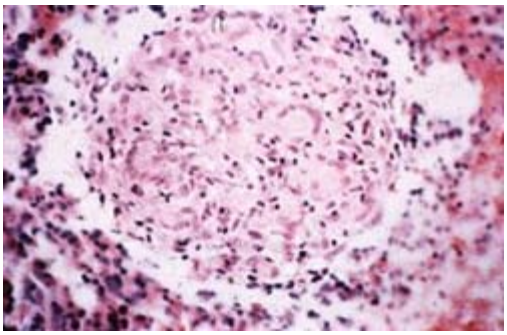

18. Granulomatous inflammation
This is another example of a granuloma. Note the presence of multinucleated giant cells. Also note that lymphocytes predominate in the areas surrounding the granuloma. **(inf061)**

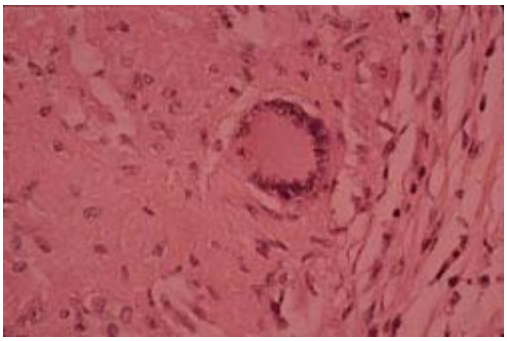

19. Granulomatous inflammation: Langhan's giant cell
This slide shows a giant cell associated with an area of granulomatous inflammation. Note that the nuclei are arranged at the periphery of the cell. This is a characteristic of Langhan's giant cells. These cells are prominent in areas of granulomatous inflammation but are not required for a diagnosis. **(inf063)**

20. Heart: Fibrinous pericarditis

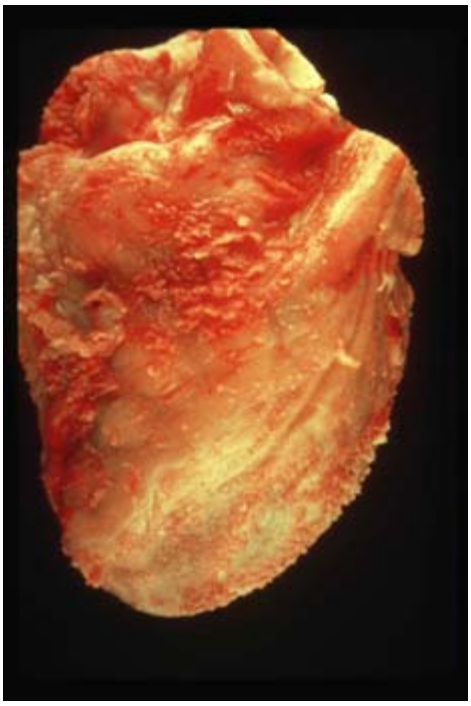

Note the shaggy exudate surfacing the pericardium. In this case, it is a sterile acute inflammatory reaction due to acute rheumatic fever. Increased vessel permeability causes protein (includes fibrinogen) to leak out of the vessels and congeal on the surface. Patients develop an audible **friction rub** due to the parietal pericardium separating away from the visceral pericardium covered with the exudate during different phases of the cardiac cycle. Other causes of fibrinous pericarditis include SLE, a transmural myocardial infarction, and coxsackie virus pericarditis (MCC). **(inf209)**

Previous | **Next**

Return to Top | **Return to Image Index**

Pathology I Images

Syllabus | Lecture Schedule | Images - Pathology I | Images - Pathology II

Neoplasia

1 | 2 | 3 | 4 | 5 | 6 | 7 | 8 | 9 | 10 | 11 | 12 | 13| 14

It is against copyright laws to make *electronic or printed* copies of these slides!!

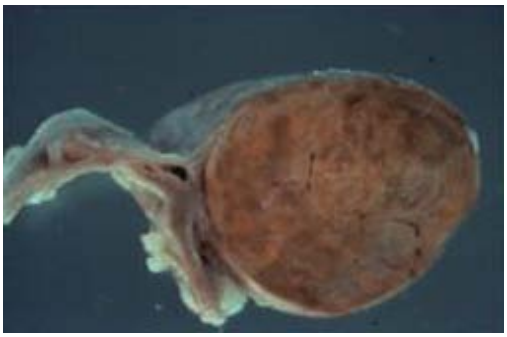

1. Adrenal adenoma
This is an adrenal adenoma which is a benign tumor arising from the adrenal cortex. Notice how well-demarcated it is. There is absence of hemorrhage and necrosis. It also has the color of adrenal cortex. **(Neo001)**

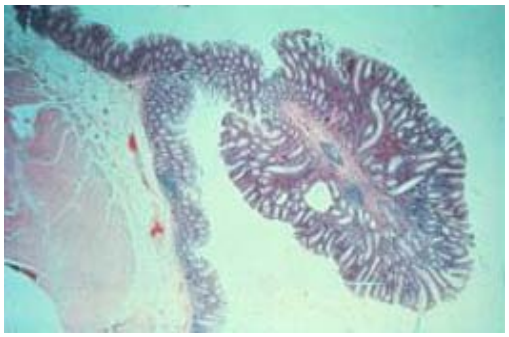

2. Tubular adenoma
This is a microscopic section of a neoplastic polyp arising from the colon mucosa. The polyp is pedunculated and is composed of colonic glands which have lost many of the normal goblet cells. This is called an adenomatous change. **(Neo003)**

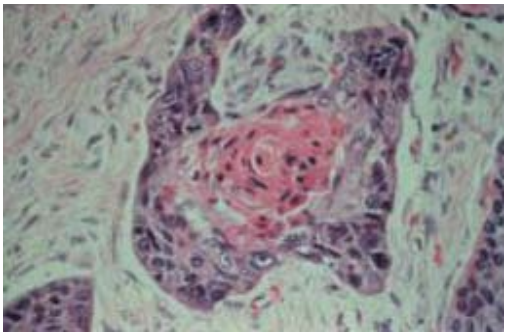

3. Squamous cell carcinoma
This is a cluster of malignant squamous cells. These malignant cells are still able to undergo some degree of differentiation as shown by the pink area of keratinization. **(Neo004)**

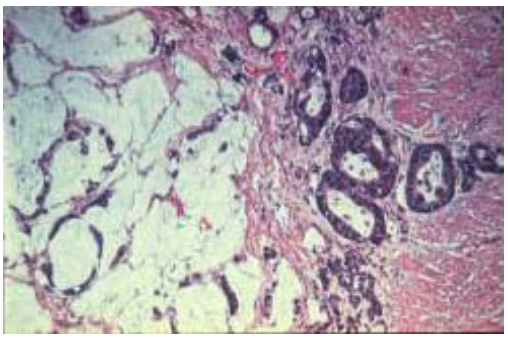

4. Adenocarcinoma
This is a slide showing malignant gland formation. The nests of malignant cells are producing gland lumina. The clear areas on the left represent mucin production by the tumor cells. **(Neo005)**

5. Transitional cell carcinoma of the

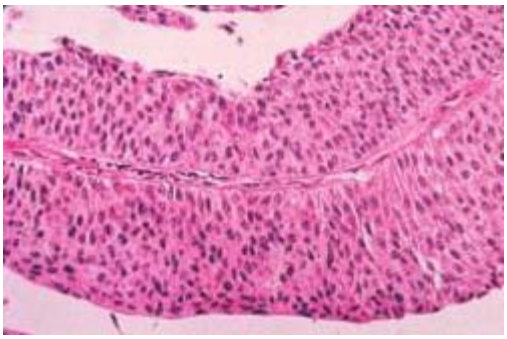

urinary bladder
This slide shows a papillary projection from a bladder cancer. Each side of the papillary process is lined by several layers of transitional cells. This tumor is graded by the number of cell layers (stratification) present. **(Neo006)**

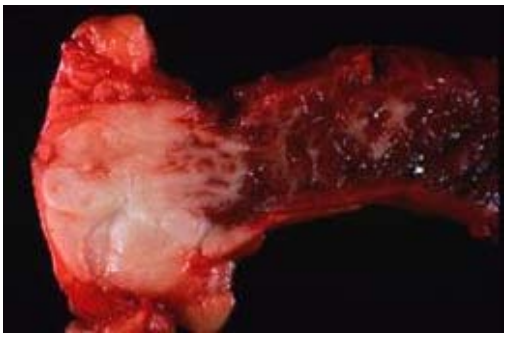

6. Lipoma
The yellow mass with the muscle is a benign tumor arising from mature adipose tissue. The tumor is well-circumscribed. **(Neo007)**

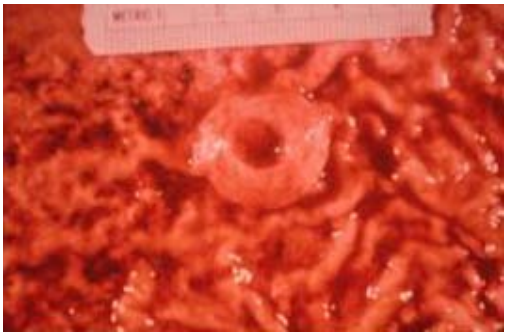

7. Leiomyoma of stomach
This is a gross photograph of a benign tumor of smooth muscle origin in the stomach. These tumors may present with bleeding. **(Neo008)**

neo010.jpg (9415 bytes)

8. Embryonal rhabdomyosarcoma
This slide shows a striated malignant tumor cell (strap cell). This type of rhabdomyosarcoma is the MOST COMMON sarcoma of children. It arises in the vagina in girls and in the urethra of boys. It is desmin positive. **(Neo010)**

9. Cystic teratoma (dermoid cyst)
This is a benign teratoma arising from all three germ cell layers. It is typically composed of ectodermally derived hair and sebaceous secretions. These tumors frequently make tooth structures. The tumors arise in gonads or as midline lesions. In children, they are found in the sacrococcygeal area. **(Neo011)**

10. Mixed tumor of the parotid
These tumors are considered the MOST COMMON type of salivary gland tumor. They arise from the same germ cell layer but there are two distinct types of histologic patterns within the tumor. These tumors

usually have a glandular type of tissue plus a myxoid stroma. **(Neo012)**

Previous | Next

Return to Top | Return to Image Index

Pathology I Images

Syllabus | Lecture Schedule | Images - Pathology I | Images - Pathology II

Neoplasia

1 | 2 | 3 | 4 | 5 | 6 | 7 | 8 | 9 | 10 | 11 | 12 | 13| 14

It is against copyright laws to make *electronic or printed* copies of these slides!!

11. Malignant lymphoma
This slide shows diffuse involvement of the mediastinum by a tan "fish-flesh" mass. This is a classic pattern seen in malignant lymphomas involving this area. The tumor arises from solid lymphoid tissue. **(Neo013)**

12. Hodgkin's disease
This slide shows bilateral cervical lymphadenopathy. This pattern is common in Hodgkin's disease which is a subtype of lymphoma. **(Neo015)**

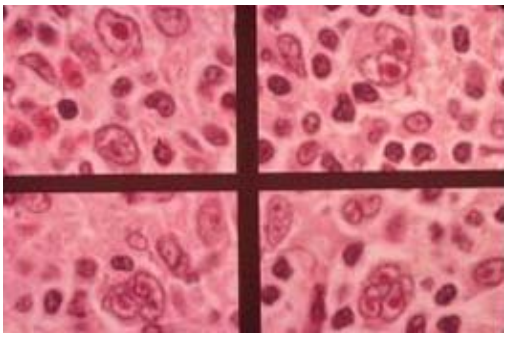

13. Hodgkin's disease - Reed-Sternberg cells
These microscopic sections show large cells with prominent eosinophilic nucleoli called Reed-Sternberg cels. These cells are most commonly found in mixed cellularity Hodgkin's disease and lymphocyte-depleted Hodgkin's disease. Both of these histologic patterns have a less favorable prognosis than lymphocyte-predominant Hodgkin's or nodular sclerosing Hodgkins's which is the most common type. **(Neo016)**

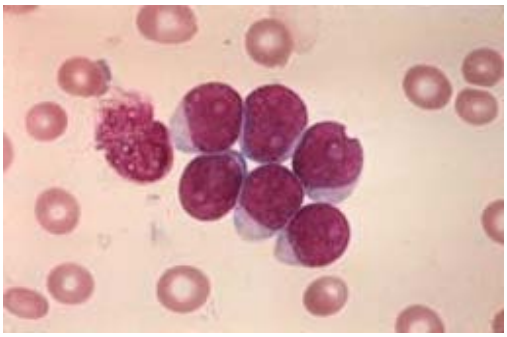

14. Acute lymphocytic leukemia
This is a peripheral blood smear showing a cluster of immature appearing lymphocytes (lymphoblasts). This tumor is the most common leukemia of children with the peak age being 4. The CALLA antigen is a tumor marker which is found on pre-B cells and gives a favorable prognosis. The bone marrow would show > 30% blast forms. **(Neo017)**

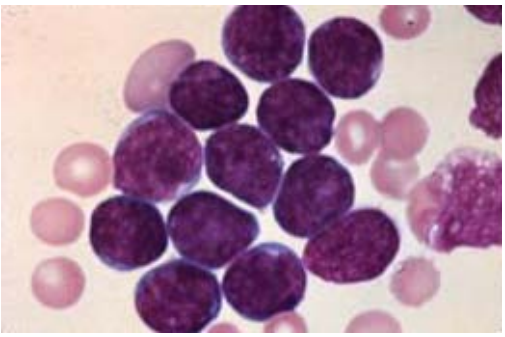

15. Chronic lymphocytic leukemia
This is the most common leukemia in elderly patients. Notice the mature appearing B lymphocytes in the peripheral blood smear. These B cells are long-lived and nonfunctional and infiltrate the bone marrow, blood, lymph nodes, and other tissues. **(Neo018)**

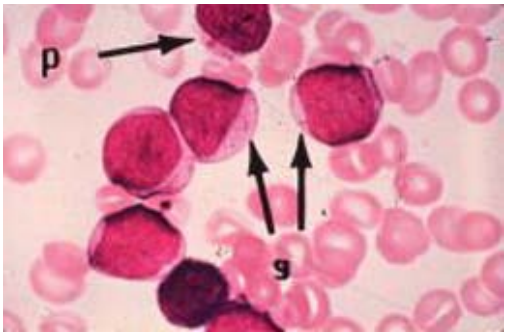

16. Acute myeloblastic leukemia
Note the eosinophilic rod-shaped structures in the cytoplasm of the neoplastic cells. These are AUER rods and are present in most cases of AML especially the promyelocyte class. There are 8 classes of AML, each with unique features. Acute promyelocytic leukemia is associated with a t (15;17) translocation and disseminated intravascular coagulopathy is common. **(Neo019)**

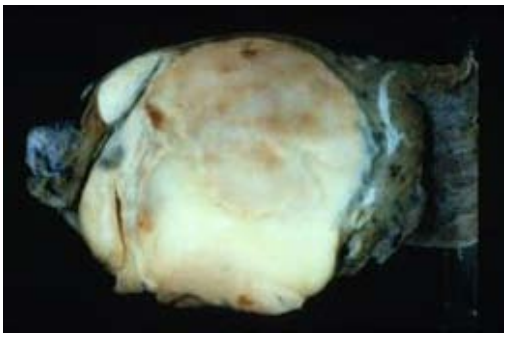

17. Bronchial hamartoma
This is a non-neoplastic lesion composed of tissues normally found in the organ where the hamartoma arises. The tissues in the hamartoma are typically disorganized in their arrangement. **(Neo020)**

18. Peutz-Jeghers
This is a syndrome associated with mucocutaneous pigmentation and hamartomatous polyps of the GI tract. **(Neo021)**

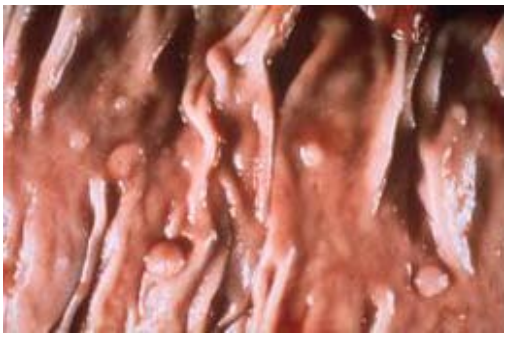

19. Hyperplastic polyps
These are hamartomatous polyps of the GI tract which are the MOST COMMON type of non-neoplastic polyp. Microscopically, they show increased numbers of goblet cells. **(Neo022)**

20. Choristoma (heterotropic pancreas)
This is a section of duodenum showing an aggregate of pancreatic tissue in the wall. The pancreatic tissue is normal in appearance but in an abnormal location. This is a non-neoplastic process. **(Neo023)**

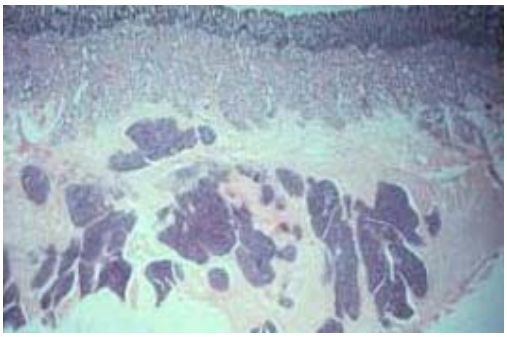

Previous | Next

Return to Top | Return to Image Index

Pathology I Images

Neoplasia

It is against copyright laws to make *electronic or printed* copies of these slides!!

21. Hemangioma
This is a benign neoplasm arising from endothelial cells of blood vessels. **(Neo024)**

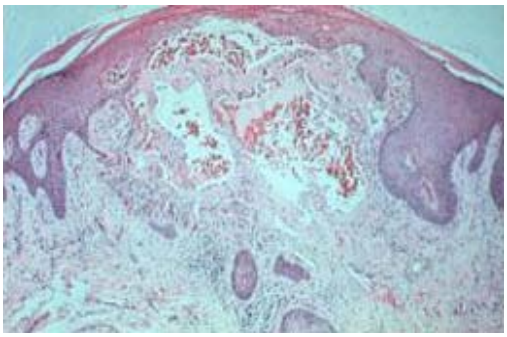

22. Hemangioma
This is the microscopic appearance of a hemangioma showing dilated blood vessels filled with red blood cells and lined by benign endothelial cells. **(Neo025)**

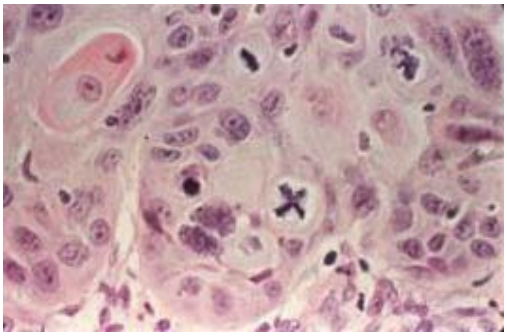

23. Malignant cells
This slide shows several features of malignancy. The cell in the central portion of the slide shows a TETRAPOLAR mitotic figure which is abnormal. Other cells show hyperchromatic nuclei or large and irregular nuclei and nucleoli all of which are features of malignancy. **(Neo026)**

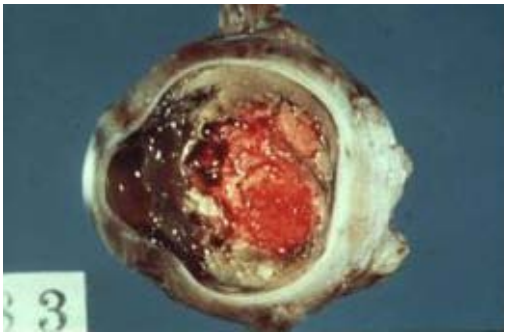

24. Retinoblastoma
This is a retinoblastoma. This malignant tumor is associated with inactivation of the Rb tumor suppressor gene. **(Neo027)**

25. Burkitt's lymphoma
This lymphoma, especially the African type,

is associated with a 8;14 chromosomal translocation. **(Neo028)**

26. Kaposi sarcoma
Multiple vascular lesions are noted. This tumor is associated with HIV and arises from endothelial cells. There is a high correlation with Kaposi sarcoma herpesvirus (KSHV) or human herpesvirus-8 (HHV-8) **(Neo029)**

27. Xeroderma pigmentosum
This autosomal recessive disorder involves a defect in DNA repair enzymes in the skin. The patients are susceptible to skin cancers such as melanomas, basal and squamous cell carcinomas of the skin associated with UVB light damage. **(Neo030)**

28. Squamous cell carcinoma of skin
This neoplasm is associated with UVB light damage and immunosuppression. It is found on sun-exposed areas, particularly the face. **(Neo031)**

29. Clear cell carcinoma of the vagina
Diethylstilbestrol exposure. This is a malignant neoplasm occurring in the vagina of the daughters of DES exposed mothers.

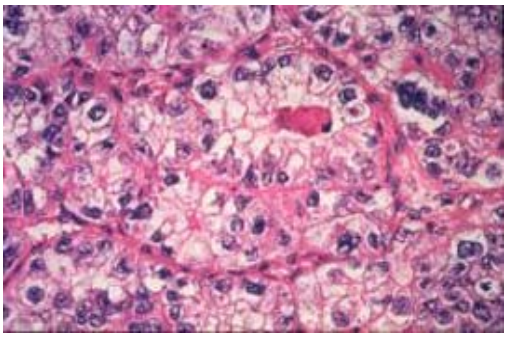

The DES causes persistence of Mullerian tissues in the vagina which gives rise to vaginal adenosis which is the precursor lesion for clear cell adenocarcinoma. This tumor occurs in young females. **(Neo032)**

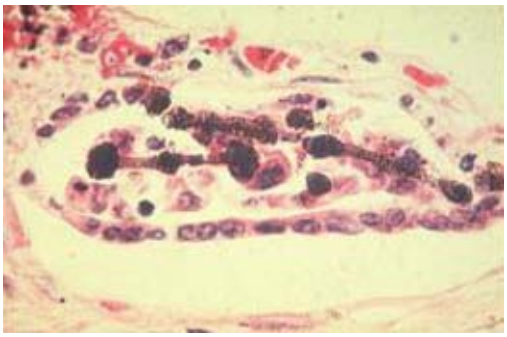

30. Asbestos (ferrunginous bodies) bodies

These dumbbell shaped particles are found in the lungs of patients exposed to asbestos. Pleural fibrous plaques and malignant mesotheliomas are associated with exposure to asbestos. **(Neo034)**

Previous | Next

Return to Top | Return to Image Index

Pathology I Images

Neoplasia

It is against copyright laws to make *electronic or printed* copies of these slides!!

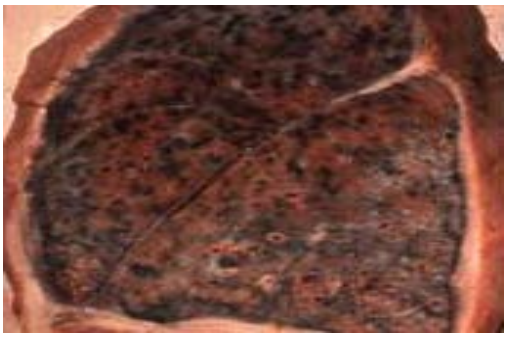

31. Pleural mesothelioma
This neoplasm arises from mesothelial cells of the pleura and peritoneum. It encases the lung-producing compressive atelectasis. Prior asbestos exposure is the major risk factor. **(Neo035)**

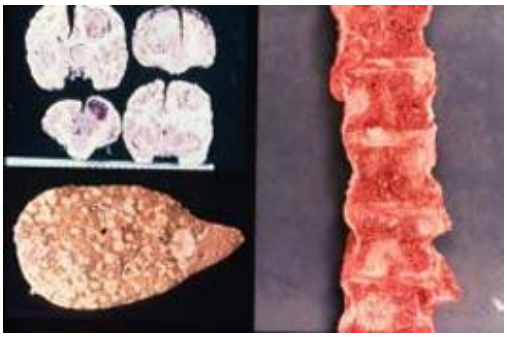

32. Metastasis
Each of the organ systems featured on the slides represent favored sites for metastasis. The bone is a common site for metastasis from prostate, lung, and thyroid cancers. CNS is a common site of metastasis from small cell carcinomas of lung and breast cancers. Liver is a common site of metastasis from lung and colon tumors. **(Neo036)**

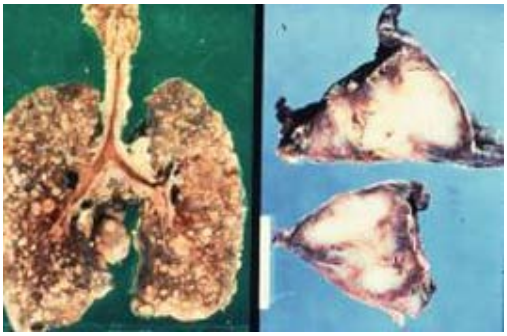

33. Metastasis
The lung is a common site of metastasis from colon and other visceral neoplasms. "Cannon-ball" metastasis is produced by hematogenous spread of choriocarcinoma, osteogenic sarcomas, and renal cell carcinoma. **(Neo037)**

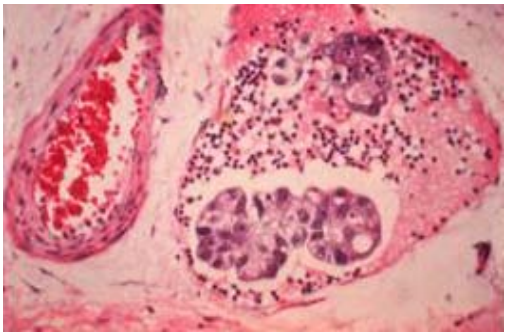

34. Lymphangitic spread
This slide shows a lymphatic vessel containing nests of malignant adenocarcinoma cells. **(Neo038)**

35. Lymph node metastasis
This is an example of a papillary carcinoma

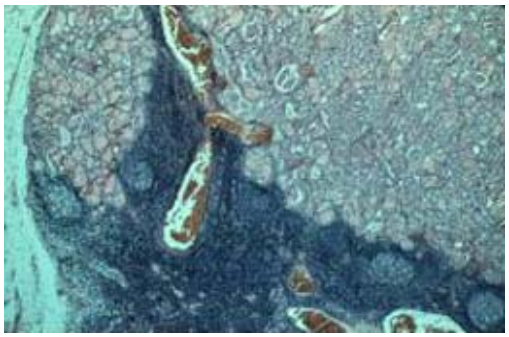

of the thyroid which has metastasized to a lymph node. **(Neo039)**

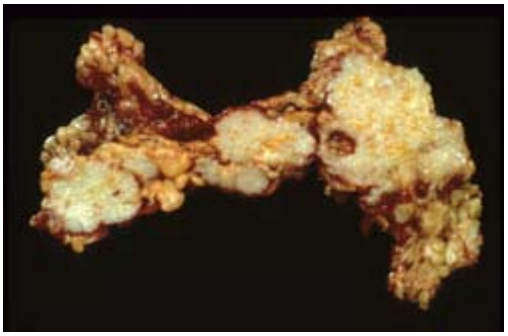

36. Omental seeding
This section of omental fat shows light tan tumor masses which are adherent to the omentum. Tumors associated with this type of seeding include mucinous cystadeno-carcinomas of the ovary, and tumors of the GI tract. **(Neo040)**

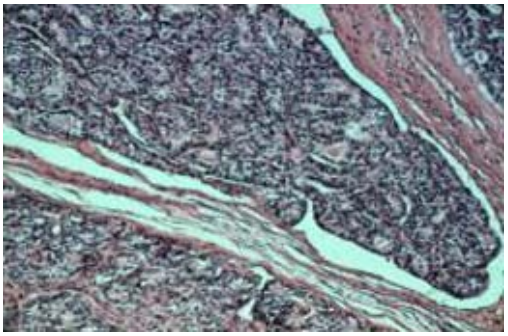

37. Vascular invasion-follicle carcinoma of the thyroid
This tumor has the propensity to invade blood vessels and undergo hematogenous dissemination which is shown on the slide. **(Neo041)**

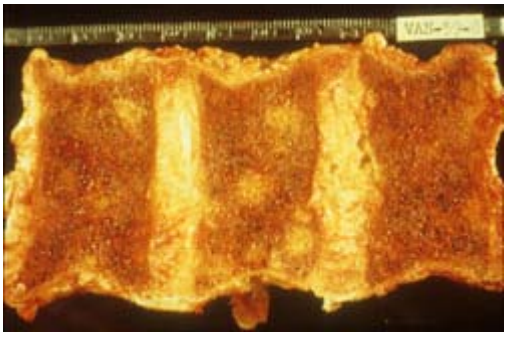

38. Osteoblastic metastasis
Certain neoplasms have a tendency to metastasize to bone and if so, produce stimulation of the osteoblasts with new bone formation. The bone alkaline phosphatase will be elevated in the serum. Tumors associated with osteoblastic metastasis include prostate, thyroid, breast, and carcinoid. **(Neo042)**

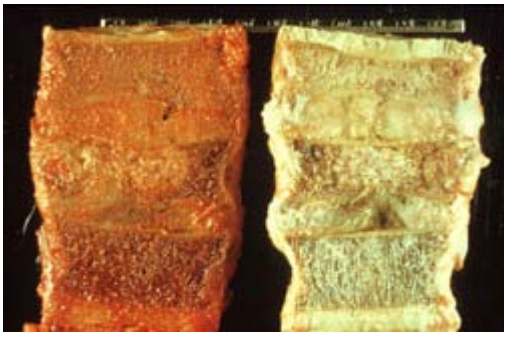

39. Osteolytic metastasis
Tumors which metastasize to bone and cause bone breakdown include breast and lung. Pathologic fractures are a risk. **(Neo043)**

40. Lung radiographics showing cancer
The top radiograph shows a peripheral density in the right lung which represents a primary adenocarcinoma of the lung. The lower radiograph shows "cannon-ball" metastasis. **(Neo044)**

Previous | Next

Return to Top | Return to Image Index

Pathology I Images

Neoplasia

It is against copyright laws to make *electronic or printed* copies of these slides!!

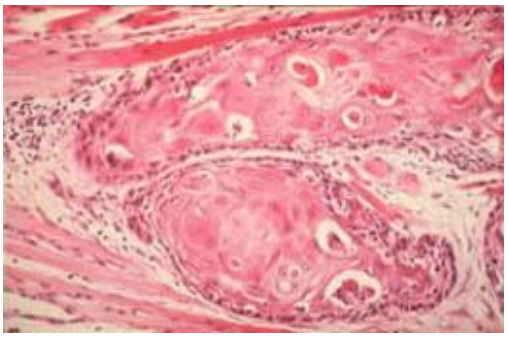

41. Well-differentiated squamous cell carcinoma
This slide shows two nests of well-differentiated squamous cells (low grade) demonstrating features of normal squamous cells. **(Neo045)**

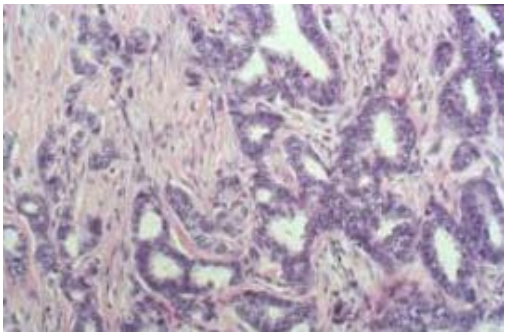

42. Well-differentiated adenocarcinoma
This slide shows a well-differentiated adenocarcinoma with well formed glands and distinct lumens. **(Neo046)**

43. Hypertrophic osteo-arthropathy
This is a paraneoplastic syndrome characterized by clubbing of the fingers, toes and periosteal elevation of the distal parts of the long bones. It is associated with lung cancer. **(Neo048)**

44. Acanthosis nigricans
A paraneoplastic syndrome of hyperpigmentation of the axilla associated with an underlying gastric carcinoma. A phenotypic marker. **(Neo049)**

45. Seborrheic keratosis (Leser Trelat)

A paraneoplastic syndrome associated with sudden appearance of multiple crops of seborrheic keratoses-a pigmented skin lesion with a "stuck-on" appearance. Associated with underlying GI cancer. **(Neo050)**

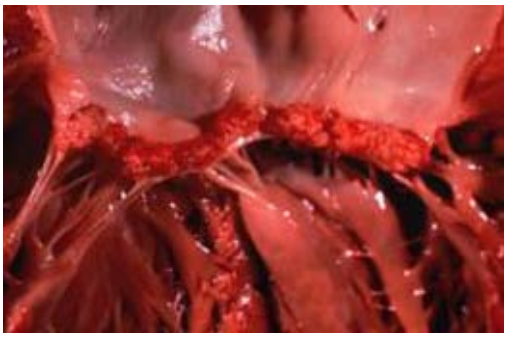

46. Marantic endocarditis
Endocarditis associated with sterile vegetations that are thought to be due to a hypercoagulable state. **(Neo051)**

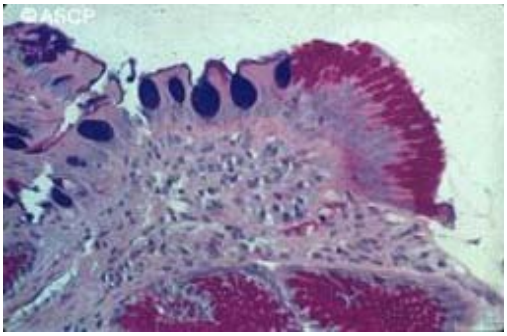

47. Barrett's esophagus-mucin stain
This is a metaplastic change in the esophagus associated with reflux esophagitis. The normal squamous esophageal mucosa is replaced by gastric glandular mucosa. It is a precursor lesion for adenocarcinoma of the esophagus. **(Neo052)**

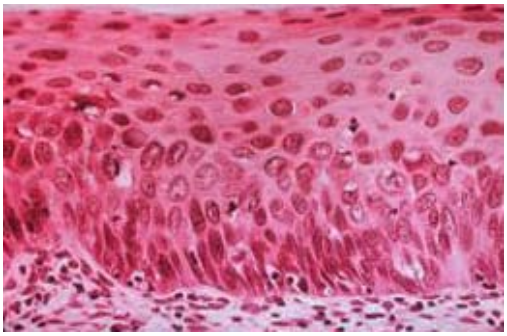

48. CIN I (Cervical Intraepithelial Neoplasia I)
The is mild dysplasia of the cervix. Notice that the basal cell layer now composes the lower 1/3 of the cervical mucosa. **(Neo053)**

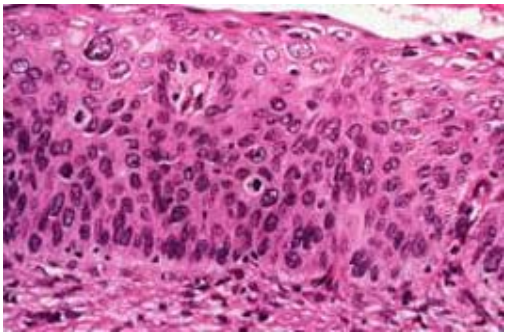

49. CIN III
This is severe dysplasia of the cervix. The basal cells now occcupy 2/3 to 3/4 of the mucosal thickness. These cells show atypical features with pleomorphism and hyperchromatic nuclei. Three mitotic figures are noted. **(Neo054)**

50. Squamous cell carcinoma of the larynx
Note the fungating mass on the lateral border of the larynx with central ulceration. These tumors are associated with smoking and chronic alcohol use. The first symptom is hoarseness. **(Neo056)**

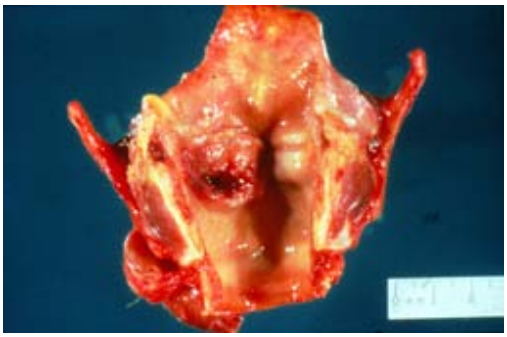

Previous | Next

Return to Top | Return to Image Index

Pathology I Images

Neoplasia

It is against copyright laws to make *electronic or printed* copies of these slides!!

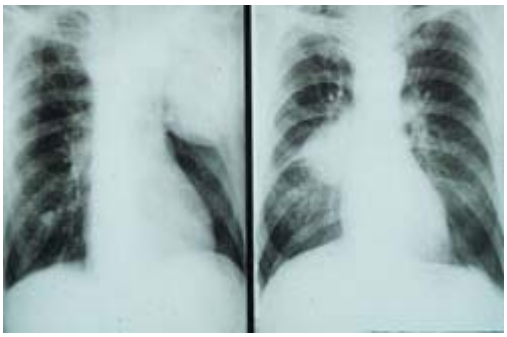

51. Two radiographs with cancers
The x-ray on the left shows a large upper lobe peripheral lesions of the left lung. This is most likely an adenocarcinoma. The x-ray on the right shows a central density in the right lung which is most likely a squamous cell carcinoma. **(Neo057)**

52. Squamous cell carcinoma of the lung
This slide shows an airway that is opened. The mucosa appears rough and there is an infiltrating mass involving the wall of the bronchi before and after the branching. This is most likely a squamous cell carcinoma. **(Neo058)**

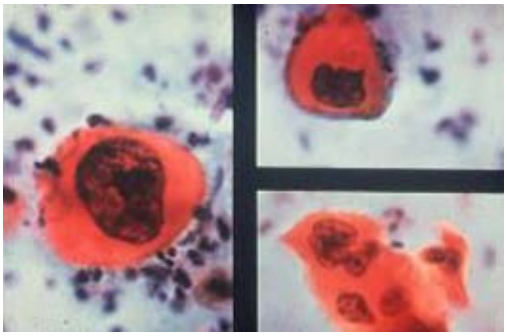

53. Squamous cell cardinoma-lung-cytology
These three photographs of cytologies show malignant squamous cells. Note the "organophilic" cytoplasm which represents keratin and the increased nuclear to cytoplasmic ratio. The cells in one slide are in a nest. The nuclei are hyperchromatic, irregular, and have prominent nucleoli. **(Neo059)**

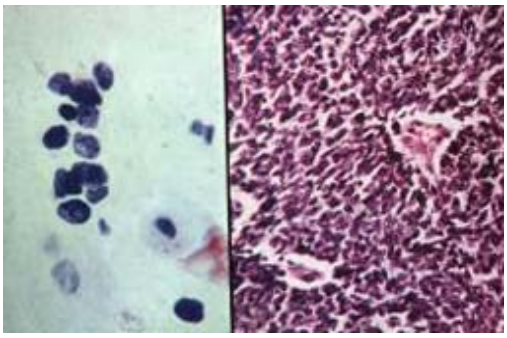

54. Small cell carcinoma of lung
The slide on the left is a sputum cytology showing small dark staining cells. They mold around each other. There is almost no cytoplasm visible. The slide on the right is from the tumor in the lung. Notice the hyperchromatic cells which appear to be swarming around the blood vessels. This tumor has the highest association with smoking and the worse prognosis. It is more common in men. **(Neo060)**

55. Squamous cell carcinoma of lung

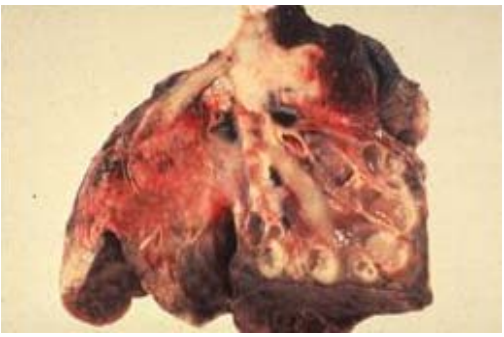

with associated findings
This slide shows a large central arising squamous cell. The upper lobe which appears dark demonstrates atelectasis from complete obstruction of the airway lumen by the cancer. Another lobe shows markedly dilated airways representing bronchiectasis with mucous plugs. This associated with incomplete obstruction of a proximal airway. The other lobe shows consolidation consistent with either golden pneumonia (endogenous lipid pneumonia) or a bacterial pneumonia secondary to incomplete obstruction. **(Neo061)**

56. Superior vena cava syndrome
This patient shows obstruction of the venous supply from the head and neck with distention of the neck veins. This is due to a neoplasm infiltrating the mediastinum and obstruction of the superior vena cava. **(Neo062)**

57. Horner's syndrome
This patient shows ptosis and miosis of the right eye due to involvement of the ipsilateral cervical sympathetic chain by local lung cancer extension. **(Neo063)**

58. Leukoplakia and invasive cancer
The slide on the right shows white patches consistent with leukoplakia, a premalignant change of the oral mucosa and tongue associated with either smokeless tobacco use or chronic irritation. The slide on the left shows a tongue with leukoplakia as well as invasive cancer (patient's right side of tongue). **(Neo064)**

59. Squamous cell carcinoma of lower lip
This patient has an ulcerated lesion of the left lower lip which is most likely a squamous cell carcinoma. The associations are pipe smoking and sun exposure. **(Neo065)**

60. Squamous cell carcinoma of esophagus

This tumor typically arises in the middle third of the esophagus and infiltrates the wall. The most common symptom is dysphagia, first for solids and then both liquids and solids. **(Neo066)**

Previous | Next

Return to Top | Return to Image Index

Pathology I Images

Syllabus | Lecture Schedule | Images - Pathology I | Images - Pathology II

Neoplasia

1 | 2 | 3 | 4 | 5 | 6 | 7 | 8 | 9 | 10 | 11 | 12 | 13 | 14

It is against copyright laws to make *electronic or printed* copies of these slides!!

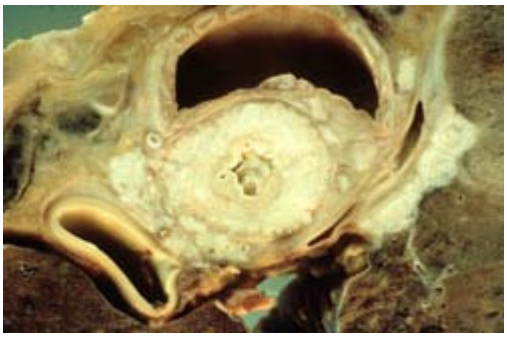

61. Squamous cell carcinoma of esophagus
This tumor has invaded the walls of local structures around the esophagus and infiltrates the wall. The most common symptom is dyphagia, first for solids and then both liquids and solids. **(Neo067)**

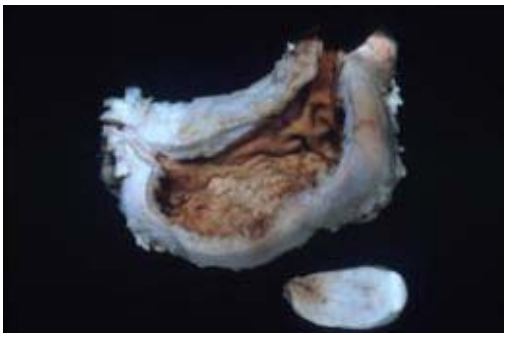

62. Linitis plastica (adenocarcinoma of the stomach (signet ring carcinoma)
This tumor invades the wall of the stomach producing a desmoplastic response. The stomach becomes hard like a leather bottle. This tumor presents late in its course and has a tendency to metastasize to the ovaries. **(Neo068)**

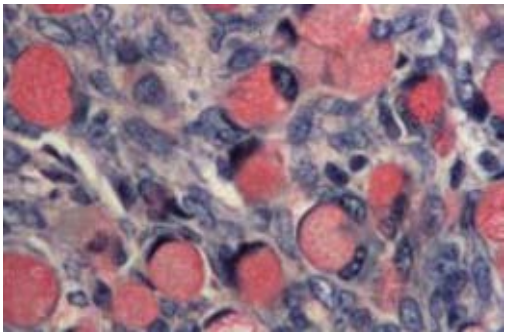

63. Krukenberg's tumor
This is a mucin stain of signet ring cells in the ovary. The tumor is a metastatic gastric carcinoma which has spread to the ovaries. **(Neo069)**

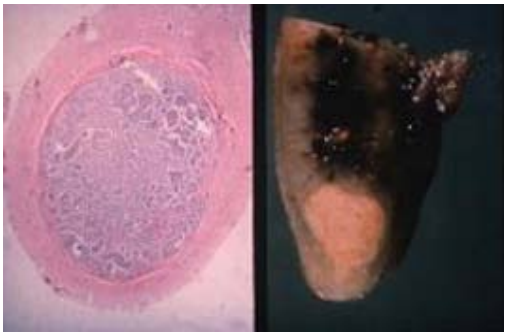

64. Carcinoid tumor of the appendix
This is the most common location of an asymptomatic carcinoid tumor. The tumor arises in the tail of the appendix from resident neuroendocrine cells (APUD cells). It is usually an incidental finding in this location. **(Neo070)**

65. Carcinoid tumor-neurosecretory granules

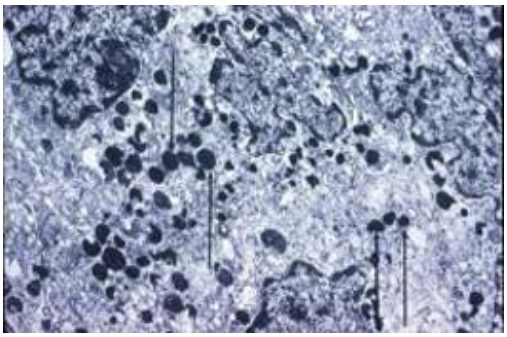

The arrows point to dark staining cytoplasmic organelles which are features of neuroendocrine tumors. **(Neo071)**

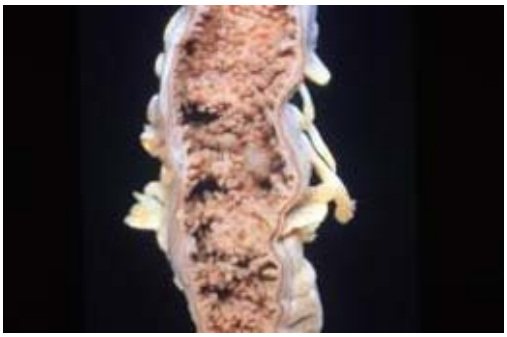

66. Familial polyposis
This autosomal dominant condition is associated with multiple tubular adenomas and tubulovillous tumors in the colon. The patient has > 100 polyps and is at risk for colon cancer. There is an association with the APC tumor suppressor gene. **(Neo072)**

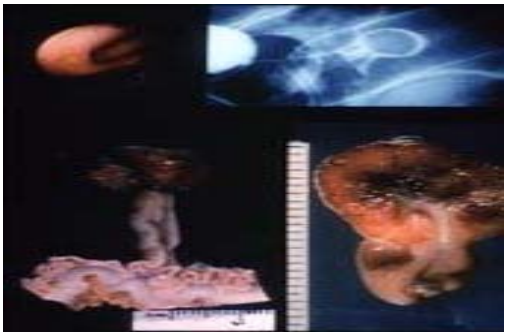

67. Tubular adenoma
There are four slide demonstrating a tubular adenoma. The slide on the upper left is a endoscopic view of the pedunculated tumor. A barium outlines the polyp. The last two slides show the pedunculated polyp. There is a slight risk of malignant transformation with tubular adenomas. **(Neo073)**

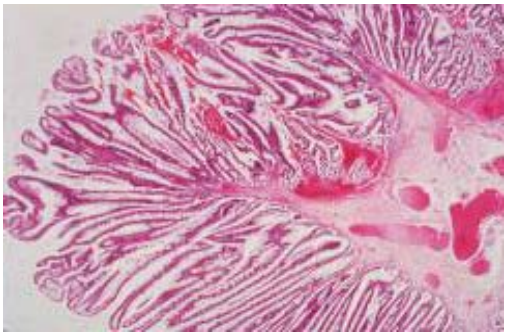

68. Villous adenoma
This is a microscopic section of a villous adenoma. Note the long stalk-like papillary projections of the tumor. These tumors are typically sessile and have a high incidence of malignant transformation. **(Neo074)**

69. Adenocarcinoma of colon
This tumor is a fungating mass with central necrosis which arises from colonic mucosa. It tends to infiltrate the wall of the colon in a "napkin-ring" fashion producing obstruction. Obstructive lesions occur in the descending colon. **(Neo075)**

70. Adenocarcinoma of the colon
This lesion is growing as a polypoid mass into the lumen of the ascending colon. Right sided colonic masses typically present with anemia and bleeding. **(Neo076)**

Previous | Next

Return to Top | Return to Image Index

Pathology I Images

Neoplasia

It is against copyright laws to make *electronic or printed* copies of these slides!!

71. Hepatocellular carcinoma
This tumor arises from hepatocytes. Conditions which predispose to this tumor include post-necrotic (post-infectious) cirrhosis, pigment cirrhosis (hemosiderosis), alcoholic cirrhosis, aflatoxins, and thorotrast. **(Neo077)**

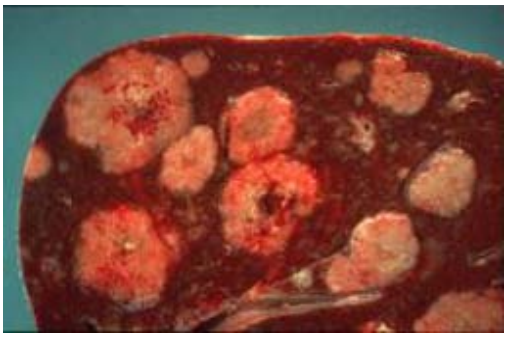

72. Metastasis to the liver
This liver shows numerous nodules, some having an umbilicated center, which are metastatic tumors. The metastasis is most likely from lung, breast, or GI tract. **(Neo078)**

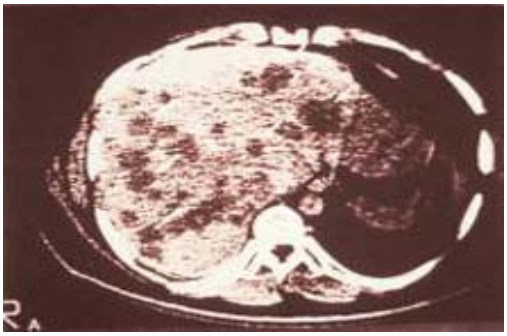

73. CT of liver with metastasis
The CT shows radiolucent areas in the liver consistent with metastatic nodules. **(Neo079)**

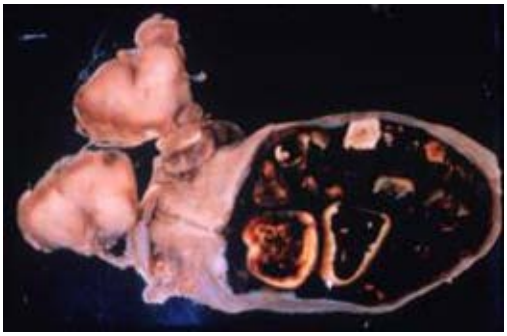

74. Cholelithiasis and carcinoma of gallbladder
This slide shows a gallbladder that is thin and fibrotic. One portion of the gallbladder wall shows a tan mass of tumor which infiltrates the attached tissues. Gallbladder cancer may arise in a setting of chronic cholecystitis and cholelithiasis. **(Neo080)**

75. Carcinoma of the pancreas
The head of the pancreas shows a large

tumor mass which is infiltrating the wall of the duodenum. This lesion will likely produce obstructive jaundice. A marker for the tumor is CA 19-9. **(Neo081)**

76. Renal cell carcinoma
This tumor arises from proximal tubular cells in the kidney and is typically in the upper pole of the kidney. It will be very vascular. The tumor presents with hematuria, flank mass, flank pain, or with paraneoplastic hormone production. The tumor tends to invade the renal vein and spread to the lungs with cannon-ball metastasis. **(Neo082)**

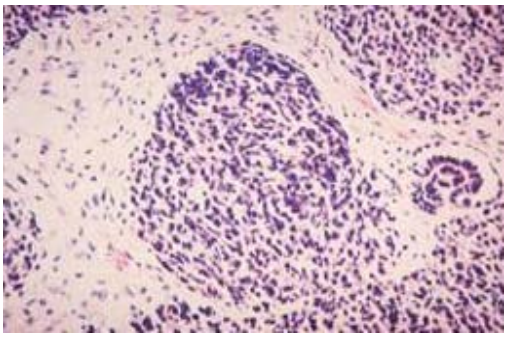

77. Wilm's tumor
This tumor arises in young children from renal primordial rests. It has tissues from two germ cell layers. Patients present with a flank mass and hypertension. **(Neo083)**

78. Transitional cell carcinoma

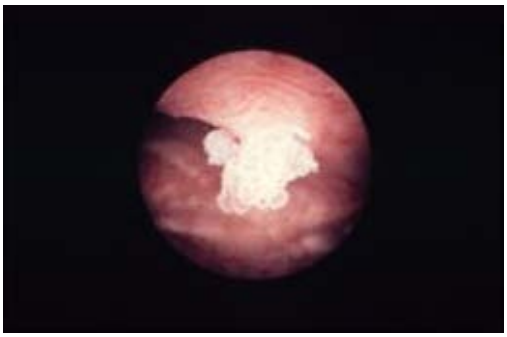

This slide shows a papillary tumor by cytoscopy. It is arising from the transitional mucosa of the bladder and usually presents with hematuria. **(Neo084)**

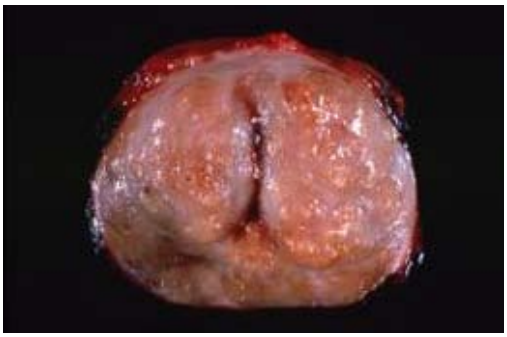

79. Carcinoma of prostate
This is an adenocarcinoma arising in the posterior lobe of the prostate. It produces a "stony-hard" consistency to the prostate on rectal exam and is painless. **(Neo085)**

80. Prostate chips
These are fragments of prostate tissue removed by the TURP procedure (transurethral prostatic resection). Each piece of tissue will be examined microscopically after they are weighed collectively. **(Neo086)**

Previous | **Next**

Return to Top | **Return to Image Index**

Pathology I Images

Neoplasia

It is against copyright laws to make *electronic or printed* copies of these slides!!

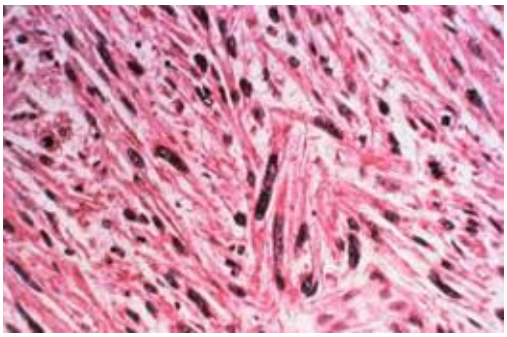

91. Leiomyosarcoma
This is the most common sarcoma of the female genital tract, although rare. It usually arises de novo. It is bulky and hemorrhagic. Microscopic grading is based on the numbers of mitoses counted per high powered field. **(Neo097)**

92. Papillary serous cystadenocarcinoma of ovary
This is the most common malignant ovarian tumor and has a high incidence of bilaterality. The tumor is derived from the surface epithelium of the ovary and the cells of the tumor resemble fallopian tube lining cells. The most solid areas of the tumor are associated with a higher grade of tumor. **(Neo098)**

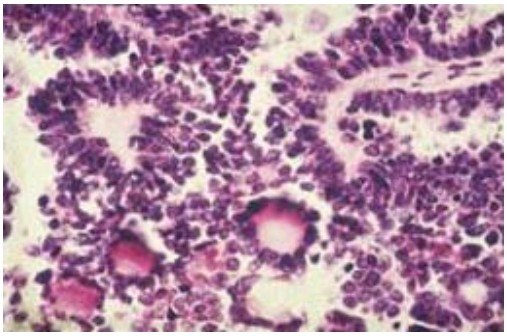

93. Papillary serous cystadenocarcinoma of ovary
This tumor is malignant and is one of the four ovarian tumors associated with calcification. The calcification are called Psammoma bodies. A marker for this tumor is CA-125. **(Neo099)**

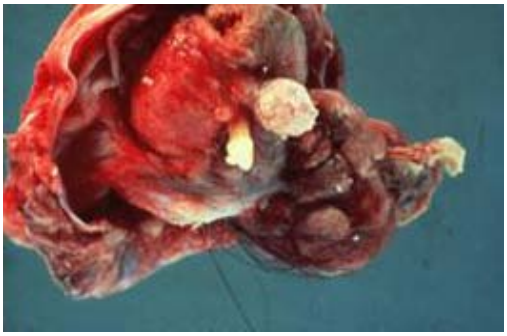

94. Cystic teratoma
This is the most common germ cell tumor of the ovary. It is benign and consists of structures derived from all three germ cell layers. The tumor frequently contains calcified tooth structures as well as hair and other structures derived from ectoderm. **(Neo100)**

95. Cystic teratoma
This teratoma is producing skin, sebaceous

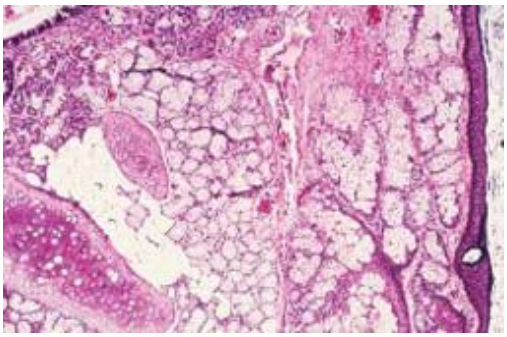

glands, bronchial mucosa and cartilage. **(Neo101)**

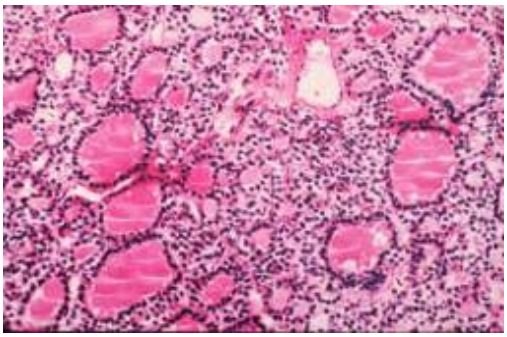

96. Struma Ovarii
This is a specialized teratoma which is producing thyroid tissue which is frequently functional. **(Neo102)**

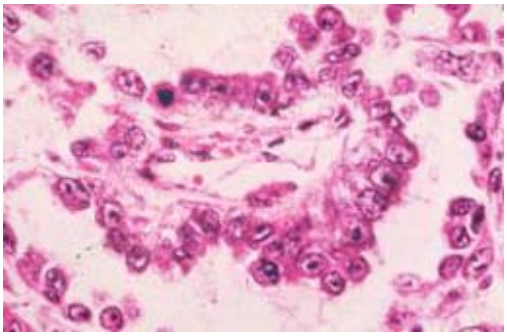

97. Schiller-Duval body (yolk sac tumor or endodermal sinus tumor)
This tumor derives from germ cell in the testis and ovary and is the most frequent testicular tumor in children. A marker of the tumor is a cluster of tumor cells surrounding a small blood vessel. This is the Shiller-Duval body. The tumor produces alpha- 1 antitrypsin and alpha-fetoprotein. **(Neo103)**

98. Meig's syndrome
Ovarian fibromas associated with a right sided pleural effusion and ascites is MEIG's syndrome. **(Neo104)**

99. Hydatidiform mole
Note the multiple-grape-like clusters associated with this neoplasm. Moles can be complete or partial. A complete mole has no embryo, a 46 XX or 46XY genotype, and is associated with choriocarcinoma. An incomplete mole has an associated embryo, 69XXY, and rare association with a choriocarcinoma. **(Neo105)**

100. Choriocarcinoma
Multiple slides show an invasive choriocarcinoma. This tumor is very aggressive and arises from gestational trophoblastic epithelium. It is common in the Asian population. No chorionic villi are formed, only cytotrophoblast and

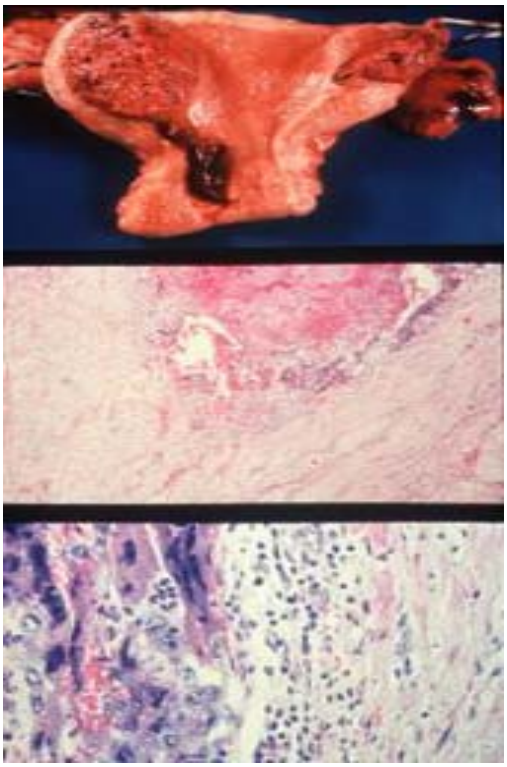

syncytiotrophoblast tissues. **(Neo106)**

Previous | Next
Return to Top | Return to Image Index

Pathology I Images

Syllabus | Lecture Schedule | Images - Pathology I | Images - Pathology II

Neoplasia

1 | 2 | 3| 4 | 5 | 6 | 7 | 8 | 9 | 10 | 11 | 12 | 13| 14

It is against copyright laws to make *electronic or printed* copies of these slides!!

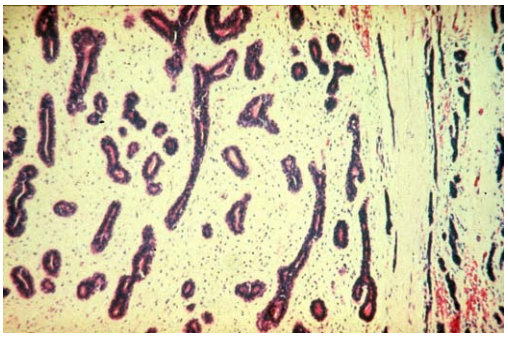

101. Fibroadenoma of breast
This tumor occurs in young females, is well-circumscribed, firm, and movable. It is composed of ductal epithelium and connective tissue. **(Neo107)**

102. Positive mammogram
Note the density in the left mammogram which has irregular margins and small calcifications. This is consistent with a neoplasm in the breast. **(Neo108)**

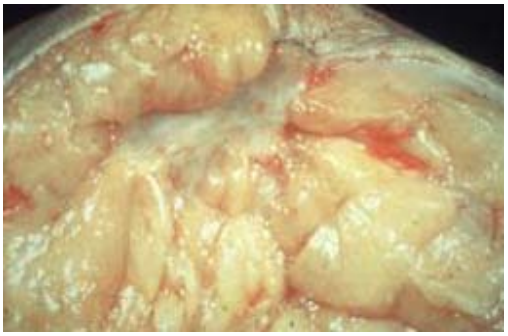

103. Adenocarcinoma of the breast
Note the area of increased density and retraction surrounded by fat. This is an area of scirrhous cancer or infiltrating ductal carcinoma of the breast. It produces retraction of the skin overlying the lesion. **(Neo109)**

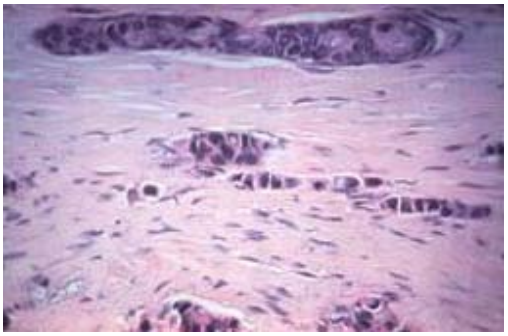

104. Infiltrating ductal carcinoma of breast
Note the tumor cells occurring in cords and nests. This type of infiltrating pattern causes desmoplasia which then leads to the firm fixed texture of the tumor. **(Neo110)**

105. Infiltrating ductal carcinoma of breast (cribiform pattern)

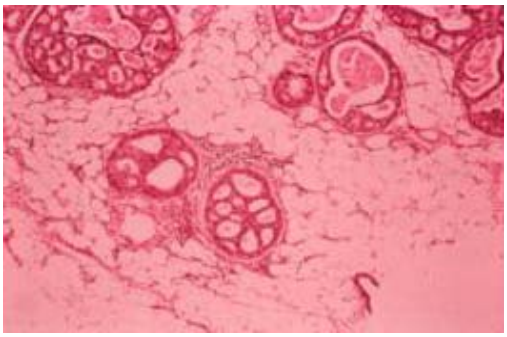

Note the collections of tumor cells with a "gland within gland" pattern. This is one of the histologic features seen in adenocarcinoma of the breast. **(Neo111)**

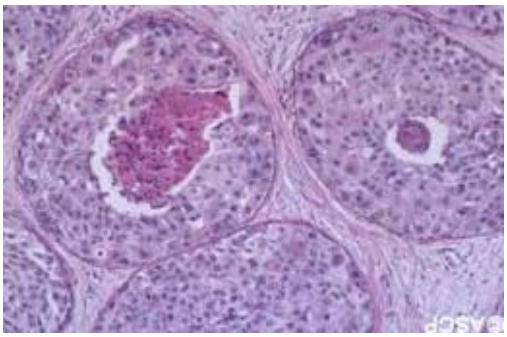

106: Comedocarcinoma of breast
This is a type of ductal cancer where the tumor is present within the ducts (intraductal) and has not infiltrated the surrounding tissues. The central area of the ducts is necrotic. This is the comedo pattern or pimple. **(Neo112)**

107: Inflammatory carcinoma of breast
Note how the left breast appears inflamed, edematous, and enlarged. This is inflammatory carcinoma which is a subtype of infiltrating ductal carcinoma. It is a very aggressive tumor with infiltration into lymphatics. **(Neo113)**

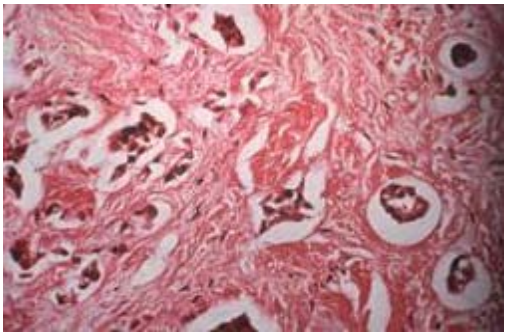

108. Inflammatory carcinoma with dermal lymphatic invasion
Note the nests of tumor cells within the dermal lymphatics of the breast. This is a poor prognostic sign. **(Neo114)**

109. Paget's disease
This is an eczematous scaly lesion of the breast which represents invasion of the nipple by adenocarcinoma cells. There will always be an underlying intraductal carcinoma of the breast. **(Neo115)**

110. Lobular carcinoma
The lobules are filled with monotonous appearing tumor cells. The entire lobule is involved but there is no spread into the surrounding tissue so this is Lobular carcinoma in situ. **(Neo116)**

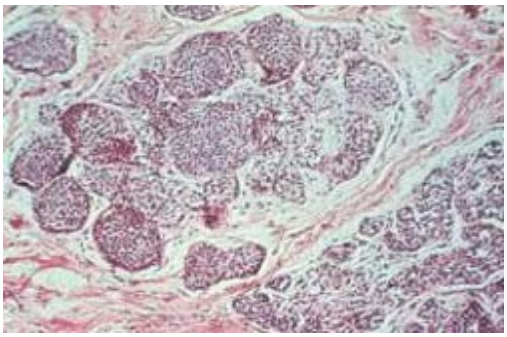

Previous | Next

Return to Top | Return to Image Index

Pathology I Images

Neoplasia

It is against copyright laws to make *electronic or printed* copies of these slides!!

111. Lymphedema
This patient has had a radical mastectomy where all of the axillary lymph nodes were removed as well as all of the breast tissue down to the chest wall. These patients have very poor lymphatic drainage of the dependent extremity and are at risk for developing a lymphangiosarcoma. **(Neo117)**

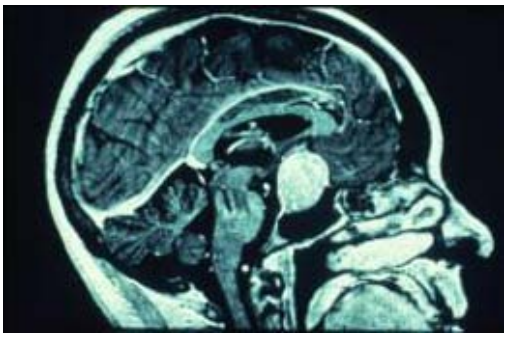

112. MRI of pituitary adenoma
Notice the midline density below the hypothalamus. This is consistent with a benign tumor of the pituitary gland. Many of these tumors are functional. The most common functional pituitary adenoma is a prolactinoma. **(Neo118)**

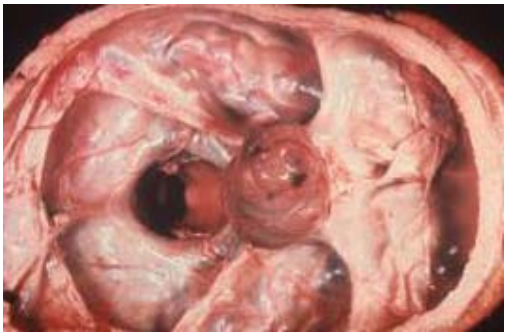

113. Pituitary adenoma
Notice the midline density below the hypothalamus. This is consistent with a benign tumor of the pituitary gland. Many of these tumors are functional. The most common functional pituitary adenoma is a prolactinoma. **(Neo119)**

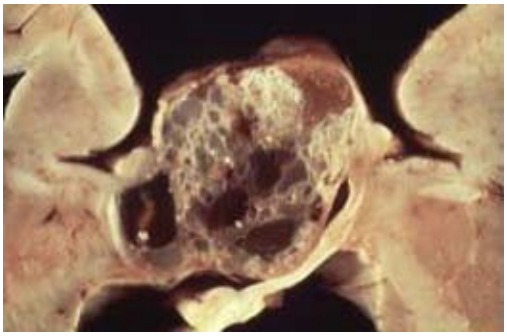

114. Craniopharyngioma
A large cystic mass is noted in the midline. These lesions frequently calcify. They arise from Ratke's pouch remnants and are the most common cause of hypopituitarism in children. **(Neo120)**

115. Carcinoma of thyroid
A large yellow mass is noted in the right

lobe of the thyroid. It appears to be infiltrating the thyroid. This would likely be a "cold" nodule on a radionucleotide scan. **(Neo121)**

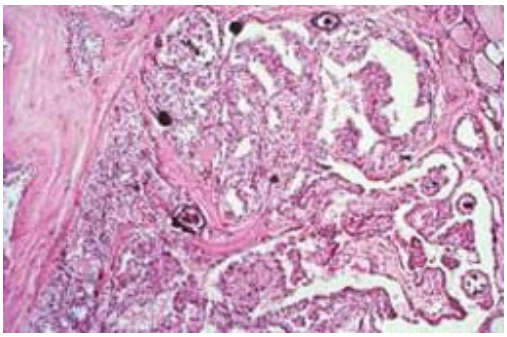

116. Papillary carcinoma of thyroid
Note the papillary projections produced by this tumor. There are calcifications in the tumor called Psammoma bodies. This tumor tends to invade through the lymphatic sytem. It is associated with prior radiation exposure to the head and neck. **(Neo122)**

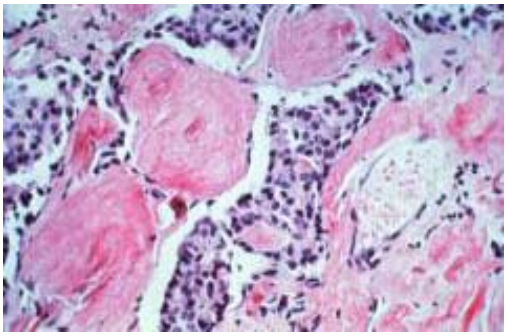

117. Medullary carcinoma of thyroid
This tumor arises from C cells of the thyroid. The stroma of the tumor is comprised of calcitonin derived amyloid. **(Neo123)**

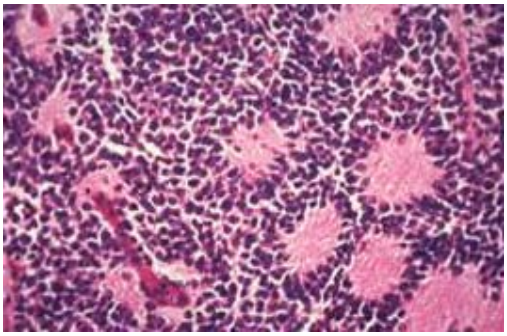

118. Neuroblastoma
This is a small cell tumor arising from the medullary portion of the adrenal or other sites in the sympathetic nervous system. It is one of the most common extracranial childhood solid tumors. The circular structures within the tumor are called Homer-Wright pseudorosettes. A marker is the n-myc oncogene. **(Neo124)**

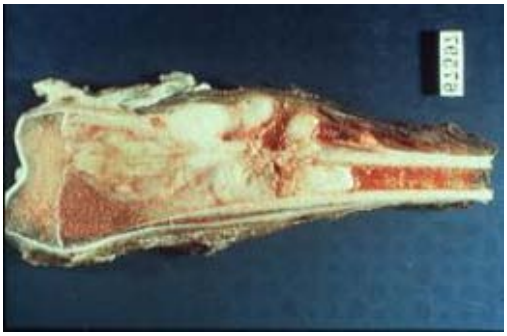

119. Osteogenic sarcoma
This tumor arises from bone forming cells. Excluding multiple myeloma, it is the most common primary malignant tumor of bone. It usually occurs in the second decade of life. Most common site is in the area around the knee. It may occur in an older age group in association with Paget's disease of bone. **(Neo125)**

120. Radiograph of osteogenic sarcoma showing "sunburst"
The tumor typically is large and ill-defined and characteristically destroys the cortex with extension inward into the marrow cavity and outwards into adjacent soft tissues. **(Neo126)**

Previous | Next
Return to Top | Return to Image Index

Pathology I Images

Syllabus | Lecture Schedule | Images - Pathology I | Images - Pathology II

Neoplasia

1 | 2 | 3| 4 | 5 | 6 | 7 | 8 | 9 | 10 | 11 | 12 | 13 | 14

It is against copyright laws to make *electronic or printed* copies of these slides!!

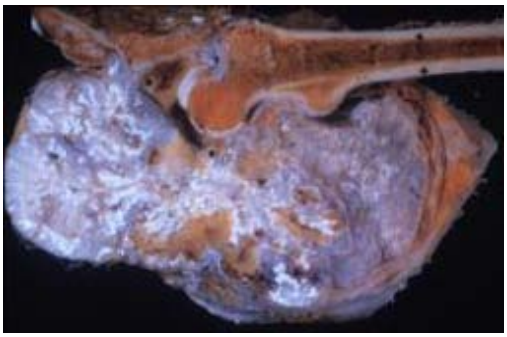

121. Chrondrosarcoma
This tumor arises from mesenchymal cells that produce a cartilaginous matrix. Chrondrosarcomas occur in older patients with a peak incidence in the sixth decade. These tumors arise in central portionsof the skeleton such as the shoulder area, pelvis, proximal femur, and ribs. **(Neo127)**

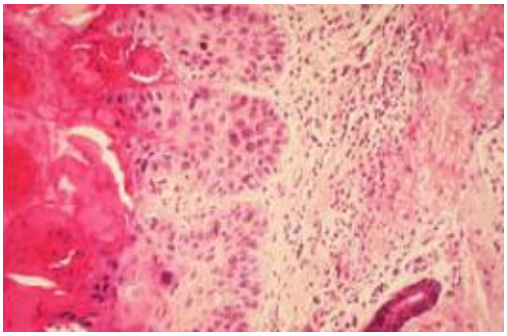

122. Actinic Keratosis
This is a premalignant lesion of the skin associated with excessive sun exposure. There is excess of keratin (hyperkeratosis) but the epidermis is thinner than normal. The stratum corneum is thickened and, unlike normal skin, the nuclei in the cells in this layer are retained (parakeratosis). The elastic tissue fibers in the dermis are thickened, and bluish-gray (elastosis). **(Neo128)**

123. Basal cell carcinoma
This tumor is associated with sun exposure. They are typically "pearly grey" papules on the side of the nose or upper lip. They rarely, if ever, metastasize. **(Neo215)**

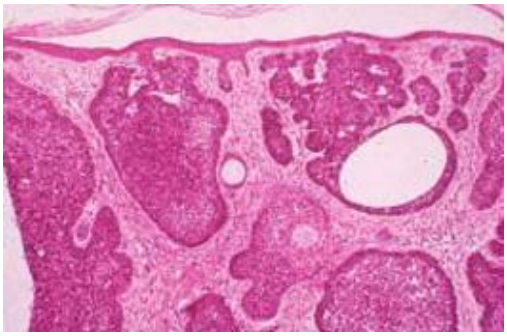

124. Basal cell carcinoma
This is a microscopic section of a basal cell carcinoma showing the tumor cell nests. The peripheral group of cells in a nest are oriented perpendicular to the rest of the cells similar to a picket fence. **(Neo130)**

125. Nevocellular nevus:

This is a pigmented lesion arising from the melanocytes in the skin. Pigmentation is generally uniform and the lesions have well-defined rounded borders. They are benign lesions. **(Neo131)**

126. Melanoma

This is a malignant tumor arising from melanocytes. A superficial spreading melanoma has a variegated pigment pattern and tends to spread along the epidermal-dermal junction in a radial or horizontal growth phase for a number of years before vertical growth begins. Superficial spreading melanomas are macules or flat and are the most common type of melanoma. They occur most commonly on women's legs and men's torsos. It is usually smaller then lentigo meligna melanoma. Pigmentation is ofter red, white, and blue, sometimes with raised, indurated edges. A nodular melanoma has only a vertical growth phase and has the worse prognosis. A vertical growth phase is signaled by a papule or nodular appearance to a melanoma. **(Neo132)**

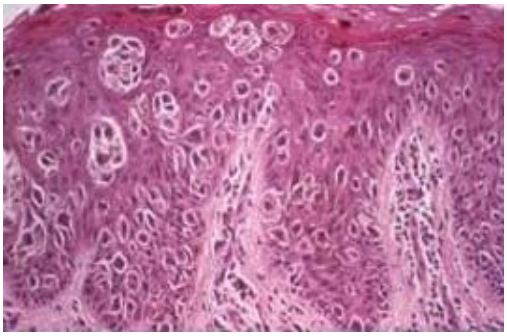

127. Malignant melanoma

This is a microscopic section of a superficial spreading melanoma showing the nests of nevus cells in the epidermis and dermis. These cells do not metastasize. If the tumor begins a vertical growth phase, then the tumor cells can metastasize. **(Neo133)**

128. Lentigo meligna melanoma

This type of melanoma typically occurs on the face in sun exposed areas in elderly patients. Malignant melanocytes invade the dermis. The lesions appear as flat, tan or brown macules with darker brown or black spots scattered irregularly on the surface of the lesion. **(Neo134)**

129. Subungual acrolentiginous melanoma

This is an uncommon type of melanoma which is the most common form found in blacks. It arises on palmar, plantar, and subungual skin and histologically resembles lentigo maligna melanoma. **(Neo129)**

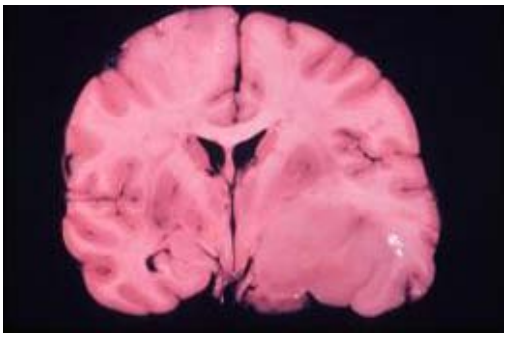

130. Astrocytoma
The left side of the cortex shows loss of the normal demarcation between grey and white matter. This is an area where the tumor has infiltrated the brain tissue with indistinct margins. Astrocytomas are the most common histologic type of primary brain tumors. They occur in the supra tentorial areas in adults and in the cerebellum in children. **(Neo136)**

Previous | Next

Return to Top | Return to Image Index

Pathology II Images

Nutrition

It is against copyright laws to make *electronic or printed* copies of these slides!!

1. Patient with bulimia:
Note the brown areas of discoloration on the teeth that represent acid injury to the enamel from repeated self-induced vomiting. The brown color is the underlying dentine of the tooth. **(Nut201)**

2. Obesity:
Obesity is defined as a body mass index (BMI) > 30 kg/m2: weight in kilograms divided by the height in meters squared. Morbid obesity is a BMI > 40 kg/m2. Hypertension is the MC complication of obesity. **(Nut202)**

3. Child with kwashiorkor: Kwashiorkor is defined as a decreased protein intake in spite of a normal caloric intake consisting primarily of carbohydrates. Note the pitting edema in the legs (decreased serum albumin), flaky paint dermatitis on

the legs, protuberant abdomen (fatty liver from decreased apolipoprotein synthesis and ascites). **(Nut003)**

4. Child with marasmus: Marasmus is a total calorie deprivation. Note the monkey like facies and broomstick extremities. **(Nut004)**

5. Eye in vitamin A deficiency: Recall that vitamin A prevents squamous metaplasia. Squamous metaplasia of corneal epithelium leads initially to focal white patches on the cornea (noted in multiple places in the eye) called Bitot's spots. **(Nut205)**

6. Eye in vitamin A deficiency:

Extensive replacement of the corneal epithelium by squamous epithelium leads to corneal softening (keratomalacia), ulcers, infection, and, ultimately, blindness. Vitamin A is the second MCC of global blindness, the first being trachoma due to Chlamydia trachomatis. **(Nut006)**

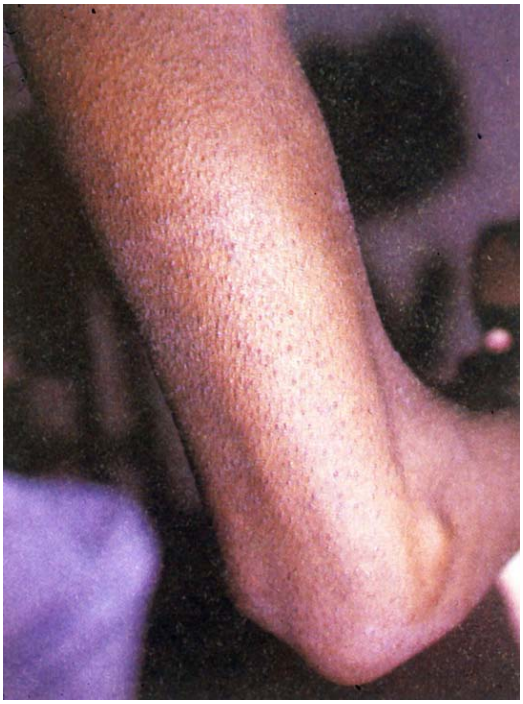

7. Patient with vitamin A deficiency:
Note the "goose-bump" appearance of the back of the arm in this patient. This represents follicular hyperkeratosis, which is an increase in squamous epithelium in the hair follicles. **(Nut206)**

8. Child with rickets:
rickets is most commonly due to vitamin D deficiency. Osteoid and cartilage do not get mineralized properly. The soft bone leads to pathologic fractures and bowing of the legs, as demonstrated in this child. **(Nut008)**

9. Patient with periorbital hemorrhage from vitamin K deficiency related to excess warfarin: Vitamin K deficiency leads to a hemorrhagic diathesis, since the vitamin K dependent factors are not g-carboxylated. This patient experienced hemorrhage into the loose subcutaneous tissue around the eye. Recall that warfarin inhibits epoxide reductase, therefore, vitamin K is in the inactive K2 form rather than the active K1 form. **(Nut009)**

10. Newborn brain with hemorrhagic disease of the newborn from vitamin K deficiency: Newborns who are not given intramuscular vitamin K at birth

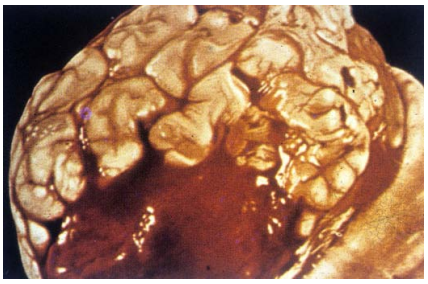

experience a drop in vitamin K levels between the 3rd to 5th day, since they do not have colonic bacteria to synthesize the vitamin that early in life. One disastrous complication of this is cerebral hemorrhage, as demonstrated in this slide. **(Nut010)**

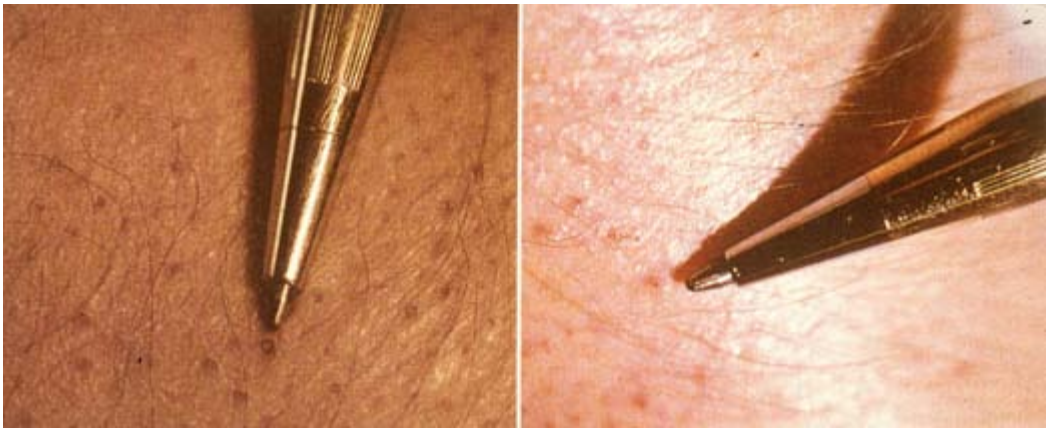

11. Skin findings in vitamin C deficiency (scurvy):
The photo on your left depicts corkscrew hairs. The photo on your right exhibits pinpoint hemorrhages around the hair follicle (perifollicular hemorrhage) related to weak collagen tissue in small vessels with subsequent rupture around the follicles. **(Nut208)**

12. Patient with scurvy:
Note the smooth, red tongue (glossitis) and the poor dentition, the latter due to weak collagen in the gums and lamina dura around the teeth. This leads to gingivitis, bleeding gums (especially after brushing the teeth), and the loss of teeth. **(Nut207)**

13. Patient with thiamine deficiency and foot drop: Note how the foot drops. This is due to a peripheral neuropathy involving the common peroneal nerve. Recall that thiamine catalyzes reactions that are important in the synthesis of ATP. ATP depletion leads to wet and dry beriberi. In addition to Wernicke's encephalopathy, peripheral neuropathy is a manifestation of dry beriberi. **(Nut013)**

14. Patient with thiamine deficiency and pitting edema: Note the dependent pitting edema in this patient. This patient has wet beriberi with

congestive cardiomyopathy and both left and right heart failure, the latter responsible for the pitting edema. **(Nut014)**

15. Patient with pellagra (niacin deficiency): This patient demonstrates the hyperpigmentation of the skin in sun exposed areas (dermatitis). Note the hyperpigmentation of the skin of the hands and around the neck, the latter called Casal's necklace. **(Nut015)**

Previous | Next

Return to Top | Return to Image Index

Pathology I Images

Hematology

It is against copyright laws to make *electronic or printed* copies of these slides!!

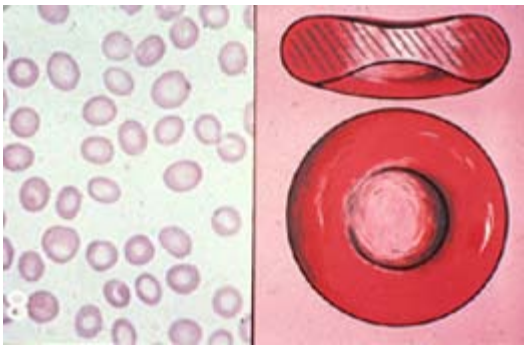

1. Normal PB smear and schematic of mature RBC
Note that RBCs are a biconcave disc. Since less Hb is concentrated in the area of depression in the membrane, it appears pale when flat on a slide, hence the central area of pallor. If the central area of pallor expands, then there is a problem with Hb synthesis, which implicates one of the microcytic anemias. If the cell is a spherocyte, there is no central area of pallor. If there is excess membrane, there is a bulge in the center of the cell collecting more Hb, hence the appearance of a target cell. Mature RBCs do not have mitochondria and use glucose for a fuel (anaerobic glycolysis). **(Hem001)**

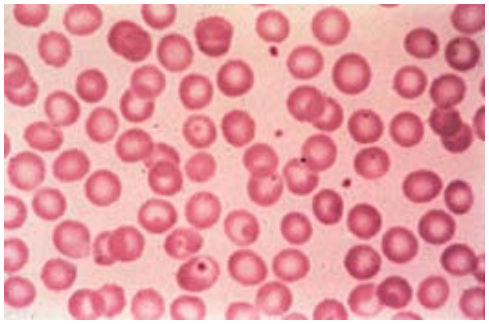

2. Asymptomatic patient
This is a normal smear. Note the uniformity of the RBCs, the normal amount of central pallor, and the compression pallor induced by platelets sitting on top of the RBC membrane. This can be confused with malarial ring forms. **(Hem003)**

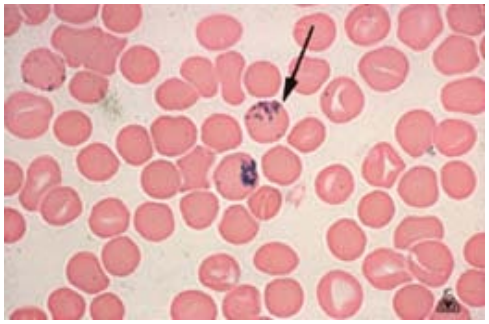

3. Supravital stain of RBCs in an asymptomatic person
Two reticulocytes are present in the slide. Reticulocytes are RBCs that within 24 hours will be changed into a mature biconcave disc by macrophages in the spleen. The supravital stain identifies RNA filaments, indicating that the cell is still synthesizing Hb. The reticulocyte count is the most important test to order after identifying an anemia since it tells the clinician how the bone marrow is responding to the anemia. **(Hem004)**

4. Reticulocyte stain
Note the RNA filaments in these young RBCs. **(Hem200)**

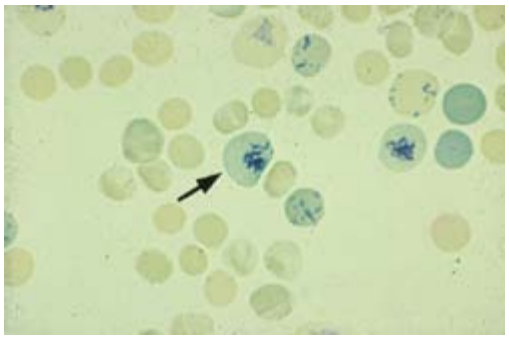

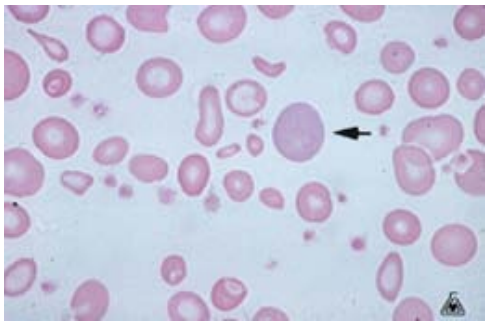

5. PB in a 9 year old child with b-thalassemia major and a severe microcytic anemia and elevated reticulocyte count
The arrow points to a marrow reticulocyte or shift cell, which, unlike a peripheral blood reticulocyte, requires 48-72 hours before it becomes a mature RBC and has a bluish discoloration (polychromasia). In severe thalassemia, the excess production of a-chains are toxic to RBCs causing a hemolytic anemia. Stimulation of marrow erythropoiesis causes the release of polychromasia cells as well as nucleated RBCs. In a reticulocyte count, the count must first be corrected for the degree of anemia and then further corrected (divide by 2) if polychromasia is present, since they have RNA filaments like PB reticulocytes and would falsely increase the reticulocyte count. **(Hem005)**

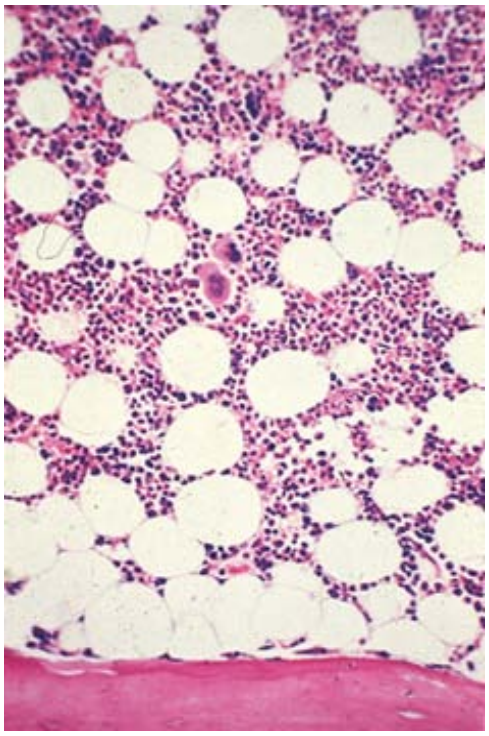

6. Normal bone marrow
Note the proportion of cells to fat is ~70 cells to 30 fat. Large cells are megakaryocytes. Cells with round nuclei are either nucleated RBCs or young neutrophils (myelocytes, etc). Cells with "squiggly" nuclei are segmented neutrophils and bands. The normal myeloid to erythroid ratio is usually 3/1 indicating more WBCs than RBCs in the marrow. **(Hem006)**

7. Patient with anemia and jaundice
What is the most likely diagnosis?
This child most likely has sickle cell disease. Note the pallor of the lips, scleral icterus, and chipmunk facies (prominent

zygomatic bones) due to marrow expansion from excessive erythropoiesis. Sickle cells are removed by macrophages, hence releasing large amounts of unconjugated bilirubin. **(Hem007)**

8. Skull x-ray from a child with sickle cell disease
Note the expansion of the marrow cavity in the skull giving it a "hair on end" appearance. Frontal bossing and prominence of the zygomatic bone is also noted. These changes occur owing to massive erythropoiesis in the bone marrow and indicate a severe hemolytic anemia (e.g., sickle cell disease, thalassemia major). **(Hem008)**

9. Patient with a severe anemia. What is the most likely diagnosis?
She has a classic chipmunk face from prominence of her zygomatic bones. This indicates expansion of the marrow space by a brisk erythropoiesis. Since she is black, the most likely diagnosis is HbSS disease. **(Hem009)**

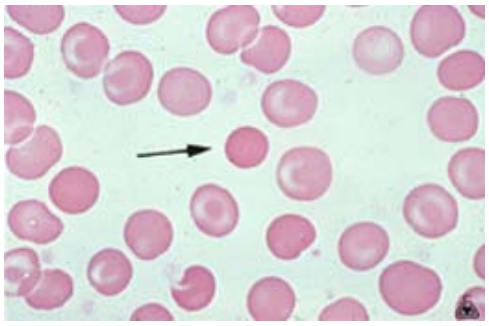

10. PB in an asymptomatic patient who had his spleen removed 10 years ago following its rupture in a car accident
The arrow points to a spherocyte. In the background are target cells (cells with a bullseye center). Both types of RBCs are commonly seen post-splenectomy. Unlike spherocytes, which have too little membrane ("skinny RBC"), hence forming a sphere rather than a biconcave disc, target cells have excessive membrane ("obese RBC"), hence forming a bulge in the middle that collects more Hb. Howell Jolly bodies and reticulocytes, and siderocytes may also be present in the PB. **(Hem012)**

Previous | Next
Return to Top | Return to Image Index

Pathology I Images

Hematology

It is against copyright laws to make *electronic or printed* copies of these slides!!

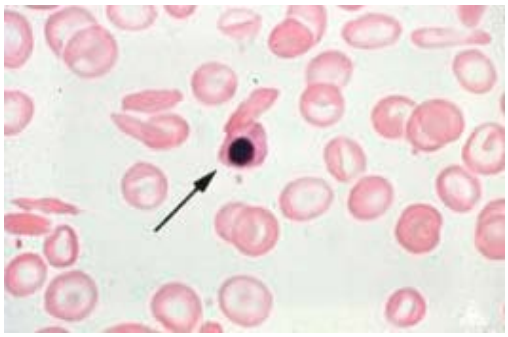

11. PB from a patient with sickle cell disease
Note the nucleated RBC (NRBC), sickle cells, and target cells, which are markers of a hemoglobinopathy. NRBCs are commonly seen when patients are briskly hemolyzing and overtaxing the bone marrow. **(Hem016)**

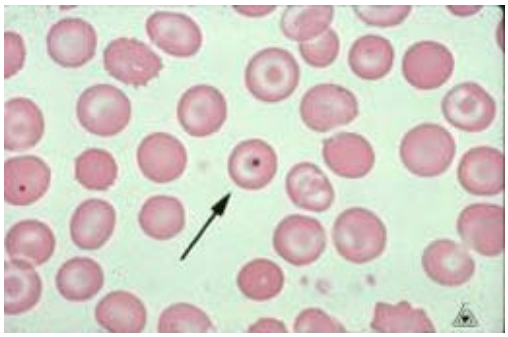

12. PB in an asymptomatic patient who had a surgical scar in the LUQ
The arrow is pointing to a target cell containing a remnant of nucleus called a Howell Jolly body. The patient had a ruptured spleen after a car accident and had his spleen removed. Note the increase in target cells. Target cells are increased after splenectomy, in hemoglobinopathies, and in alcoholics with liver disease. **(Hem017)**

13. PB demonstrating rouleaux and agglutination
Rouleaux (stack of coins) is associated with an increase in IgG or fibrinogen, while agglutination seen with an increase in IgM, which owing to its pentameric configuration is able to bridge the negative charge around RBCs and agglutinate them. Cold agglutinins contain IgM antibodies, which clump RBCs in digital vessels in cold weather and produce Raynaudâ€™s phenomenon. **(Hem018)**

14. Patients fingers: there is a history of craving for eating ice chips and a severe microcytic anemia
The nails exhibit spooning or koilonychia, a characteristic feature of iron deficiency. **(Hem019)**

15. Patient with a severe microcytic anemia and dysphagia for solids (not

liquids)
Note the cracking at the angles of the mouth (cheilosis, stomatitis). With a history of a microcytic anemia, and dysphagia for solids, the patient probably has the Plummer Vinson syndrome with iron deficiency producing an esophageal web, glossitis, cheilosis, and achlorhydria. **(Hem020)**

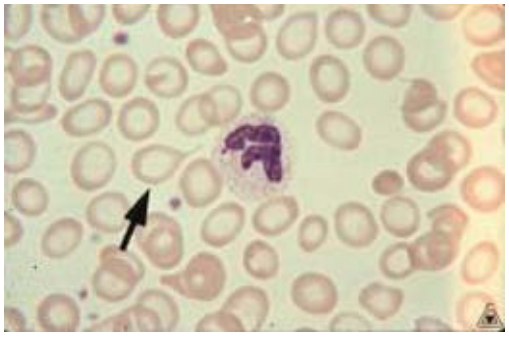

16. PB from a 4 year old child with a microcytic anemia and an increase in the RDW. What is the most likely diagnosis?
The cells are hypochromic. The most likely cause is iron deficiency secondary to GI blood loss, most often a bleeding Meckelâ €™s diverticulum. **(Hem021)**

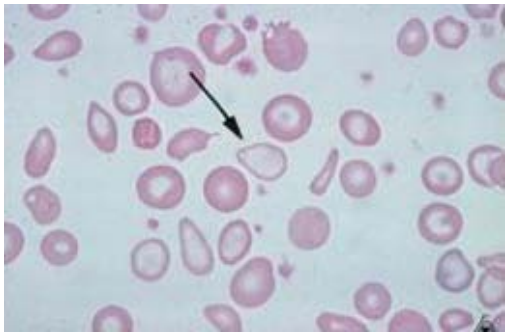

17. PB in a 22 year old woman with menorrhagia and a microcytic anemia with an increase in the RDW. What is the most likely diagnosis?
The findings illustrate marked variation in the size of the RBCs, hence the increase in the RDW, and pronounced hypochromasia, indicating a defect in Hb synthesis. With a history of menorrhagia, iron deficiency is most likely present. Iron deficiency is the only microcytic anemia with an increase in RDW. Serum ferritin should be low in this patient. **(Hem022)**

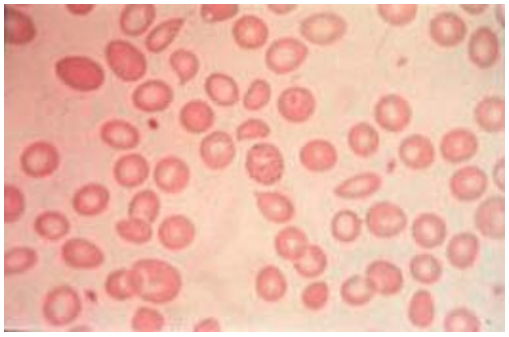

18. PB in a patient with b-thalassemia minor and a mild microcytic anemia
Note the tear drops cells, and cells with a fine stippled appearance, the latter representing persistence of ribosomes (basophilic stippling). This is a nonspecific finding in any anemia with a defect in Hb synthesis, which characterizes the microcytic anemias. Thalassemias characteristically have an elevation in the RBC count. **(Hem023)**

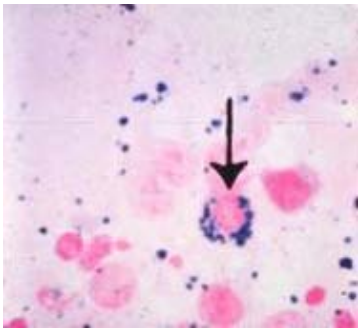

19. BM with a Prussian blue stain in an alcoholic with a microcytic anemia
The patient has a sideroblastic anemia. The ringed sideroblast in the slide represents a nucleated RBC with iron trapped in the damaged mitochondria (alcohol is a mitochondrial poison). Damage to the mitochondria interferes with normal heme synthesis. Siderocytes with iron (Pappenheimer bodies) often accompany sideroblastic anemias. Alcohol is the most common cause of acquired sideroblastic anemia. Pyridoxine deficiency and Pb poisoning are additional

causes. **(Hem024)**

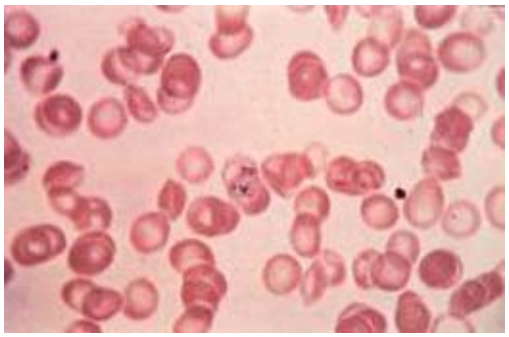

20. PB from the alcoholic with microcytic anemia

Note the irregular dark inclusions in the RBCs. These are clumps of hemosiderin in the cytosol called Pappenheimer bodies and the cells are called siderocytes (sideroblasts are NRBCs in the bone marrow). These are present in iron overload diseases, in this case, alcohol induced sideroblastic anemia. **(Hem025)**

Previous | **Next**
Return to Top | **Return to Image Index**

Pathology I Images

Hematology

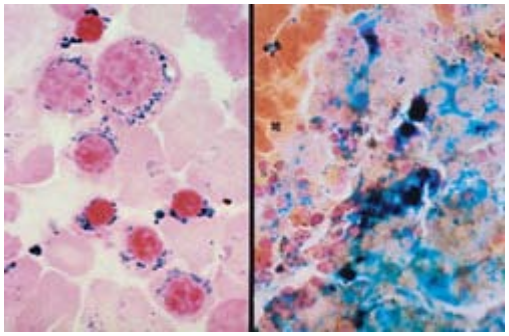

21. BM with Prussian blue stain in a patient taking INH for an active case of TB who has a microcytic anemia. What is the most likely diagnosis?
Iron stores are increased and ringed sideroblasts are present indicating a defect in heme synthesis. INH produces deficiency of pyridoxine (B6), which is a cofactor in the reaction between glycine and succinyl CoA to form D ALA. Iron enters the mitochondria but cannot exit the mitochondria, so it accumulates in mitochondria located around the nucleus and produces the ringed sideroblast (ring around the collar). **(Hem026)**

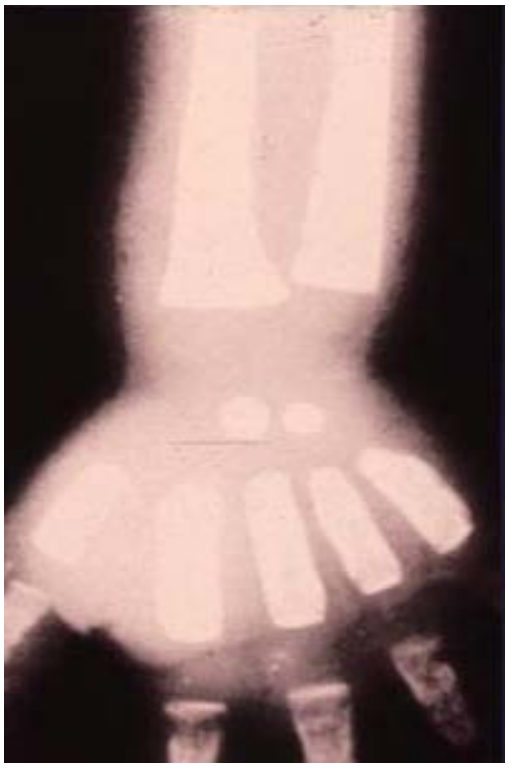

22. X-ray of hand of 9 month old black child with dactylitis and sickle cell disease
Note the white out of the bones owing to infarction and the densities in the epiphyses of the digits, the latter indicating lead poisoning. Pb is the only heavy metal that deposits in the epiphyses. **(Hem027)**

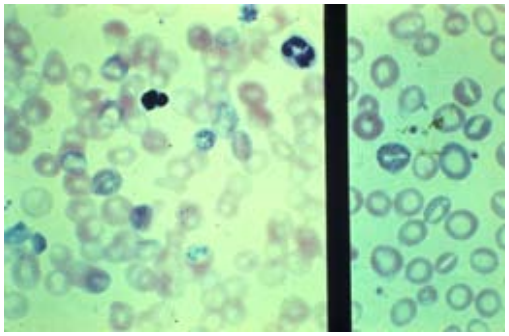

23. PB from the 9 month old child with severe microcytic anemia and a history of eating paint chips from his crib
The PB exhibits classic coarse basophilic stippling owing to denaturation of ribonuclease by Pb. Basophilic stippling is due to persistence of ribosomes (Pb denatures ribonuclease). Note also the hypochromic microcytic cells owing to a defect in heme synthesis (ferrochelatase and ALA dehydrase are denatured by Pb).

There is an increase in RBC protoporphyrin and d ALA **(Hem028)**

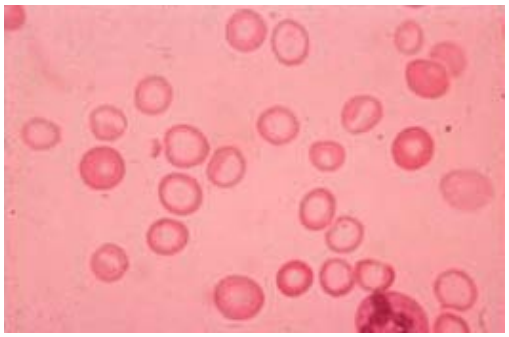

24. PB finding in a 35 year old man with epigastric distress, dark stools, and a microcytic anemia. What is the most likely diagnosis?
The smear shows marked microcytosis and hypochromasia and the history suggests GI blood loss, most likely from a bleeding duodenal ulcer. **(Hem029)**

25. Teeth of a patient with a peripheral neuropathy and normal anion gap metabolic acidosis. What is the most likely diagnosis
A lead line is noted along the gum margin. In adults lead poisoning targets the peripheral nervous system producing foot drop (peroneal nerve palsy), wrist drop (radial nerve palsy), claw hand (ulnar nerve palsy) and the kidneys (proximal renal tubular acidosis), owing to the toxic effect of Pb (coagulation necrosis) on renal tubular cells in the proximal tubule. Patients lose amino acids, glucose, phosphate, and uric acid in the urine. **(Hem030)**

26. Physical diagnostic finding
You would expect what type of anemia in the patient? Koilonychia is present which suggests iron deficiency. **(Hem031)**

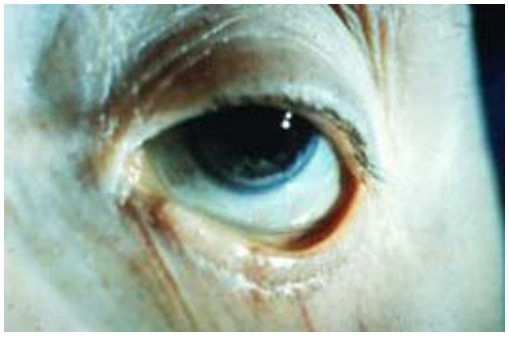

27. Physical diagnostic finding
Playing odds, what anemia would you expect in this patient? Iron deficiency anemia. Note the pale conjunctiva. **(Hem032)**

28. Physical findings in a patient compared to a normal hand
What is the difference? The patientâ€™s nail beds are pale and the palmar creases are pale compared to normal indicating anemia. **(Hem033)**

29. BM from a 65 year old woman with

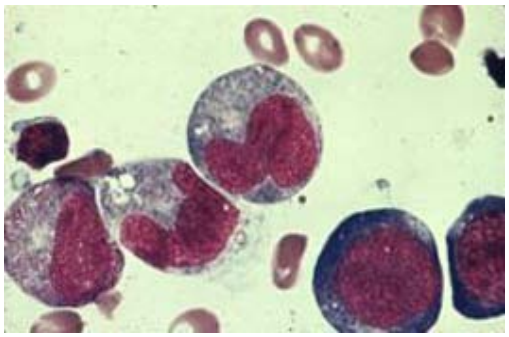

a macrocytic anemia, pancytopenia, and absent vibratory sensation in the lower extremities. What is the most likely diagnosis?
The BM shows megaloblastic RBC and WBC precursors consistent with B12/folate deficiency, in this case, the former owing to the neurological findings of posterior column disease. These large cells are destroyed outside the sinusoids in the marrow by macrophages, hence producing pancytopenia, a possibility for unconjugated hyperbilirubinemia with jaundice, and a marked increase in serum LDH from the destroyed RBCs. **(Hem035)**

30. PB in a 35 year old alcoholic with a macrocytic anemia. What is the most likely diagnosis?
The slide exhibits a hypersegmented neutrophil (pathognomonic of B12 or folate deficiency) and a mature lymphocyte. The RBCs are macroovalocytes (egg shaped). The most likely origin is folate deficiency owing to only a 3-4 supply of folate in the liver. Alcohol also blocks the reabsorbtion of folate in the jejunum. Serum folate, RBC folate, and B12 levels should be ordered. **(Hem036)**

Previous | **Next**
Return to Top | **Return to Image Index**

Pathology I Images

Hematology

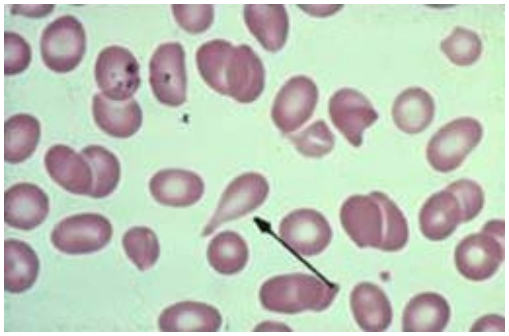

31. PB in a 67 year old woman with a macrocytic anemia
The arrow points to a tear drop cell, which may be seen in patients with B12 deficiency, myelofibrosis, and thalassemia. The other RBCs are macroovalocytes. The patient has pernicious anemia. **(Hem037)**

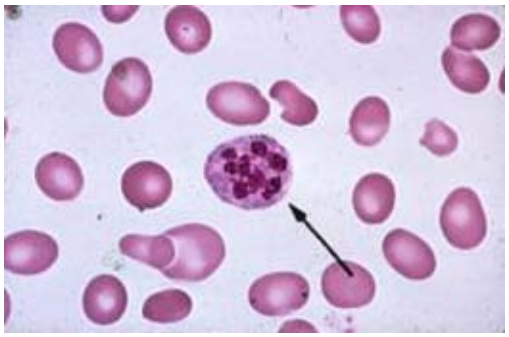

32. PB from a patient with Crohnâ€™s disease and a macrocytic anemia
What is the most likely diagnosis?
The WBC is hypersegmented indicating either B12 or folate deficiency. Since the terminal ileum is involved in 80% of cases of CD, the most likely diagnosis is B12 deficiency, since it is absorbed in the terminal ileum. **(Hem038)**

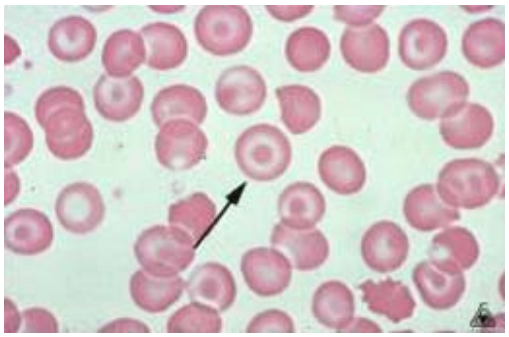

33. PB in an alcoholic with alcoholic hepatitis and a macrocytic anemia
What are these cells called? Note the round, macrocytic target cell. Alcohol increases the cholesterol in the RBC membrane resulting in excess membrane and target cell formation. Hypersegmented neutrophils are not present in this type of macrocytic anemia. **(Hem039)**

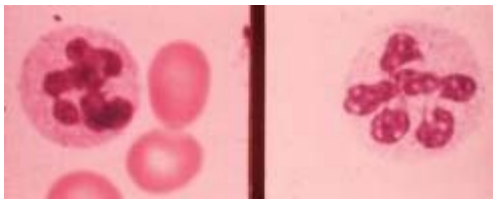

34. PB findings in a woman on birth control pills who has a mild macrocytic anemia
What is the most likely diagnosis? Note the 2 hypersegmented neutrophils indicating B12 and/or folate deficiency. Birth control pills inhibit the uptake of the monoglutamate form of folate in the jejunum, hence producing a folate deficiency. **(Hem040)**

35. BM from a patient with pancytopenia and hepatitis C
The BM is aplastic. Interspersed among the adipose cells are scattered lymphocytes. Hepatitis C is the most common infectious cause of aplastic anemia, a stem cell disorder involving suppression of the trilineage myeloid stem

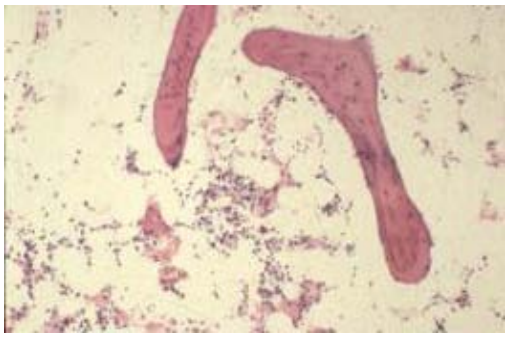

cell. **(Hem041)**

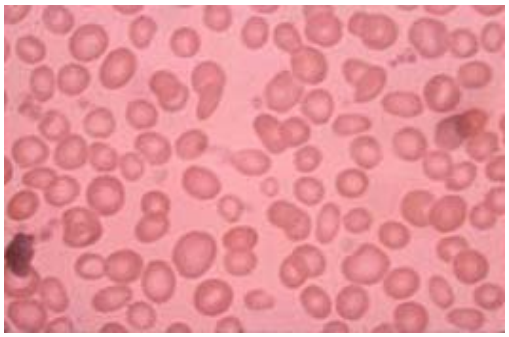

36. PB finding in a patient with celiac disease, a normocytic anemia, and an increased RDW
Note the two populations of RBCs (dimorphic), both small and large cells, the former representative of iron deficiency and the latter folate/B12 deficiency secondary to malabsorption in celiac disease. Since the MCV is a mean of the average size of the RBCs, the MCV is normal, however, the RDW, which detects size variations is increased. Malabsorption and the myelodysplastic syndrome are common causes of dimorphic RBC populations. **(Hem042)**

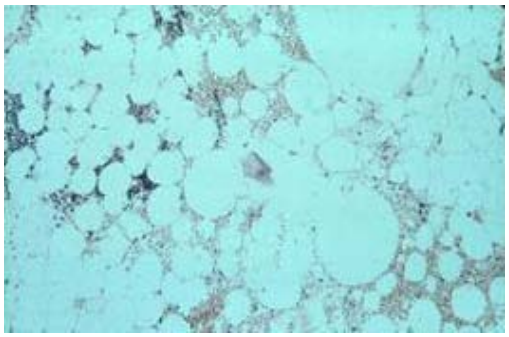

37. BM finding in a patient.
What would you expect the CBC to show? The patient has an aplastic anemia, hence one would expect pancytopenia.
(Hem043)

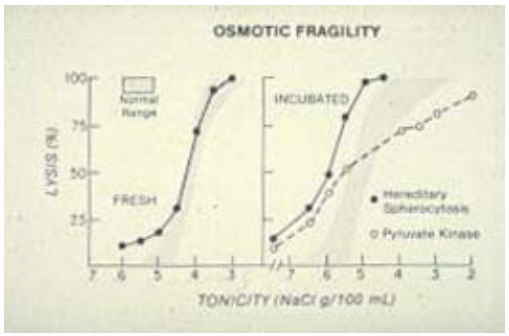

38. Schematic of the nonincubated and incubated osmotic fragility test for congenital spherocytosis and pyruvate kinase (not discussed)
Note that in spherocytosis, the cells lyse more easily than normal cells in hypotonic salt solutions because they have less membrane than normal RBCs and no extra space to contain water and salt. Note that incubation makes the defect more pronounced. **(Hem044)**

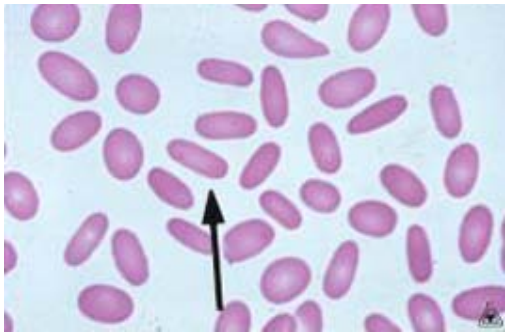

39. PB from a 26 year old woman with acute cholecystitis and a mild normocytic anemia with an increased corrected reticulocyte count
The patient has hereditary elliptocytosis, an AD disease, with either a defect in spectrin (similar to spherocytosis) or protein 4.1 in the RBC membrane. Increased extravascular hemolysis by macrophages in the spleen increases the release of unconjugated bilirubin, which increases the amount of bilirubin metabolized in the liver and excreted in

the bile, hence predisposing to calcium bilirubinate stones. **(Hem045)**

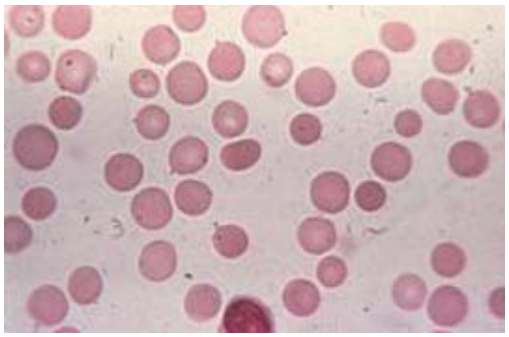

40. PB from a 27 year old with splenomegaly and a mild normocytic anemia with an elevated corrected reticulocyte count

The patient has congenital spherocytosis, an AD disease with a defect in spectrin in the cell membrane causing the cell to lose membrane ("skinny RBC") and form a sphere rather than a biconcave disc. Spherocytes are trapped and removed by macrophages in the cords of Billroth (extravascular hemolysis). Osmotic fragility testing confirms the diagnosis. **(Hem046)**

Previous | **Next**

Return to Top | **Return to Image Index**

Pathology I Images

Hematology

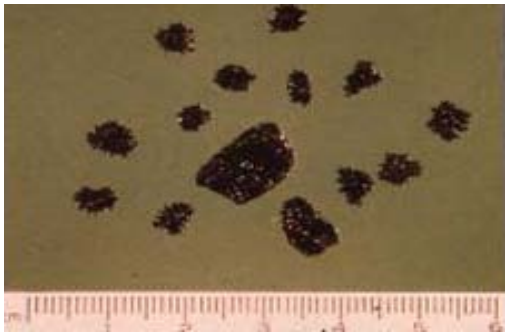

41. Gallstones removed from a 22 year old female with a chronic hemolytic anemia. What is the most likely diagnosis?
The stones are calcium bilirubinate stones, which indicate the presence of increased generation of unconjugated bilirubin from extravascular hemolysis in a chronic hemolytic state such as congenital spherocytosis or sickle cell disease. The excess amount of conjugated bilirubin that will be generated from metabolism of the unconjugated bilirubin will combine with calcium to form these small, jet black stones. **(Hem047)**

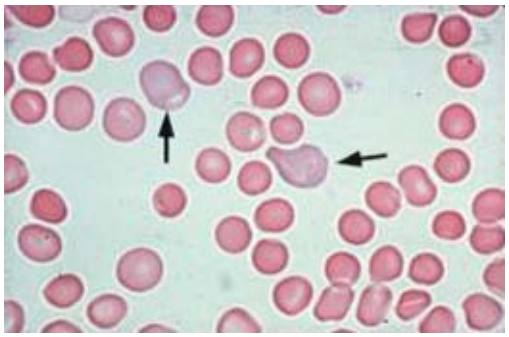

42. PB from a patient with a brisk hemolytic anemia. What is the most likely diagnosis?
Note the presence of spherocytes and polychromasia, the latter indicating a pronounced erythropoiesis in the bone marrow, which is common in hemolytic anemias like congenital spherocytosis or autoimmune hemolytic anemia. **(Hem049)**

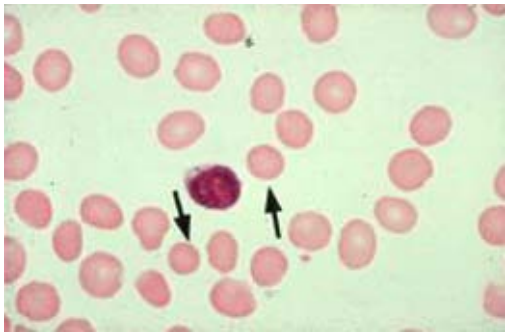

43. PB from a patient with jaundice and a mild normocytic anemia with an increased corrected reticulocyte count. What is the most likely diagnosis?
The arrows point to spherocytes in a patient with congenital spherocytosis (AD disease). A lymphocyte is present in the center of the slide. Jaundice is due to extravascular hemolysis by macrophages and increased production of unconjugated bilirubin. **(Hem050)**

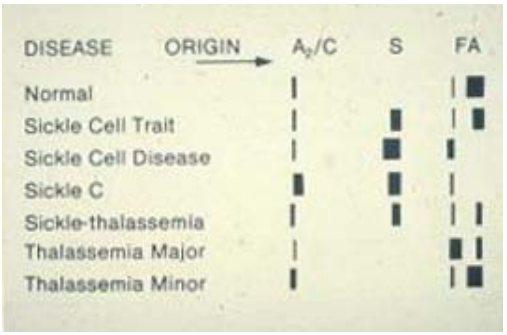

44. Hb electrophoresis patterns in various hemoglobinopathies
Note the normal migration sites for a normal person with HbA, HbA2, and HbF. Patients with HbSA (trait) have ~40% HbS, with the remainder representing A, A2 and F. In HbSS (disease), there is no HbA and varying amounts of HbF, the latter a potent inhibitor of sickling (the more the better). b-Thal major has a proportionately greater concentration of HbF than all the other types, while b-thal minor has a slightly increased amount of F

and A2. **(Hem051)**

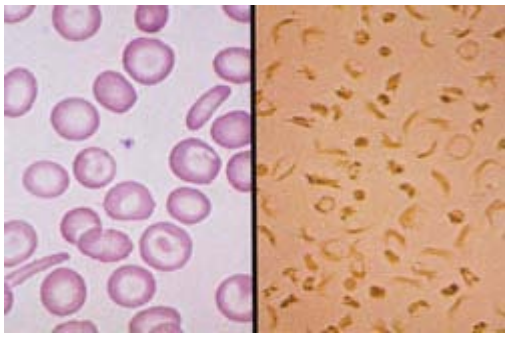

45. PB and sickle cell prep. Note the sickle cells and target cells in the PB and how the sickle prep resulted in sickling of most of the cells. Sodium metabisulfite is used to reduce oxygen tension in the test tube hence precipitating sickling. It is a more sensitive and specific test than the solubility test using dithionite. **(Hem052)**

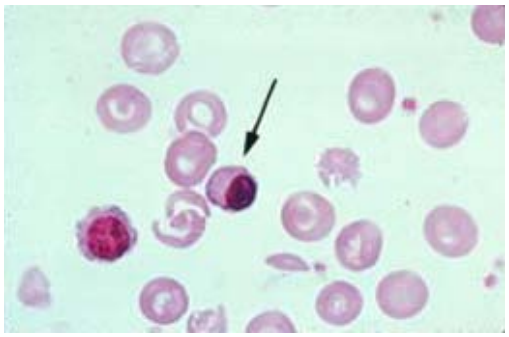

46. PB finding in a patient with sickle cell disease. The cell in question is a nucleated RBC with a background of target cells (bulls-eye appearance) and a mature lymphocyte for comparison. Note that an NRBC has a more pyknotic (ink dot) appearance than a lymphocyte. In brisk hemolytic episodes, NRBCs may be released from the bone marrow. **(Hem053)**

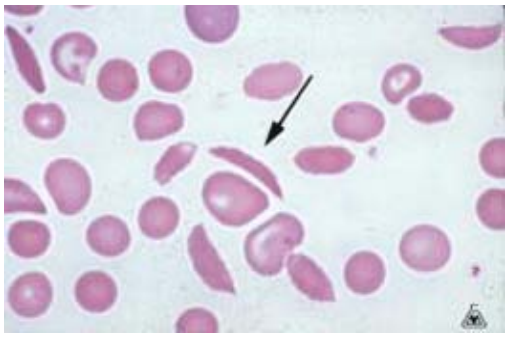

47. PB from a 9 month old black child with painfully swollen hands and feet
The patient has sickle cell disease and is presenting with dactylitis (infarctions in the bones of the digits). Note the sickle cells and the target cells in the background. HbS is the substitution of valine for glutamic acid in the sixth position of the b-chain. **(Hem054)**

48. Hands from the 9 month old black child with sickle cell disease and dactylitis, the first manifestation of sickle cell disease
HgF protects the child from this complication for the first few months by inhibiting sickling. **(Hem055)**

49. Two year old child with sickle cell disease: What does the RBC finding signify in this patient?
Note the single RBC with a Howell Jolly body (nuclear remnant). This indicates that the patient's spleen is non-functional. **(Hem223)**

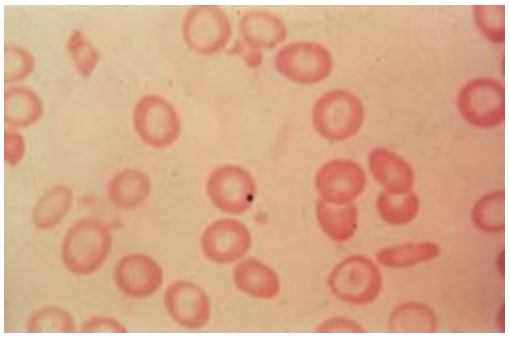

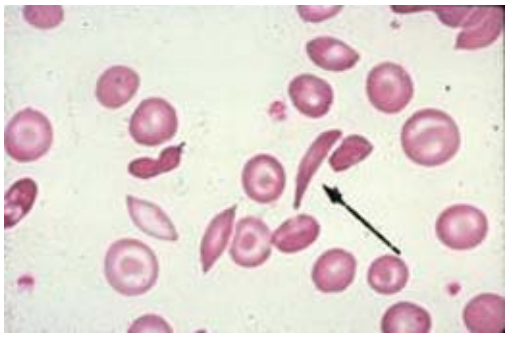

50. PB in a 22 year old black man with chest pain. What is the most likely diagnosis?

The patient has sickle cell disease (note sickle cells and the background of target cells) and the acute chest syndrome. The latter is associated with fever, hypoxemia, a pulmonary infiltrate, and pleuritic chest pain. It is treated with oxygen and blood transfusion. **(Hem058)**

Previous | **Next**
Return to Top | **Return to Image Index**

Pathology I Images

Hematology

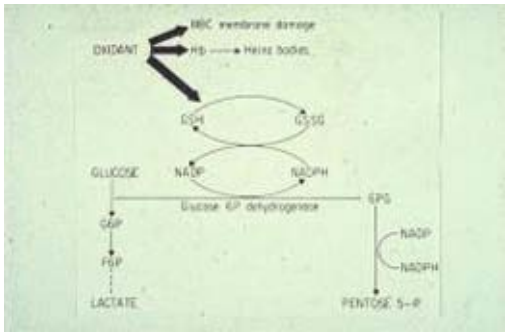

51. Schematic of the pentose phosphate shunt and G6PD deficiency
Note that the absence of G6PD (SXR disease) reduces the production of NADPH (this shunt is most responsible for this substrate) and glutathione (GSH) which neutralizes peroxide and other free radicals (acetaminophen FR). Peroxide is a by-product of every living cell, hence the need for GSH and catalase in peroxisomes for neutralizing peroxide. In the RBC, peroxide may increase in the presence of oxidizing agents (primaquine, dapsone) or infection, the latter representing the most common precipitating cause of RBC hemolysis in the enzyme deficiency. Left unneutralized, peroxide denatures Hb (forms Heinz bodies) and damages SH-groups in the RBC membrane resulting in an intravascular hemolytic anemia. It should not be surprising that infection is the most common precipitating event, because the oxygen dependent MPO system requires NADPH as a cofactor with NADPH oxidase to generate superoxide for the most potent of the bactericidal systems in neutrophils and monocytes. **(Hem059)**

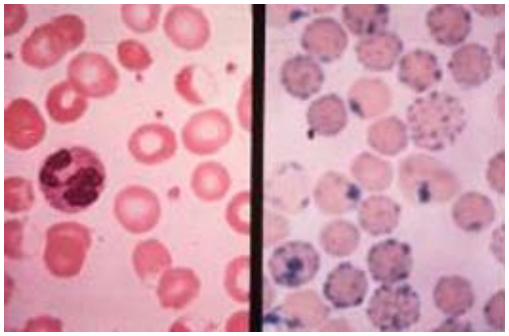

52. PB on the left and special supravital stain on the right in a black man who developed a hemolytic anemia when he took primaquine for malaria.
The patient has G6PD deficiency, or Heinz body anemia. The absence of the enzyme reduces the amount of glutathione synthesized which is necessary to neutralize peroxide in the RBC when infections occur or oxidizing drugs are used. Peroxide damages the Hb producing Heinz bodies and damages the sulfhydryl groups in the RBC membrane, producing a predominantly intravascular hemolysis. The Heinz body prep is best to diagnose the disease in the active stage of hemolysis, while the enzyme assay confirms the diagnosis when hemolysis has subsided and new RBCs are synthesized that are either deficient in the enzyme or contain a defective enzyme that degrades

as the RBC matures. **(Hem60)**

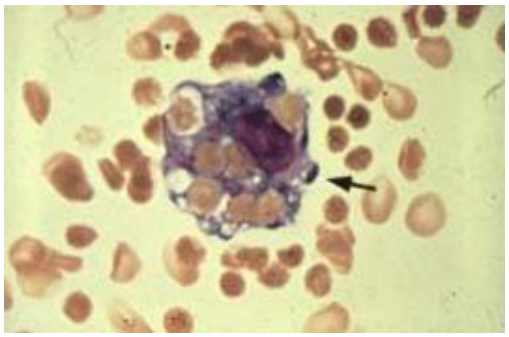

53. BM finding in a patient with a hemolytic anemia and positive direct Coombs test

The arrow points to a macrophage that has phagocytosed a number of RBCs (erythrophagocytosis) that are coated by IgG and C3 for which the macrophages have receptors. In the direct Coombs test, rabbit anti-human IgG and C3 antibodies crosslink RBCs coated by IgG and C3 causing them to visibly clump under the microscope. Extravascular hemolysis is the most common mechanism of RBC destruction in autoimmune hemolytic anemias. The end-product of the RBC destruction is unconjugated bilirubin. The iron and amino acids are recycled. **(Hem061)**

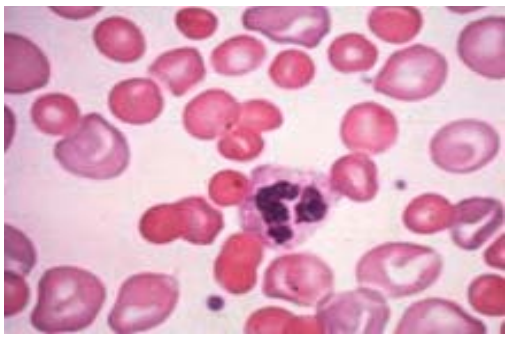

54. PB in a patient with SLE and a normocytic anemia with an elevated corrected reticulocyte count

What is the most likely diagnosis? Note the spherocytes and shift cells (marrow reticulocytes) in the smear and the segmented neutrophil. The patient has an autoimmune hemolytic anemia with a brisk erythropoiesis in the BM causing the release of shift cells. Spherocytes are noted in autoimmune hemolytic anemias, since macrophages in the spleen may only take part of the RBC membrane in an attempt at phagocytosis, hence causing the cell to lose its biconcave configuration. A direct Coombs test was positive in this patient. **(Hem062)**

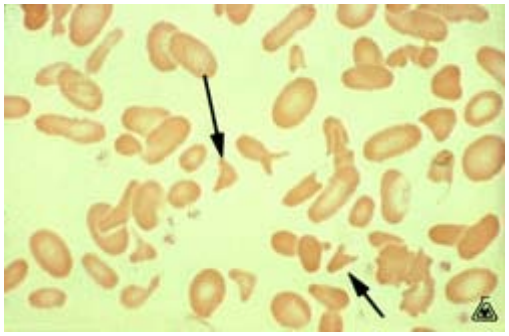

55. PB in a patient with severe calcific aortic stenosis and a mild normocytic anemia with an increased corrected reticulocyte count. What is the most likely diagnosis?

Note the increased number of schistocytes that have traumatized by the calcified valve. This is a microangiopathic anemia. Haptoglobin levels would be low and hemosiderin present in the urine sediment. Iron deficiency and thrombocytosis commonly occur in chronic cases. **(Hem064)**

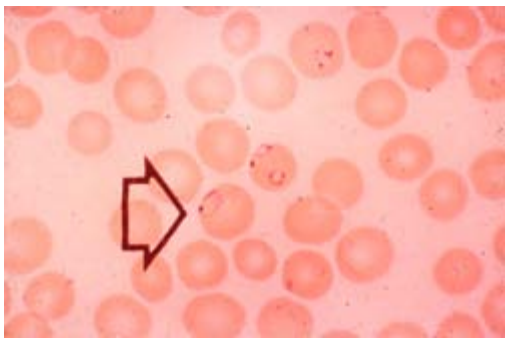

56. Peripheral blood from a missionary with spiking fever: What is the most likely diagnosis?

The patient has falciparum malaria. Note the ring forms in many of the RBCs. Some are multiply infected, which is a characteristic of falciparum malaria. Only ring forms and gametocytes are present in the peripheral blood in this type of malaria. Fever corresponds with rupture of

the RBCs (intravascular hemolysis). **(Hem232)**

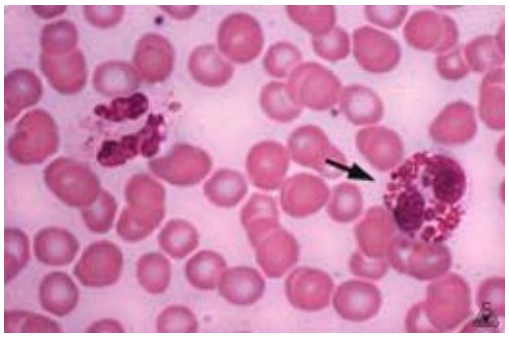

57. Peripheral smear from a 3 year old boy with recurrent infections
Arrow points to neutrophil with giant lysosomes of Chediak Higashi syndrome. AR disease with a membrane defect in transferring lysosomal enzymes into phagocytic vacuoles. Since the lysosomes have never been emptied, they are markedly enlarged. Patients also have severe neutropenia. **(Hem065)**

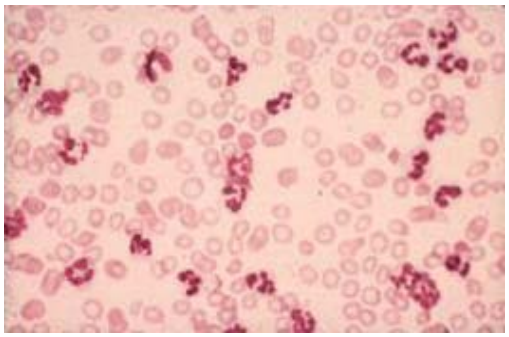

58. PB finding in a 5 year old child with *Streptococcus pneumoniae* pneumonia and a WBC count of 55,000 cells/m L. The WBCs are predominantly segmented neutrophils and a few band neutrophils. Since the count is >50,000 cells/m L, this would qualify as a leukemoid reaction secondary to the underlying bacterial pneumonia. A leukocyte alkaline phosphatase score (LAP is a marker of mature neutrophils) would be elevated. **(Hem066)**

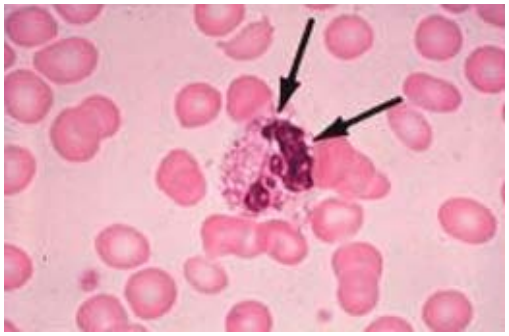

59. PB finding in a child with cystic fibrosis who has fever, productive cough and a left shifted smear
The cell is a neutrophil demonstrating toxic granulation (increased number of nonspecific, azurophilic granules containing myeloperoxidase), phagolysosomes (arrows pointing to vacuoles in the cytoplasm) indicating that phagocytosis has occurred. The patient most likely has a bacterial pneumonia, which is responsible for this type of neutrophil response. **(Hem067)**

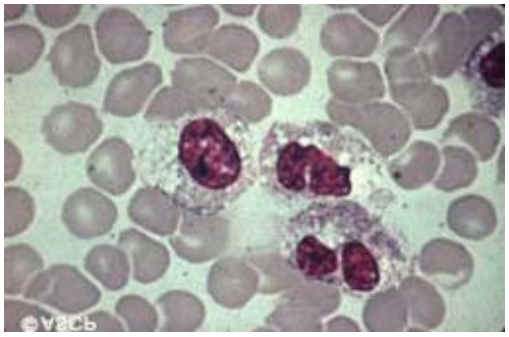

60. Peripheral smear from a 15 year old boy with fever, RLQ pain, and rebound tenderness
Segmented neutrophil, band, and metamyelocyte are present. There is toxic granulation and increased vacuoles (phagolysosomes). This is a left shifted smear and the history suggests acute appendicitis. **(Hem068)**

Previous | Next
Return to Top | Return to Image Index

Pathology I Images

Hematology

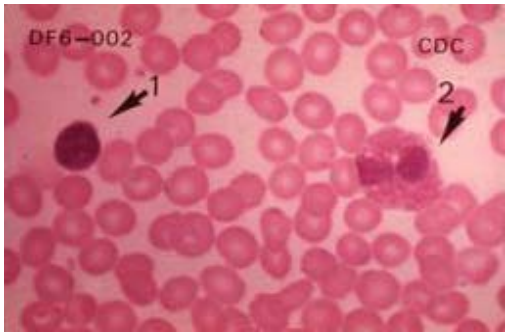

61. Peripheral smear normal patient
Cell #1 is a mature lymphocyte and cell #2 an eosinophil. Note how the red granules do not cover the nucleus and match the color of the RBCs. **(Hem069)**

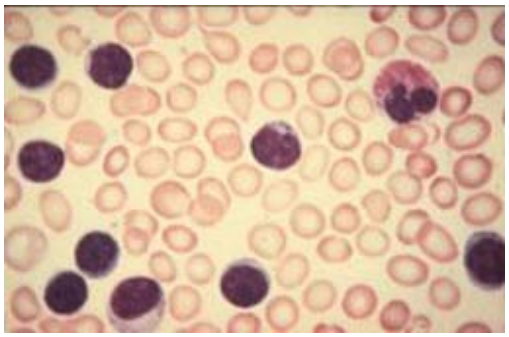

62. PB finding in a child with fever and severe cough characterized by paroxysms of coughing followed by an inspiratory whoop
The WBC count is 60,000 cells/m L. All of the cells, except for the eosinophil, are mature lymphocytes, hence the smear is characterized as an absolute lymphocytosis. Since the count is >50,000 cells/m L, it qualifies as a leukemoid reaction, which is commonly encountered in whooping cough (*Bordetella pertussis*). Note that the lymphocytes are mature and have no atypical features. **(Hem070)**

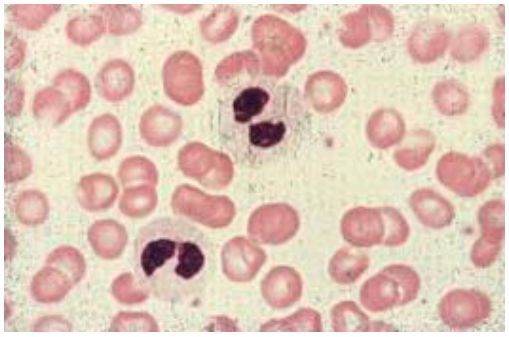

63. Asymptomatic 25 year old man
Note the hyperchromatic nuclear chromatin and the bilobed nucleus. This patient has Pelger-Huï¿½t syndrome, an AD disease with no clinical significance. The cells function normally. Pseudo-Pelger-Huet cells are noted in myeloproliferative diseases (e.g., chronic myelogenous leukemia). **(Hem071)**

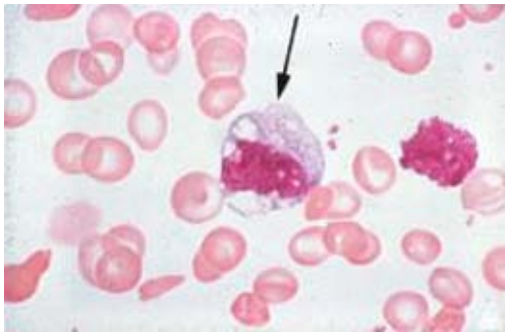

64. Peripheral smear from a 65 year old man with colon cancer metastatic to the liver
The cell in the slide accounted for 15% of the WBC count. The cell in question is a monocyte with linear appearing chromatin and a slate gray cytoplasm with vacuoles. Monocytosis is commonly present in malignancy and chronic inflammation. **(Hem072)**

65. PB finding in a 3 month old infant with fever and wheezing
The cell is a mature lymphocyte in a patient with a bronchiolitis secondary to

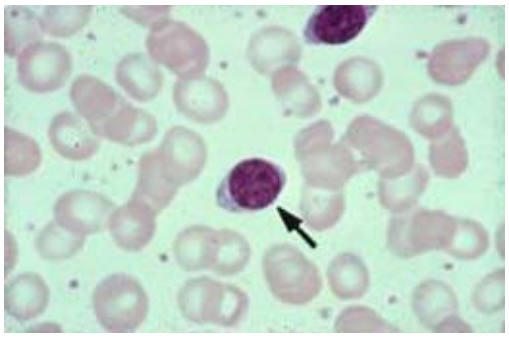

the respiratory syncytial virus. Lymphocytosis is common in viral infections. **(Hem073)**

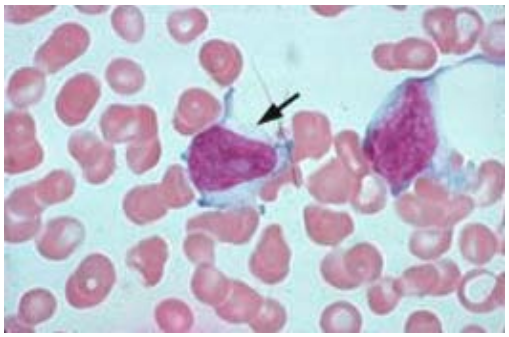

66. Peripheral smear from a 20 year old college student with malaise, exudative tonsillitis, cervical lymphadenitis, and hepatosplenomegaly
Note the large lymphocyte with activated nuclear features and abundant blue cytoplasm. These are atypical lymphocytes (antigenically stimulated lymphocytes) in a patient with EBV induced infectious mononucleosis. The lymphocytes are activated T cells responding to EBV infecting B cells after attaching to CD21 receptors on their surface. **(Hem074)**

67. Mouth of a 25 year old woman with generalized fatigue, hepatosplenomegaly, cervical lymph-adenopathy and atypical lymphocytosis
Palatal petechiae are commonly seen in patients with infectious mononucleosis. However, they are not pathognomonic of the disease. **(Hem075)**

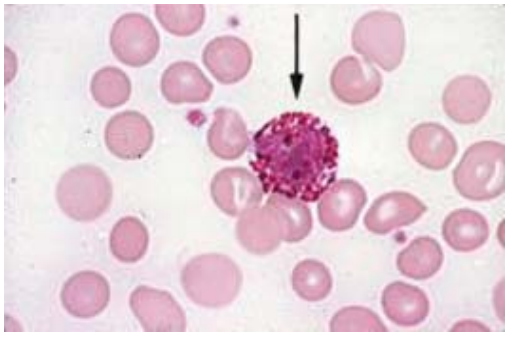

68. PB from a 60 year old man with splenomegaly
The cell depicted in the slide accounted for 8% of the WBC differential count. The cell in question is a basophil with dark purple granules covering the nucleus. Basophilia is a hallmark for myeloproliferative diseases such as PRV, CML, agnogenic myeloid metaplasia, and essential thrombocythemia. With the presence of splenomegaly, a myeloproliferative disease is likely in this patient. **(Hem076)**

69. 55 year old man with flushing of the face, headaches, splenomegaly, and a Hb of 19 gm/dL
The patient has a plethoric face and polycythemia with splenomegaly, hence polycythemia rubra vera is the most likely diagnosis. Plethora is due to the release of histamine from the increased numbers of

mast cells/basophils. **(Hem077)**

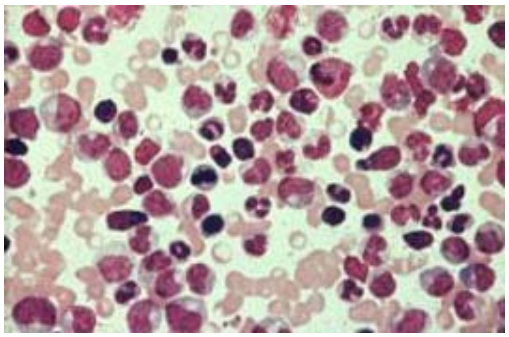

70. 45 year old man with anemia, 110,000 WBC count, thrombocytopenia, hepatosplenomegaly
Note the mixture of mature and immature WBCs. Cells with round nuclei are myeloblasts, progranulocytes, or myelocytes. Metamyelocytes (slight indentation of nucleus), band neutrophils, and segmented neutrophils also present. Leukocyte alkaline phosphatase score was zero and the Philadelphia chromosome positive indicating chronic myelogenous leukemia. **(Hem078)**

Previous | **Next**
Return to Top | **Return to Image Index**

Pathology I Images

Hematology

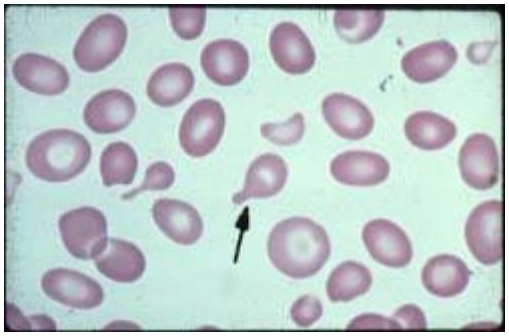

71. PB finding in a 60 year old woman with massive splenomegaly and a dry tap on attempted bone marrow aspiration
The RBC is a tear drop cell, which is a characteristic finding of agnogenic myeloid metaplasia, a myeloproliferative disease. The disease begins in the bone marrow and shifts to the spleen where extramedullary hematopoiesis takes over the bone marrow functions. Megakaryocytes in the bone marrow stimulate fibrogenesis, which traps erythroid islands and damages RBCs as they try to enter the sinusoids. Tear drop cells are also noted in the thalassemias and megaloblastic anemias due to folate and B12 deficiency. **(Hem079)**

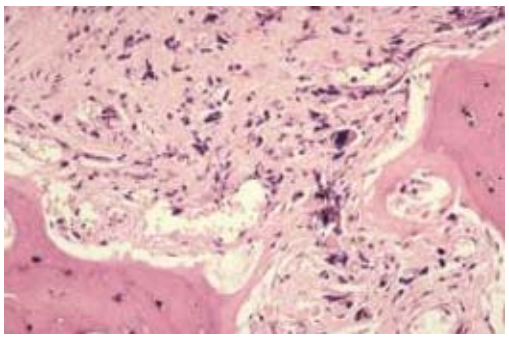

72. Bone marrow biopsy from a 60 year old patient who has massive splenomegaly and a dry bone marrow aspirate
Note that the marrow is replaced by fibrous tissue. The large cells represent benign megakaryocytes, which secreted platelet derived growth factor, an agent that stimulates reactive fibrosis in the marrow. Reactive marrow fibrosis may also occur with metastatic disease and radiation. **(Hem080)**

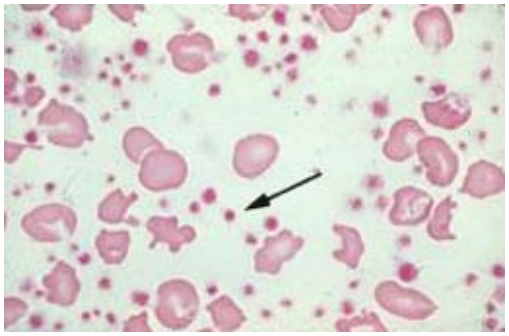

73. PB findings in a 65 year old woman with GI bleeding, hepato-splenomegaly, mild neutrophilic leukocytosis, and a platelet count over 1,000,000 cells/m L
The patient has essential thrombocythemia, a myeloproliferative disease with excessive production of platelets (>600,000 cells/m L). Bleeding is more characteristic than thrombosis, since the platelets are defective and do not aggregate. A bone marrow would reveal large, dysplastic appearing megakaryocytes. This is the least common of the myeloproliferative diseases. **(Hem082)**

74. BM findings with Prussian blue stain from a 79 year old man with a refractory macrocytic anemia, pancytopenia, and dimorphic RBC cell

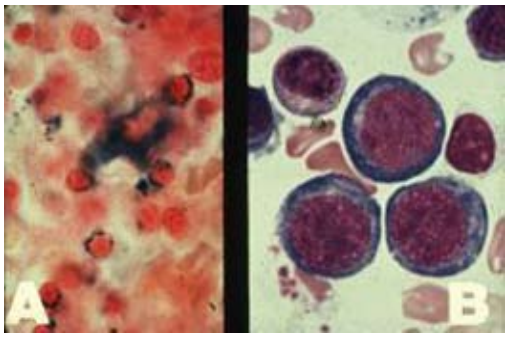

populations (small and large)
The patient has myelodysplastic syndrome (MDS) with megaloblastoid RBCs and ringed sideroblasts (defect in heme synthesis). These patients frequently have chromosome defects and commonly progress into acute leukemia. **(Hem083)**

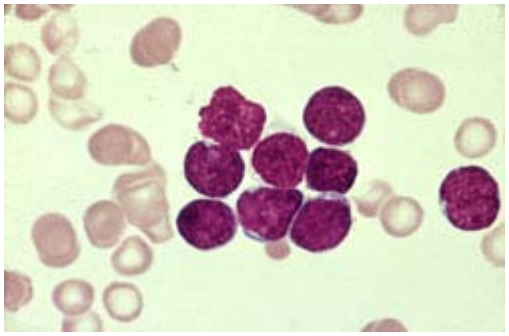

75. PB finding in a 3 year old child with fever, bone pain, anemia, thrombocytopenia, elevated WBC count, hepatosplenomegaly, and generalized lymphadenopathy
The cells are all lymphoblasts, many of which contain nucleoli. The patient has acute lymphoblastic leukemia (ALL), which is not only the most common cancer in children, but also the most common leukemia up to 15 years of age. The majority are common ALL antigen positive CD10 B cell leukemias. The type of ALL is the most important prognostic factor. **(Hem084)**

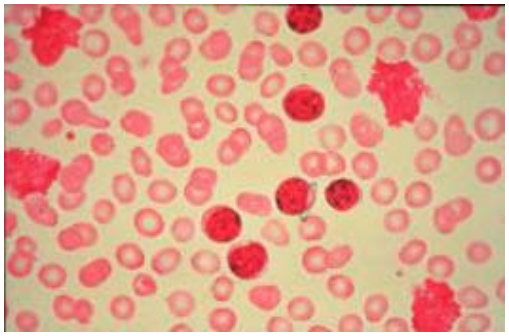

76. Peripheral smear from a 70 year old man with generalized non-tender lymphadenopathy, hepatospleno-megaly, normocytic anemia, thrombocytopenia, and a WBC count of 35,000 cells/mL
All of the cells are lymphocytes with hyperchromatic nuclei. Note the smudge cells as well (fragile lymphocytes crushed in the smear preparation). The patient has chronic lymphocytic leukemia, the most common overall leukemia, and the most common one in patients over 60 years old. The majority are B cell malignancies. **(Hem085)**

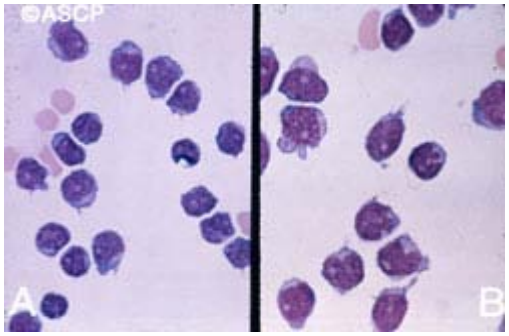

77. PB from a 65 year old man with hepatosplenomegaly, normocytic anemia, thrombocytopenia, and these abnormal cells in the smear
The patient has hairy cell leukemia. Note the hairy cytoplasmic projections. The tartrate resistant acid phosphatase stain is positive in these neoplastic B cells. The spleen is the reservoir for the neoplastic cells, hence splenectomy is usually performed as part of the treatment. Lymphadenopathy is characteristically absent, an unusual feature for leukemia. Splenomegaly is invariably present. Unlike most leukemias which infiltrate both the red and white pulp, HCL only infiltrates

the red pulp. **(Hem086)**

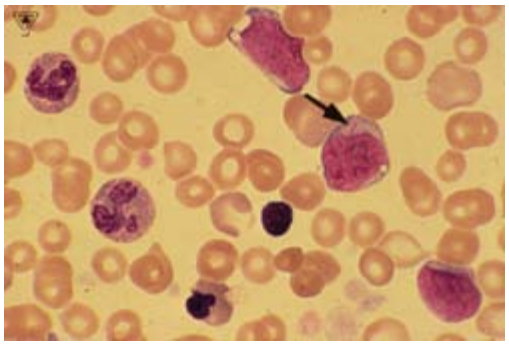

78. Peripheral blood in a 25 year old man with normocytic anemia, thrombocytopenia, WBC count of 20,000 cells/m L, hepatosplenomegaly and generalized lymphadenopathy
The cell with the arrow is a myeloblast with an Auer rod (red splinter) in the cytoplasm. Acute myelogenous leukemia is the most common leukemia from 15-39 years of age. **(Hem247)**

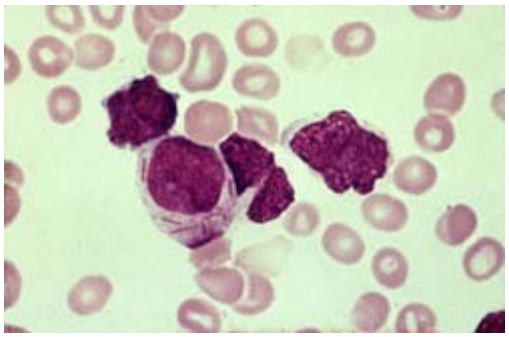

79. PB from a 32 year old male with anemia, thrombocytopenia, and an elevated WBC count containing cells similar to those noted in the slide
The patient has acute myelogenous leukemia. Note the myeloblast with the Auer rods. **(Hem088)**

80. 22 year old man with acute leukemia
The patient has gum infiltration by leukemic cells. This is characteristic of acute monocytic leukemias. **(Hem089)**

Previous | Next
Return to Top | Return to Image Index

Pathology I Images

Hematology

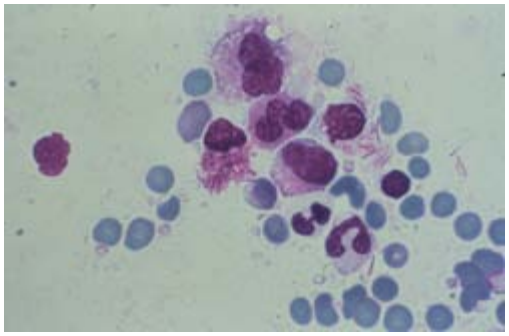

81. Peripheral blood from a 25 year old man with disseminated intravascular coagulation: What is the treatment for this type of leukemia?
The patient has acute progranulocytic leukemia (M3), which almost invariably presents with DIC. These patients have a t(15;17) translocation and can be treated with retinoic acid (vitamin A). Retinoic acid increases maturation of the blasts. **(Hem250)**

82. 12 year old boy with epistaxis
Patient with petechial lesions on skin. These do not blanch with pressure. Platelet count was 5000 cells/m L consistent with idiopathic thrombocytopenic purpura, an autoimmune disorder with IgG antibodies against a platelet antigen (type II hypersensitivity). **(Hem090)**

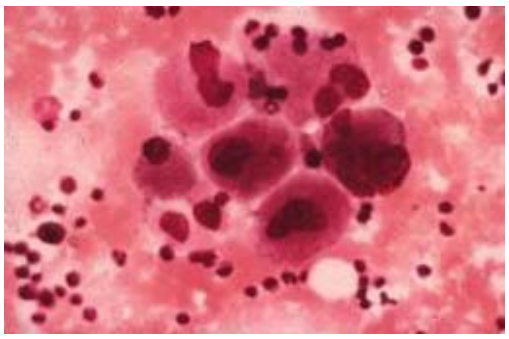

83. Bone marrow aspirate from a woman with SLE who has thrombocytopenia
The marrow exhibits clumps of megakaryocytes that are not budding off platelets from their cytoplasm. This is a characteristic feature of autoimmune thrombocytopenia and would also have been present in the previous patient as well. **(Hem091)**

84. Finger of a 23 year old man with severe iron deficiency and a positive stool guaiac
The patient has Osler-Weber-Rendu disease (hereditary telangiectasia). Note small vascular lesions on the pad of the finger. These are also located in the mouth and GI tract, hence predisposing to blood loss and iron deficiency. **(Hem092)**

85. Hands of a 70 year old woman with a normal platelet count and CBC. The patient has senile purpura with rupture of small vessels producing these ecchymotic areas in the subcutaneous tissue. Vascular instability is common in the elderly. These could also have occurred as a response to being over-anticoagulated with warfarin or

heparin. **(Hem093)**

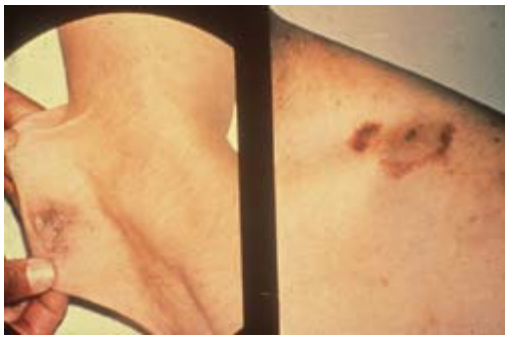

86. Patient with hyperextensible joints and skin: What is the defect in this patient?
The patient has Ehlers-Danlos syndrome, which is a group of diseases with various defects in collagen. Note the ecchymoses related to vessel instability. **(Hem273)**

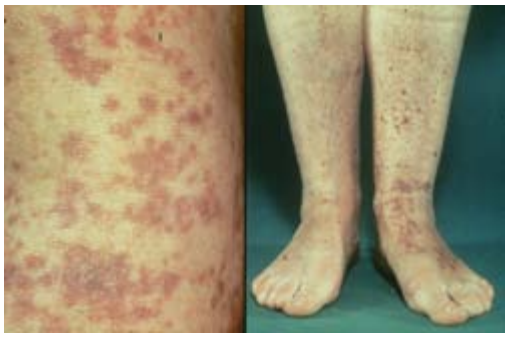

87. 15 yr old boy with palpable purpura, hematuria, and polyarthritis. What is the mechanism of the patient's vascular problem?
The patient has Henoch-Schönlein purpura, the MC vasculitis in children. It is a small vessel vasculitis due to IgA-anti-IgA immunocomplexes (type III hypersensitivity). **(Hem277)**

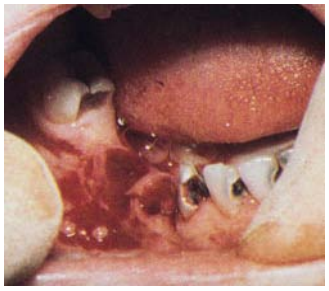

88. Tooth socket in a 22 year old with a recent extraction and problems with persistent bleeding
The bleeding time is normal and the aPTT prolonged. Persistent bleeding from a tooth extraction is characteristic of a coagulation disorder, in this case, hemophilia A. A temporary platelet plug is formed in the socket, however, a stable clot is not formed, hence late rebleeding is commonly observed. The single best question to ask a patient that will exclude any significant hemostasis abnormality is how well they did after a molar extraction. **(Hem094)**

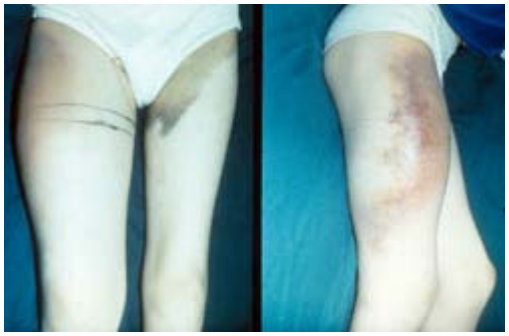

89. 18 year old boy with a prolonged aPTT. The patient has an intramuscular hematoma secondary to severe hemophilia A. Bleeding into closed spaces or fascial planes is a feature of a coagulation deficiency. **(Hem095)**

90. Cervical lymph node biopsy from a 25 year old man with painful cervical lymphadenopathy

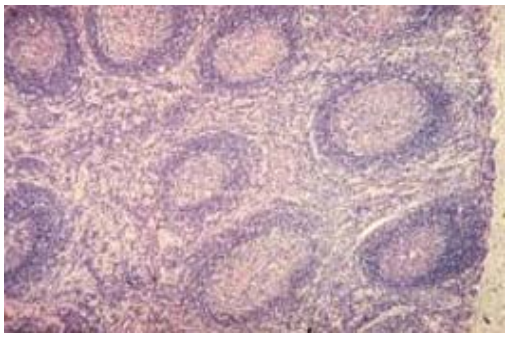

The node shows the classic features of reactive hyperplasia: sharply demarcated follicles (B cells) with a mantle of darkly staining B cells, and paracortex (T cells). Note the variety of cellular types in the node which distinguishes it from a malignant lymphoma. The follicles have been antigenically stimulated, hence the node becomes enlarged and painful. The cells in the center of the follicles are antigenically stimulated B cells in different stages of development: small cleaved large cleaved small non-cleaved large non-cleaved immunoblast plasma cell. **(Hem096)**

Previous | **Next**
Return to Top | **Return to Image Index**

Pathology I Images

Hematology

91. Child with ataxia telangiectasia:
This is an AR chromosome instability syndrome (increased susceptibility to chromosomal mutations involving defects in DNA repair enzymes) that predisposes to malignant lymphomas and leukemias. Note the vessel telangiectasias in the eye. Cerebellar ataxia, recurrent sinus infections, and B and T cell defects are present. **(Hem253)**

92. Child with Wiskott-Aldrich syndrome:
This is an SXR disease with a triad of eczema (evident in this child), thrombocytopenia, and recurrent sinopulmonary infections. They have both B and T cell defects and an increased incidence of leukemia and lymphomas. Rx: bone marrow transplant. **(Hem254)**

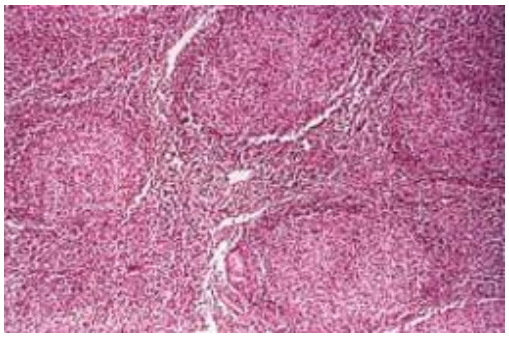

93. Lymph node biopsy from a 55 year old woman with non-tender cervical lymphadenopathy
The biopsy shows a monomorphic infiltrate of cells forming nodular areas. The normal sharply demarcated follicles (B cells) and the paracortex (T cells) have been replaced by these neoplastic cells. This is follicular B cell lymphoma, the most common non-Hodgkin's lymphoma in adults. It commonly involves the bone marrow and peripheral blood, but is considered a low grade malignancy. **(Hem097)**

94. Cross-section of trachea and arch

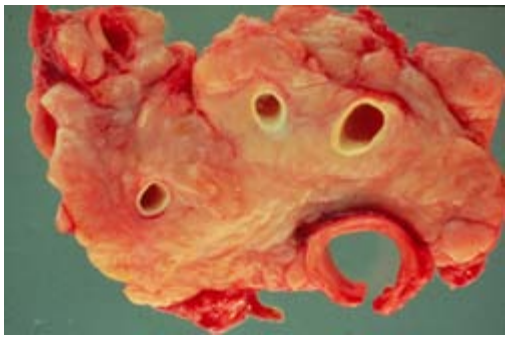

vessels in a patient with a malignant lymphoma:
Note the bulging, fish flesh appearance of the tumor. Note that the tumor cells cannot invade elastic tissue or cartilage. **(Hem256)**

95. African child with a jaw tumor: What is the etiologic agent?
The patient has the African variant of Burkitt's lymphoma, which has a high association with EBV. Patients also have a t(8;14) translocation of the c-myc oncogene, which is a nuclear transcriber. **(Hem259)**

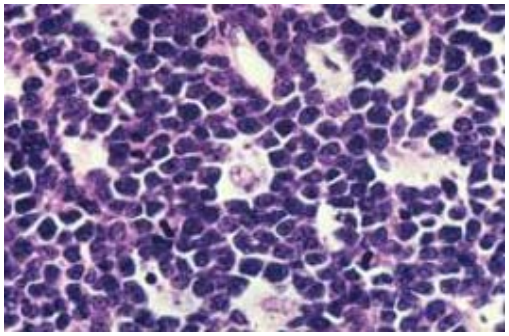

96. Lymph node biopsy of a para-aortic node from a 5 year old child
The patient has Burkitt's lymphoma, the most common lymphoma in children. Unlike the African variant, the American variant is more commonly located in the abdominal cavity. Note the characteristic "starry sky" appearance, where the dark of night are the small noncleaved malignant B cells and the stars are tingible macrophages with apoptotic remnants of phagocytosed B cells. It is a high grade lymphoma. There is an association with EBV and a t(8;14) translocation. **(Hem098)**

97. Patient with an abnormal infiltrate of cells in the skin. The patient has the nodular, ulcerated plaques of mycosis fungoides, a malignancy of CD_4 T helper cells
Skin infiltration by the malignant T cells results in these lesions. Collections of malignant cells in skin are called Pautrier's microabscesses. When the cells enter the blood stream, they are called Sezary cells and the disease changes its name to Sezary syndrome. **(Hem099)**

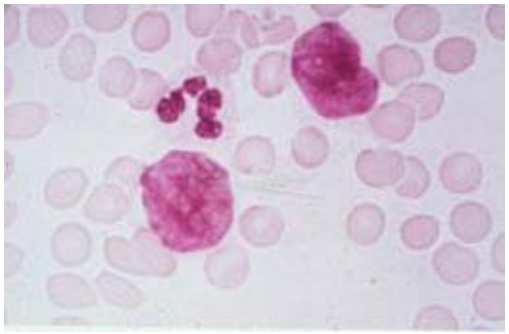

98. Abnormal cells in the blood of the above patient
The cells with the nuclear cleft are malignant CD_4 T helper cells, or Sezary cells. They stain positive for PAS (not demonstrated in this slide) and have PAS positive chunks of material located around the nucleus ("ring around the collar" analogous to ringed sideroblasts in sideroblastic anemias"). **(Hem100)**

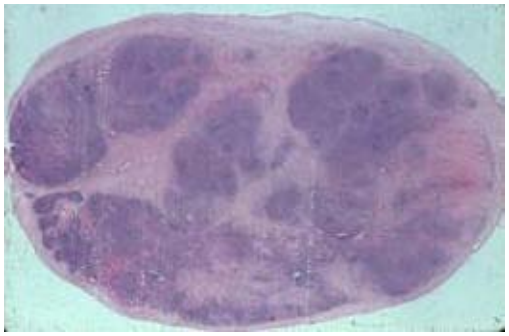

99. Lymph node in cross-section from a 32 year old female with nonpainful cervical lymphadenopathy and an anterior mediastinal mass
The lymph node shows the characteristic features of nodular sclerosing Hodgkin's lymphoma, the most common HL and the one most commonly seen in women. The fibrotic areas separate the lymphoid tissue into nodular appearing areas. These areas contain spaces (not easily visible on this slide) within which are lacunar cells, a variant of Reed-Sternberg cells. **(Hem101)**

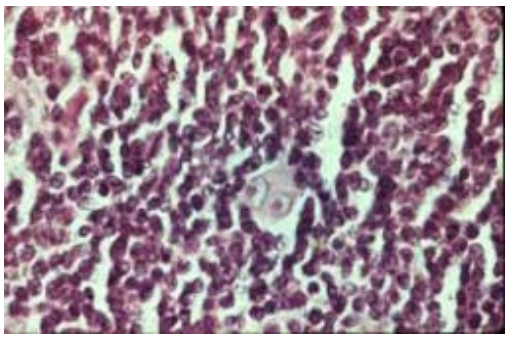

100. Cell found in the right supraclavicular lymph node of a 19 year old man
The cell is a Reed-Sternberg (RS) cell. The RS cell is a single large cell with two or more nuclei or nuclear lobes with a large inclusion body-like eosinophilic nucleolus surrounded by a halo of clear nucleoplasm (has an "owl eye" appearance). Mononuclear variants (single, round nucleus) of the RS cell are noted in the different subtypes. The **L and H variant**

("popcorn cell") is noted in the lymphocyte predominant HL, which frequently has a lymphocytic and histiocytic infiltrate, hence the term L and H cell. The **lacunar cell variant** is noted in nodular sclerosing HL and consists of a multilobulated nucleus surrounded by a clear space, which may represent artifactual distortion related to formalin fixation of the node. **Mononuclear variants** are noted in mixed cellularity HL which resemble RS cells but for the presence of a single nucleus with a prominent nucleolus. Unlike NHL, the lymphocytes in the lymph nodes involved with HL are not neoplastic, which has a binucleate cell with prominent red nucleoli surrounded by a clear space. **RS cells** are the neoplastic cell in HL. They are of B cell origin in some variants or T cell origin in other variants. It is essential for securing the initial diagnosis of HL in lymph nodes but is not pathognomonic of HL, since there are many look-alikes, e.g., immunoblasts in infectious mononucleosis. **(Hem102)**

Previous | **Next**

Return to Top | **Return to Image Index**

Pathology I Images

Hematology

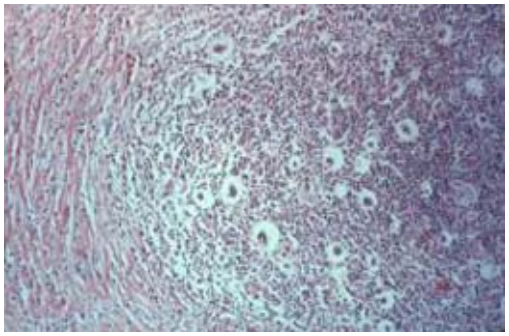

101. Lymph node (higher magnification) from a patient with nodular sclerosing HL
Note the spaces within which are multinucleated cells with small nucleoli (lacunar cells). This is characteristic of nodular sclerosing HL. **(Hem103)**

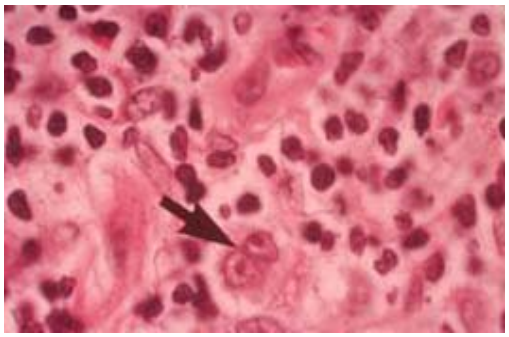

102. Lymph node biopsy in a 17 year old with painless cervical lymphadenopathy
A classic RS cell is present. The patient most likely has a lymphocyte predominant HL, where RS cells are very difficult to find, hence the better prognosis, since they are the neoplastic cell of HL. **(Hem104)**

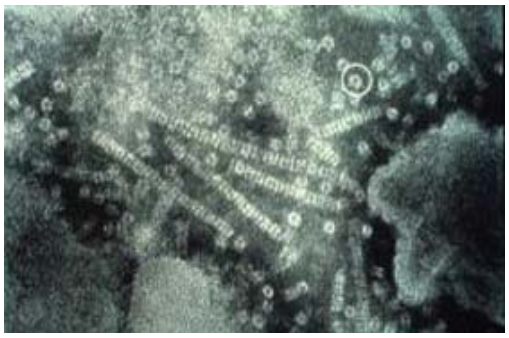

103. EM finding of interstitial tissue from a rectal biopsy in a patient with macroglossia, hepatosplenomegaly, and massive proteinuria
The EM shows the non-branching fibril with a hollow core of amyloid. The patient has secondary (reactive) amyloidosis, the amyloid, in this case, derived from serum associated amyloid (SAA) protein synthesized in the liver. Amyloid is Congo red positive, which fluoresces apple green (Granny Smith apple) under the polarizing microscope. **(Hem105)**

104. Patient with macroglossia, restrictive cardiomyopathy, and the nephrotic syndrome. What systemic disease is most likely present?
The patient has macroglossia secondary to secondary (reactive) amyloidosis. Chronic diseases are most often associated with this type of amyloidosis, which is due to conversion of serum associated amyloid into amyloid. **(Hem270)**

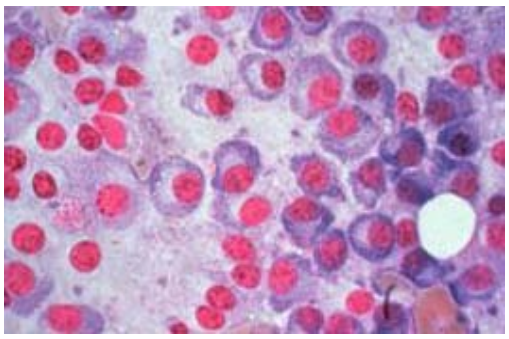

105. BM finding in a 70 year black woman with bone pain, anemia, rouleaux, and a pathologic fracture of the rib
The patient has multiple myeloma. Note the sheets of malignant plasma cells with eccentric nuclei, perinuclear clearing, and bright blue cytoplasm (increased RER with immunoglobulin synthesis). Light chains in the urine are called Bence Jones protein. The cells produce osteoclast activating factor (IL-1), which is responsible for the lytic areas in bone and hypercalcemia. Rouleaux occurs when immunoglobulins are increased. **(Hem106)**

106. Skull x-ray from the black woman in the above case
Note the lytic areas in the skull associated with the release of osteoclast activating factor from malignant plasma cells in multiple myeloma. **(Hem107)**

107. Serum immunoelectrophoresis in a patient with multiple myeloma. Which immunoglobulin and light chain are abnormal in this patient?
N refers to the normal control and P refers to the patient. There is an abnormal arc for IgG and k light chain. Light chains in the urine are called Bence Jones protein, which is toxic to the renal tubules and leads to renal failure. **(Hem269)**

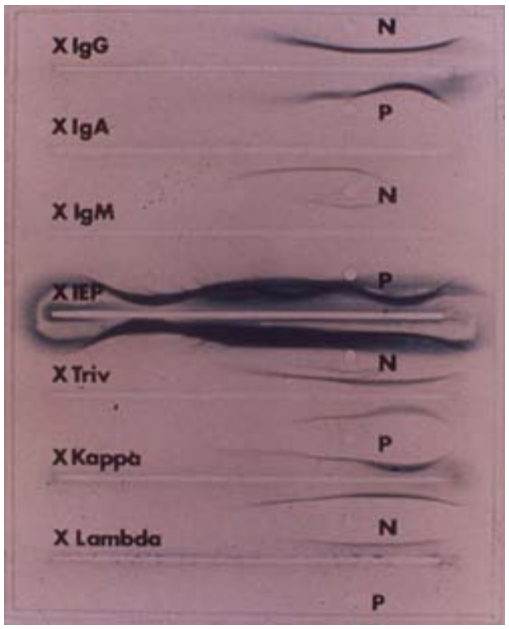

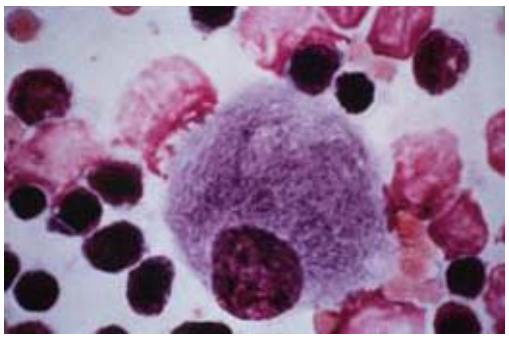

108. Bone marrow finding in an adult with massive splenomegaly and increased total acid phosphatase levels
The cell is a macrophage containing a fibrillary material. This is a cell in Gaucherâ€™s disease, which is an AR lysosomal storage disease with a deficiency of glucocerebrosidase and an accumulation of glucocerebroside. Infantile and adult types of the disease are recognized. The cells contain large amounts of acid phosphatase. **(Hem108)**

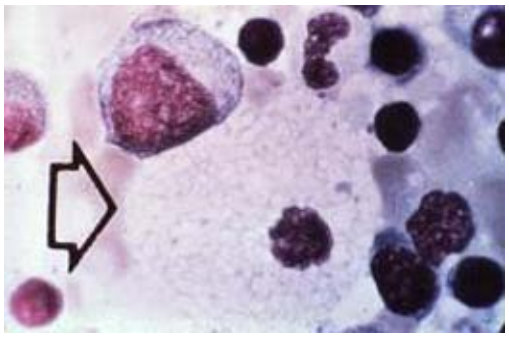

109. Bone marrow finding from an infant with severe mental retardation and hepatosplenomegaly
The foamy appearing cell with a small nucleus is a macrophage containing lysosomes filled with sphingolipid. The patient has Niemann Pick disease, an AR disease with an absence of lysosomal sphingomyelinase. **(Hem109)**

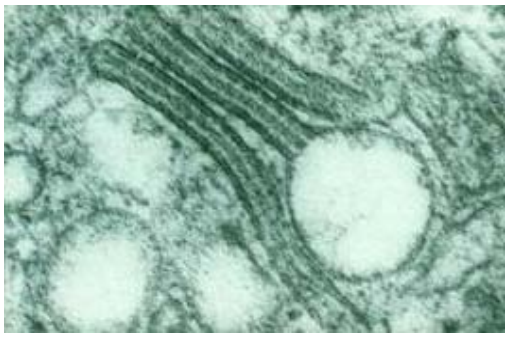

110. EM of a cell which was part of an infiltrate in the skin of a 3 year old child with an eczematous rash, hepatosplenomegaly, and generalized lymphadenopathy
The cells were CD1 positive. The finding in the cell is a Birbeck granule (looks like a tennis racket), which is a characteristic finding in Langerhanâ€™s cells, a true histiocyte. The patient has Letterer Siwe disease, which is part of the histiocytosis X complex of diseases. **(Hem110)**

111. Lymph node biopsy from the above patient. What are the pink staining cells called and where are they normally located?
The pink staining aggregates are malignant histiocytes, which are normally

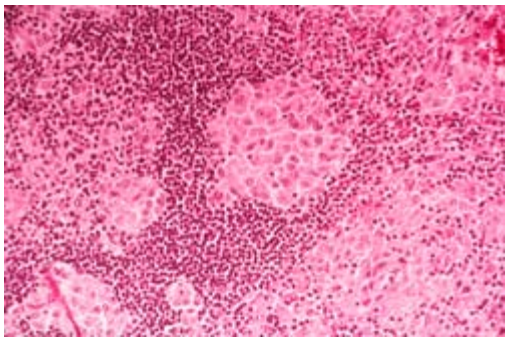

present in the sinuses of a lymph node. **(Hem265)**

112. Child with Rh hemolytic disease of the newborn: Why is the fetus edematous?
The child has hydrops fetalis. Patients with Rh hemolytic disease have severe anemias, which lead to high output failure and both left and right heart failure, the latter responsible for peripheral edema and ascites. The liver in this fetus had massive hepatomegaly secondary to extramedullary hematopoiesis. **(Hem282)**

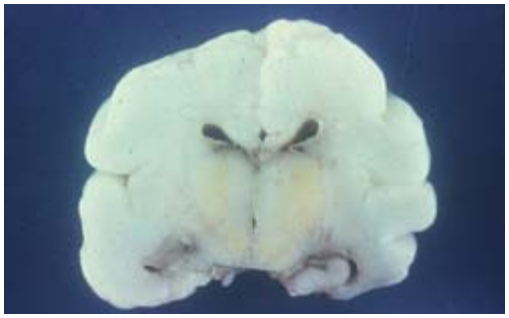

113. Brain of the above fetus. What is causing the yellowish discoloration?
The yellow pigment is unconjugated, lipid soluble bilirubin derived from macrophage destruction of the Rh-sensitized fetal RBCs. The condition is called kernicterus. **(Hem284)**

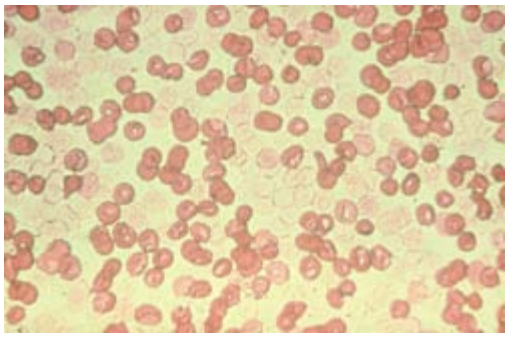

114. Kleihauer-Betke test in maternal blood post-delivery. The mother is O negative and the baby is O positive. Who do the normal colored RBCs belong to and what should the mother be given to prevent sensitization?
The normal staining cells contain Hgb F and represent fetal RBCs, while the pale staining cells contain Hgb A from the mother. She should be give Rh immune globulin (anti-D) to prevent sensitization to the D antigen. **(Hem285)**

Previous | Next
Return to Top | Return to Image Index

Pathology I Images

Syllabus | Lecture Schedule | Images - Pathology I | Images - Pathology II

Cardiovascular

1 | 2 | 3 | 4 | 5 | 6 | 7 | 8

It is against copyright laws to make *electronic or printed* copies of these slides!!

1. Test tube: turbid specimen
When a tube of turbid plasma is left overnight in a refrigerator at $4^{O}C$, chylomicrons float on top of the plasma (form a supranate), since they have very little protein, while VLDL produces an infranate, since it contains more protein and is more dense than chylomicrons. This tube has both a supranate and an infranate (pinkish staining) indicating the presence of both chylomicrons and VLDL. This is type V hyperlipoproteinemia, which is commonly seen in diabetic ketoacidosis. **(CV001)**

2. Test tubes
The tube on your left is clear, however the LDL fraction is markedly increased. LDL contains CH, which does not produce turbidity. The patient has a type II hyperlipoproteinemia. The tube on the right has a supranate (arrow) and clear infranate indicating the presence of chylomicrons. The most common cause of this is



someone who did not fast and had a breakfast full of saturated fats. If this was a hyperlipoproteinemia, it would be a type I hyperlipoproteinemia. **(CV002)**

3. Patient: Achilles tendon xanthoma
This type of lipid deposit is pathognomonic for familial hypercholesterolemia, which is an AD disease with absence of LDL receptors. **(CV003)**

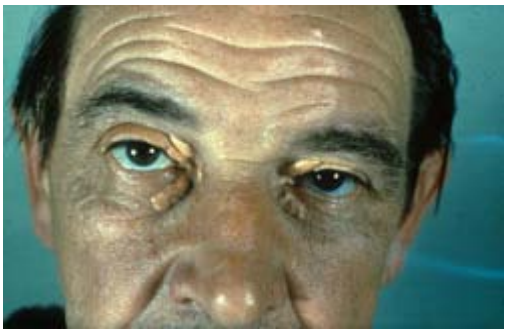

4. Patient with xanthelasmas
Note the yellow, plaque-like lesions on the upper and lower eyelids in both eyes. These lesions are associated with hypercholesterolemia - e.g. familial hypercholesterolemia, obstructive jaundice, or hypothyroidism. **(CV204)**

5. Vessel: hyaline arteriolosclerosis
Arteriosclerosis (hardening of the arteries) involves both small and large vessels. Hyaline arteriolosclerosis is a small vessel arteriosclerosis that is commonly found in diabetics and hypertensives. **(CV004)**

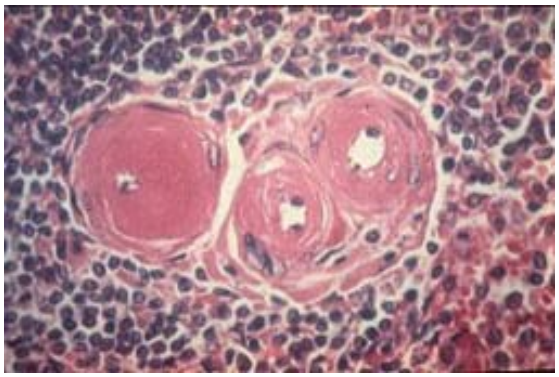

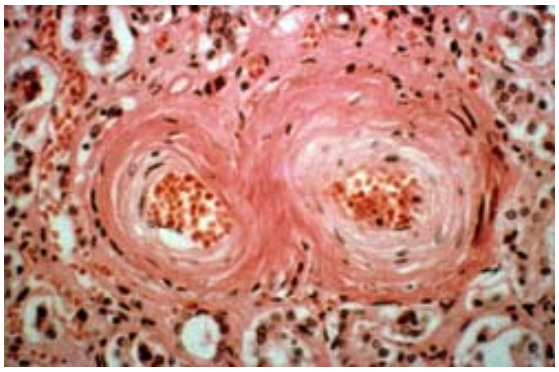

6. Vessel: hyperplastic arteriolosclerosis: This is the other type of small vessel arteriosclerosis. It is predominantly seen in malignant hypertension and renal disease associated with polyarteritis nodosa and progressive systemic sclerosis. It is also characteristic of the arterioles in the spleen in patients with SLE. Note the "onion skin" appearance of the vessels. This is secondary to hyperplasia of the smooth muscle in the wall of the vessels. **(CV005)**

7. Aorta: complicated atheromatous plaques
Note the raised yellow plaques and the fissures in between the plaques. Dystrophic calcification is likely present as well. **(CV205)**

8. Aorta: aorta with complicated atheromatous plaques
Note the fissured-appearing endothelial surface and raised plaque-like structures from the surface. Red clot material is adherent to the plaques in multiple areas. These clots consist of platelets held together by fibrin strands. Aspirin would have prevented these clots from forming. The blotchy white areas represent dystrophic calcification. This is an example of advanced atherosclerosis. It is likely that this patient had an increase in LDL. **(CV006)**

9. Patient: dry gangrene of the foot in a diabetic
Note the blackened big toe and little toe. Ulcers are present on the

undersurface of the big toe and the metatarsophalangeal joint. These are called pressure ulcers and are primarily due to peripheral neuropathy and inability to feel any pain in areas of trauma. Ischemia and infection also play a role in their development. Coagulation necrosis is primarily operative in this patient. However, anaerobic infection commonly occurs leading to gas production, further ulceration of the foot, a malodorous exudate, and gas in the subcutaneous tissue. In this case, liquefactive necrosis would be the predominant type of infection, hence the term wet gangrene. **(CV007)**

10. Aorta: atherosclerotic abdominal aortic aneurysm

Note the fusiform dilatation of the aorta below the renal arteries. The lumen is filled with atheromatous debris. Abdominal aortic aneurysms are the most common overall aneurysm. Weakening of the wall by atherosclerosis occurs owing to no vasa vasorum below the renal artery orifices. **(CV008)**

Previous | Next

Return to Top | Return to Image Index

Pathology I Images

Cardiovascular

It is against copyright laws to make
electronic or printed copies of these slides!!

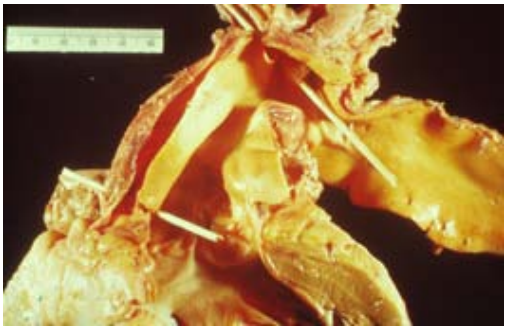		**11. Ascending aorta: dissecting aortic aneurysm** The tear in the aorta is at the top of the screen. A toothpick extends through the opening. Blood dissected proximally and emptied into the pericardial sac. The small toothpick is where the pericardial reflection is located. **(CV208)**
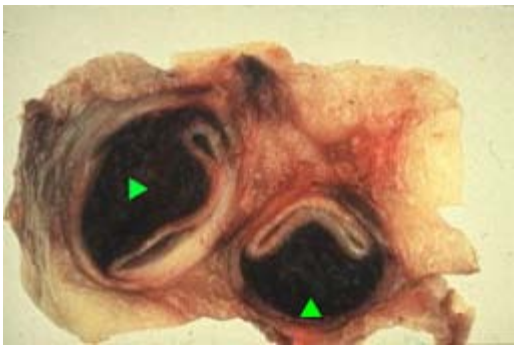		**12. Aortic arch vessels: dissecting aortic aneurysm** This is a cross-section of two of the elastic arteries coming off the arch of the aorta. Note how the lumens of both vessels are compressed by clotted blood within the wall of the vessels. This is a type A proximal dissection, where blood entered an intimal tear and extended proximally and up into the arch vessels. **(CV009)**
		13. Aorta: dissecting aortic aneurysm Note the two lumens in the aorta (double barreled aorta). The lumen on the top is a false lumen (clot has been removed) created by a more proximally located dissection. The false lumen represents the outer media and adventitia of the aorta. The lumen below the false lumen is the true lumen. This is a type B dissection. **(CV010)**
		14. Patient with Marfan's syndrome Marfan's syndrome is an AD disorder with a defect in the synthesis of fibrillin, hence elastic tissue is weakened. Note the longitudinal scar on the patient's chest, most likely representing repair of a previous dissection. The arm span is greater than the height of the patient and the

distance from the pelvic brim to the heels is greater than the distance from the brim to the top of the head. This describes eunuchoid proportions. **(CV210)**

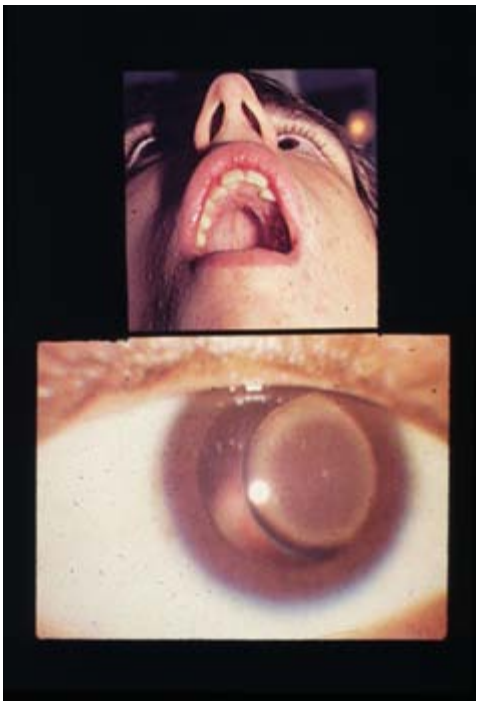

15. Patient with Marfan's syndrome: dislocated lens and high arched palate
Since the suspensory ligament holding the lens in place is composed of elastic tissue and the elastic tissue is weakened in Marfan's syndrome, the lens commonly dislocates. Note the high arched palate, which is also a characteristic feature. Arachnodactyly (not shown) is yet another physical finding. **(CV211)**

16. Arch of aorta: syphilitic aneurysm
Note the large depression just below the ruler which represents the aneurysm. The aortic valve ring is stretched, which leads to the murmur of aortic regurgitation. The pathogenesis relates to a vasculitis of the vasa vasorum (endarteritis obliterans), which decreases blood flow to the tissue within the aorta. The weakened tissue begins to outpouch in response to the increased stroke volume. **(CV207)**

17. Patient: varicose veins in the lower extremeties
Note the bulging and tortuous veins particularly in the left lower leg. There is some discoloration along the medial portion of the ankle, suggesting that the varicosities may be due to deep venous thrombosis and a backup of blood into the superficial saphenous system. **(CV212)**

18. Superficial saphenous veins: primary varicosities involving the superficial saphenous veins
Note the marked tortuosity and dilatation of the vessels. Usually there is absence of the sentinel valve in the femoral vein. **(CV014)**

19. Patient: superior vena caval syndrome:
This patient has a small cell cancer of the lung that has blocked off the superior vena cava. Note the congestion of the head and neck due to the backup of venous blood.

		(CV015)
		20. Patient: lymphedema of the arm post-modified radical mastectomy and radiation Note the marked enlargement of the extremity. Lymphedema is non-pitting. **(CV016)**
Previous	**|**	**Next**
Return to Top	**|**	**Return to Image Index**

Pathology I Images

Cardiovascular

It is against copyright laws to make
electronic or printed copies of these slides!!

		21. X-ray study: Takayasu's arteritis The arrows point to numerous areas of constriction in the subclavian arteries. The patient most likely had weak to absent pulses in both upper extremities. **(CV219)**
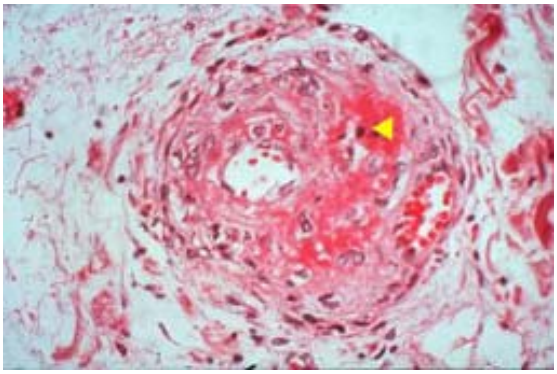		**22. Arteriole: fibrinoid necrosis (leukocytoclastic vasculitis):** Note the pink staining material (fibrinoid necrosis) in multifocal areas of the thickened wall of the venule. The material represents protein derived from the plasma that has deposited in the vessel wall owing to an increase in vessel permeability from the inflammatory process. It is called fibrinoid because it looks like fibrin in a clot but it is really protein. Small vessel vasculitis is usually due to immune complex (IC) disease (type III hypersensitivity). ICs are deposited in the vessel wall and then activate the complement system. C5a, a chemotactic factor, attracts neutrophils (only a few are visible at around 7 o clock). Neutrophils are responsible for the vessel injury. **(CV017)**
		23. Patient's lower legs: palpable purpura Note the red-blotchy areas scattered randomly over the skin surface. These lesions would be palpable, hence the term palpable purpura. Palpable purpura is due to a small vessel vasculitis with destruction of the vessel leading to an extravasation of blood into the subcutaneous tissue. The inflammation around the vessel (tumor of inflammation) makes the lesion palpable. This patient had Henoch-Schoenlein s purpura. **(CV018)**
		24. Patient: temporal arteritis Note the prominent temporal artery. A biopsy of the artery reveals multinucleated giant cells (granulomatous vasculitis, see arrow). **(CV019)**

25. Patient: thromboangiitis obliterans (Buerger s disease)
Note the blackened digits (coagulation necrosis). Autoamputation of the digits is likely to occur in this patient. **(CV020)**

26. Child: swelling of the hand in Kawasaki's disease
The patient had all the findings of this disease including chest pain (coronary artery vasculitis), erythema of mucous membranes and swelling of the dorsum of the hands. Desquamation of skin has not yet occurred. **(CV220)**

27. Patient: saddle nose of Wegener s granulomatosis
Note the flattened nose in this patient owing to destruction of the nasal septum by granulomatous inflammation. Congenital syphilis can also produce the saddle nose deformity. **(CV021)**

28. Patient: Raynaud s phenomenon
Note the white discoloration of some of the digits owing to spasm of the digital vessels. **(CV022)**

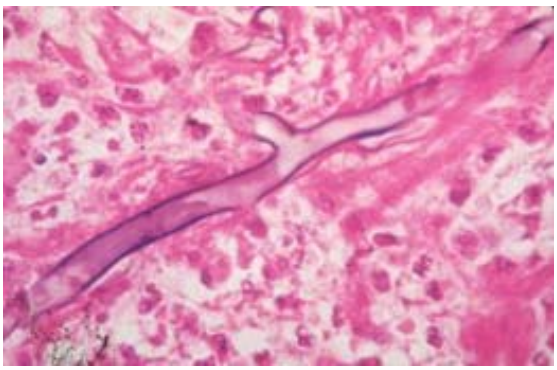

29. Vessel: Mucormycosis
Vasculitis may be secondary to fungi that invade vessel walls. Note the non-septate hyphae and wide-angled branches of Mucor. Candida and Aspergillus can also invade vessels. **(CV023)**

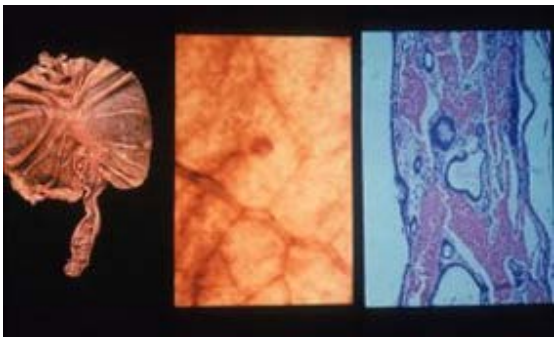

30. Stomach: hereditary telangiectasia (Osler-Weber-Rendu disease)
The stomach close-up reveals a vessel dilatation in the submucosa. A histologic section of the lesion exhibits dilated vascular channels. These lesions bleed causing the loss of blood in the stool. Similar lesions occur on the skin and mucous membranes of the mouth. **(CV024)**

Previous | Next

Return to Top | Return to Image Index

Pathology I Images

Cardiovascular

It is against copyright laws to make
electronic or printed copies of these slides!!

		31. Patient: spider angiomata Note the tentacle-like appearance of this lesion. Compression of the central portion of this lesion causes the tentacles to disappear, hence this lesion is an arteriovenous fistula. They are secondary to hyperestrinism (pregnancy, cirrhosis of the liver). **(CV025)**
		32. Child: capillary hemangioma on the nose These benign lesions that present at birth invariably disappear with increasing age in the patient. Most pediatricians recommend that they be left alone. **(CV216)**
		33. Patient: Kaposi's sarcoma: Note the raised, elongated red lesion on the neck. This patient is HIV positive and has Kaposi's sarcoma, which is due to HSV-8. Kaposiï¿½s sarcoma is an AIDS-defining lesion. **(CV027)**
		34. Renal angiogram: left renal artery stenosis Note the narrowing of the lumen of the proximal right renal artery. The narrowing is due to an atherosclerotic plaque. **(CV028)**

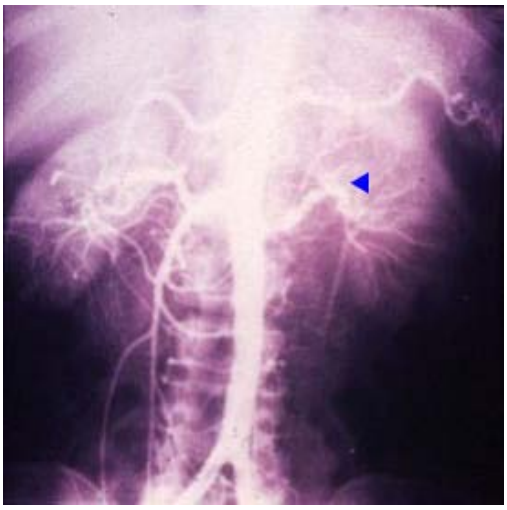

35. Renal angiogram: bilateral fibromuscular hyperplasia of the renal arteries
Note the "beaded" appearance in the right renal artery. This is due to fibromuscular hyperplasia in the wall of the renal artery (narrow lumen) alternating with a normal sized lumen. **(CV029)**

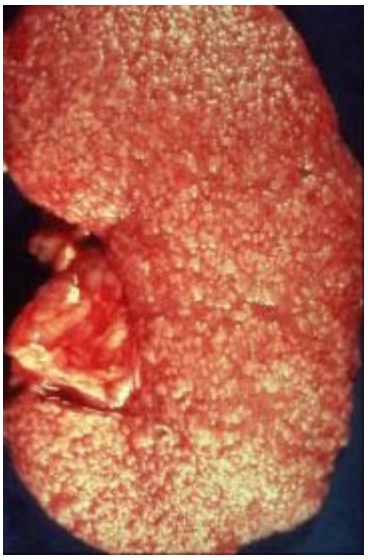

36. Kidney: benign nephrosclerosis (BNS)
Note the cobblestoned surface of this kidney in a patient with long-standing essential hypertension. BNS is the kidney of hypertension. The cortical effect is secondary to hyaline arteriolosclerosis (Slide 4) of the arterioles in the cortex with subsequent tubular atrophy and glomerular fibrosis. **(CV030)**

37. Retina: grade I hypertensive retinopathy
Note the narrow caliber of the retinal vessels. There is very mild AV nicking (slightly to your left of the red line going down the slide) where the large vessel at the top of

		the screen crosses a small venule. **(CV031)**
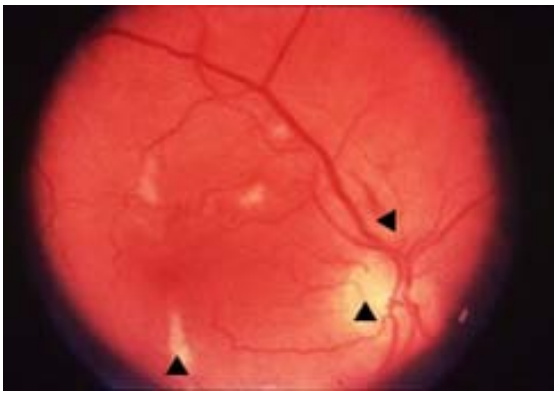		**38. Retina: grade III hypertensive retinopathy** Note the flame hemorrhage (ruptured microaneurysm) directly superior to the optic disc (pale area at 5 o'clock). The white lesions (arrow) are well demarcated and represent hard exudates (increased vessel permeability). There is no papilledema. **(CV032)**
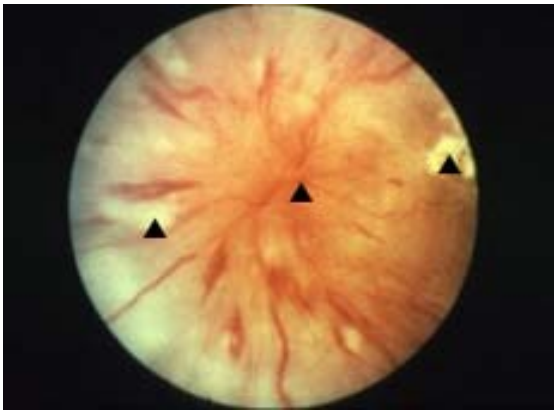		**39. Retina: grade IV hypertensive retinopathy** Note the obliteration of the optic disc (papilledema, arrow to center of the slide), flame hemorrhages, soft exudates (white exudates with a fuzzy margin like cotton [cotton wool exudates, arrow at 9 o'clock] representing microinfarctions, hard exudates (white patch that is well demarcated [arrow along the periphery of the slide at 3 o'clock] indicating increased vessel permeability. **(CV033)**
		40. Hearts: normal heart on the left; concentric hypertrophy on the right Recall that concentric hypertrophy is due to an increase in afterload (e.g., essential hypertension, aortic stenosis). **(CV034)**
Previous	|	Next
Return to Top	|	Return to Image Index

Pathology I Images

Cardiovascular

It is against copyright laws to make
electronic or printed copies of these slides!!

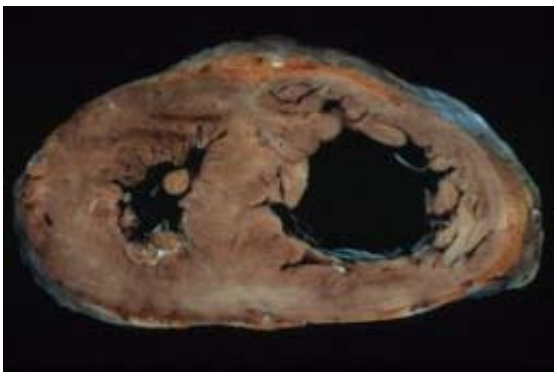		**41. Heart: right and left ventricular hypertrophy** The left ventricle is on your left and the right ventricle on your right. Note that both ventricles are thickened. One possible explanation for RV hypertrophy is pulmonary artery hypertension, which imposes an increased afterload against the RV. **(CV035)**
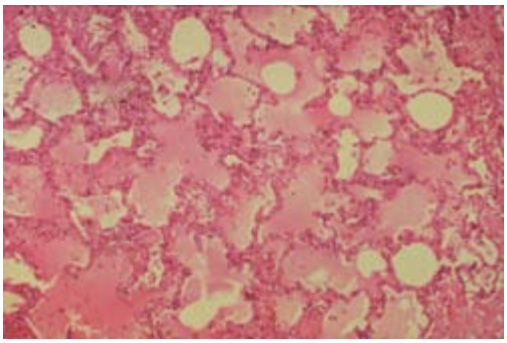		**42. Lungs: microscopic of pulmonary edema** Note the pink staining fluid (transudate) filling the alveoli. Pulmonary edema occurs in left heart failure. **(CV232)**
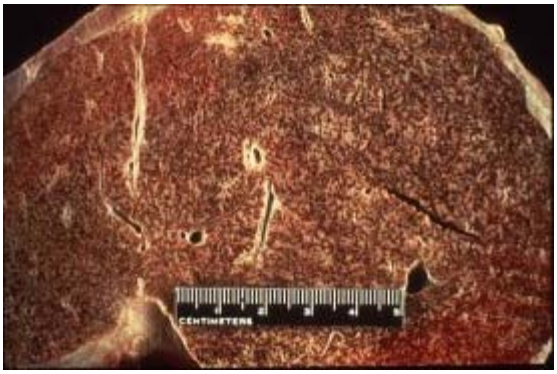		**43. Liver: congestive hepatomegaly ("nutmeg" liver)** Note the red dots scattered throughout the liver parenchyma. These represent blood backed up into the terminal hepatic venules (central vein) in a patient with right heart failure. Recall the terminal hepatic venules eventually coalesce to form the hepatic vein, which empties into the vena cava, which empties into the right heart. Hence an increase in systemic venous pressure transmits back into the liver. **(CV042)**
		44. Aorta: postductal coarctation of the aorta Note the area of constriction just distal to the ligamentum arteriosum (arrow) extending off the transected pulmonary artery. The proximal aorta is dilated and the posterior wall of the aorta hit by the jet-stream of blood going through the narrow opening is also aneurysmally dilated. You can trace a figure 3 lying on its side. **(CV043)**

45. Children: cyanotic congenital heart disease
Note the blue discoloration of the lips in these two children, both of which have tetralogy of Fallot. Refer to course notes for why these patients squat to relieve cyanosis. **(CV044)**

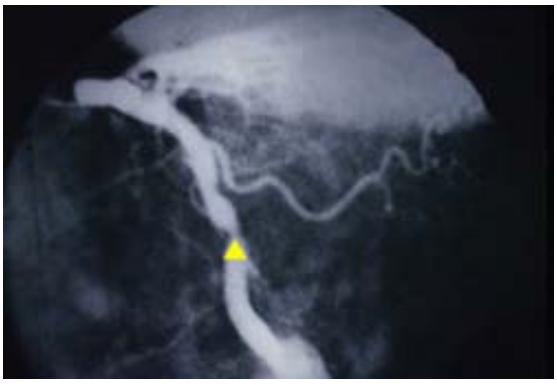

46. Right coronary artery angiogram
RCA stenosis secondary to atherosclerosis. Note the area of constriction (arrow) in the mid-portion of the coronary artery. **(CV045)**

47. Heart: heart with coronary artery bypasses using saphenous vein grafts
Note the 2 veins, one bypassing the LAD coronary artery (arrow) and the other the RCA. **(CV046)**

48. Coronary artery: coronary artery atherosclerosis

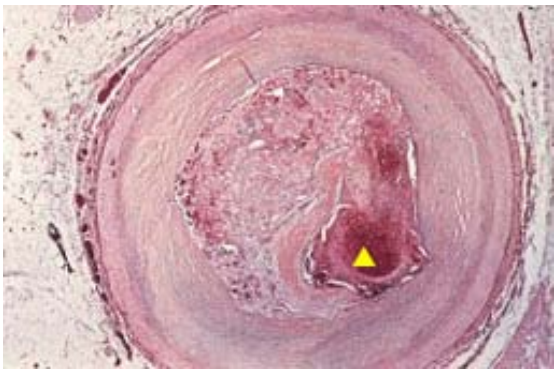		**and thrombus occluding the lumen** Note the red thrombus overlying an atheromatous plaque (arrow). The slit like spaces are where cholesterol used to be present. **(CV047)**
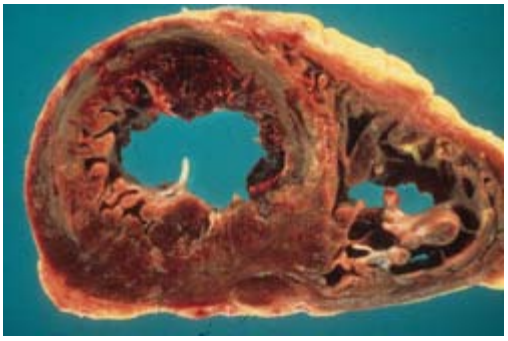		**49. Heart: anterior myocardial infarction** Note the pale infarct in the anterior portion of the left ventricle (on your left) with extension into the anterior 2/3rds of the interventricular septum. This is the distribution of the left anterior descending coronary artery. **(CV240)**
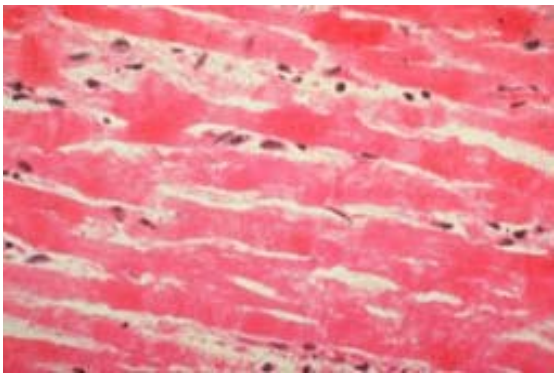		**50. Heart: coagulation necrosis of cardiac muscle in an AMI** Note the eosinophilic staining cells with no cross striations or nuclei. **(CV049)**
Previous	|	Next
Return to Top	|	Return to Image Index

Pathology I Images

Cardiovascular

It is against copyright laws to make
electronic or printed copies of these slides!!

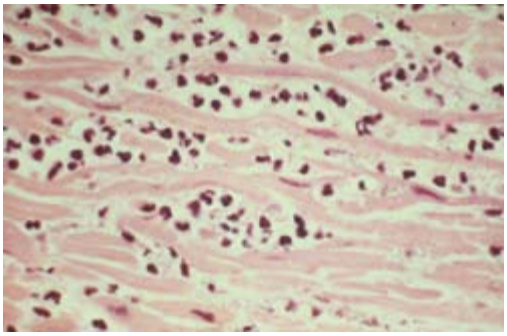		**51. Heart: microscopic section of a 3 day old acute myocardial infarction** Unlike the previous slide, which showed the early stages of coagulation necrosis, this slide depicts a heavy neutrophilic infiltrate with destruction of the cardiac fibers. The neutrophils came into the area of the infarct from the periphery, so this should not be confused with liquefactive necrosis. Macrophages will eventually replace the neutrophils and then collagen tissue will be deposited in the area of infarction. **(CV241)**
		52. Heart: cardiac tamponade secondary to rupture of the left ventricle in a patient with an AMI At the apex of the heart, there is a rupture site in the area of a transmural AMI. Blood fills the pericardial sac and encircles the heart. **(CV050)**
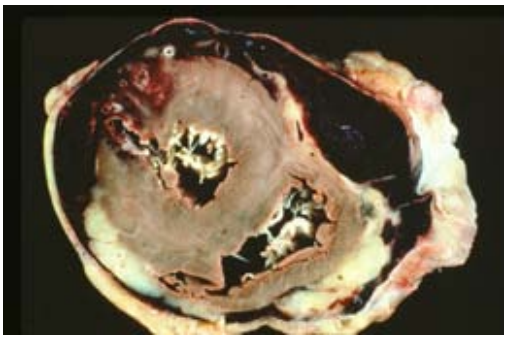		**53. Heart: rupture of the anterior wall of the left ventricle in a patient with an acute myocardial infarction** The rupture site is at 10 o'clock in the slide. The pericardial sac is filled with blood. **(CV255)**
		54. Heart: posteromedial papillary muscle rupture in a patient with a right coronary artery thrombosis A portion of papillary muscle hangs from the chordae tendineae of the mitral valve. A biopsy of the muscle shows coagulation necrosis. Recall that the right coronary artery supplies this muscle. **(CV254)**

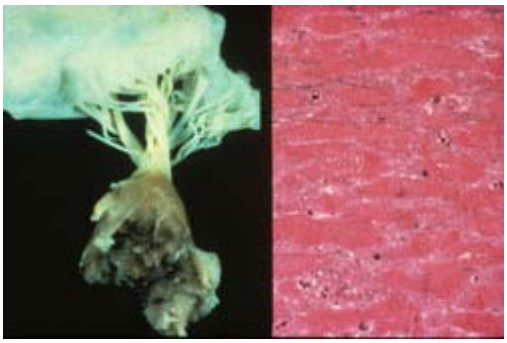

55. Heart: rupture of the interventricular septum in a patient with an acute myocardial infarction
A plastic stick marks the site of rupture in the IVS. Blood flows from left to right and volume overloads the right heart leading to right heart failure. The majority of IVS ruptures are due to thrombosis of the LAD coronary artery. **(CV262)**

56. Heart: fibrinous pericarditis post anterior acute myocardial infarction
Note the shaggy exudate along the surface of the visceral pericardium. This may be a complication of a transmural infarction during the first week or an autoimmune pericarditis 6-8 weeks later with autoantibodies directed against pericardial tissue. This is called Dressler's syndrome. **(CV070)**

57. Heart: mural thrombus on anterior wall of the ventricle
Note the large thrombus occupying most of the lumen of the left ventricle. A pale infarct overlies the thrombus. It

		is a mixed clot with the part attached to the endocardium representing a platelet thrombus and the part projecting into the lumen a "venous" type clot. **(CV261)**
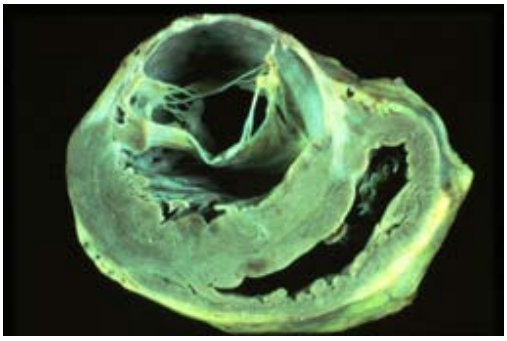		**58. Heart: ventricular aneurysm** Note the thin aneurysmal sac extending from the anterior portion of the left ventricle. Very little functional muscle tissue is left in the ventricle. These are late complications and present with a precordial bulge of the anterior chest with each systolic contraction. Rupture is uncommon, since the tissue is scar tissue. Most patients die of heart failure. **(CV245)**
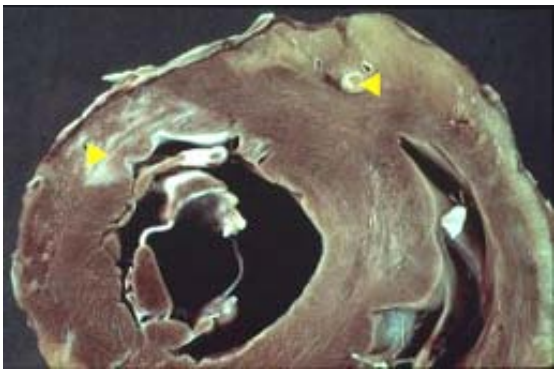		**59. Heart: scar tissue in an old anterior AMI** Note the completely calcified LAD coronary artery buried in the epicardial fat. The white patchy area in the anterior wall is fibrous tissue. **(CV053)**
		60. Heart: sterile vegetations on the mitral valve in a patient with acute rheumatic fever Note the red, wart-like vegetations along the line of closure of the valve (arrow). The vegetations are examples of fibrinoid necrosis. **(CV247)**
Previous	|	**Next**
Return to Top	|	**Return to Image Index**

Pathology I Images

Cardiovascular

It is against copyright laws to make
electronic or printed copies of these slides!!

		61. Heart: Aschoff nodule The Aschoff body is the pathognomonic lesion of rheumatic fever. It consists of a collection of Anichkov's myocytes (reactive histiocytes; in the center of the slide) and Aschoff multinucleated giant cells (a few multinucleated cells are visible) within an area of fibrinoid necrosis (pink staining material surrounding the histiocytes) located in the myocardium. **(CV055)**
		62. Patient: erythema marginatum in a patient with acute rheumatic fever This skin rash is one of the five Jone's criteria for diagnosing acute rheumatic fever. Note the erythematous circular lesions with central areas of pallor. **(CV248)**
		63. Heart: severe mitral stenosis with a dilated left atrium containing a thrombus Note the fixed, stenotic opening of the mitral valve (arrow in low center). The chordae are thickened owing to scar tissue formation. Stasis in the enlarged left atrium predisposes to clot formation (arrow in top center). LA dilatation predisposes to atrial fibrillation, which is

responsible for breaking the clot up into small emboli. **(CV056)**

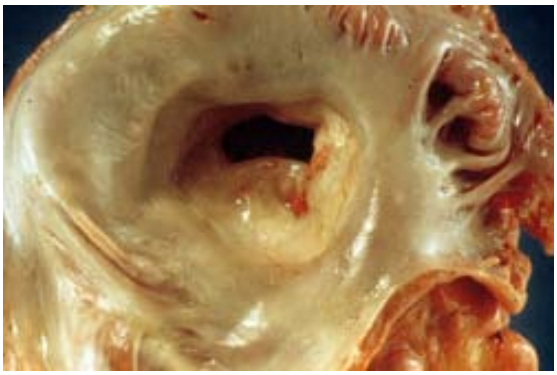

64. Heart: mitral stenosis
You are looking down from the enlarged left atrium into the orifice of the mitral valve. Note that it has a fish-mouth appearance. This patient probably had a significant component of mitral insufficiency as well as stenosis. **(CV057)**

65. Heart: mitral valve prolapse
Note the baggy-appearing mitral valve leaflets. When blood collects beneath these voluminous valves, it projects them into the left atrium like a parachute. When the chordae abruptly stop the valves from moving any further, a systolic click is heard followed by a murmur of mitral insufficiency. **(CV058)**

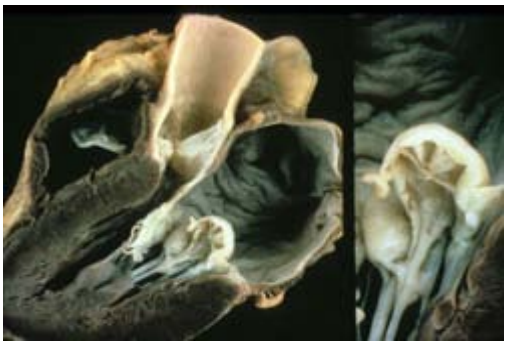

66. Heart: mitral valve prolapse
Note the parachute-like redundancy of the mitral valve and how it has prolapsed into the left atrium. A close-up of the valve shows that one of the chordae has ruptured causing the patient to develop acute mitral regurgitation, and, in this case, death. **(CV249)**

67. Aortic valve: bicuspid aortic valve with associated aortic stenosis

Note that there are only 2 cusps when there should be 3. The AV orifice is stenotic due to dystrophic calcification of the valve leaflets (knobby appearing material). **(CV060)**

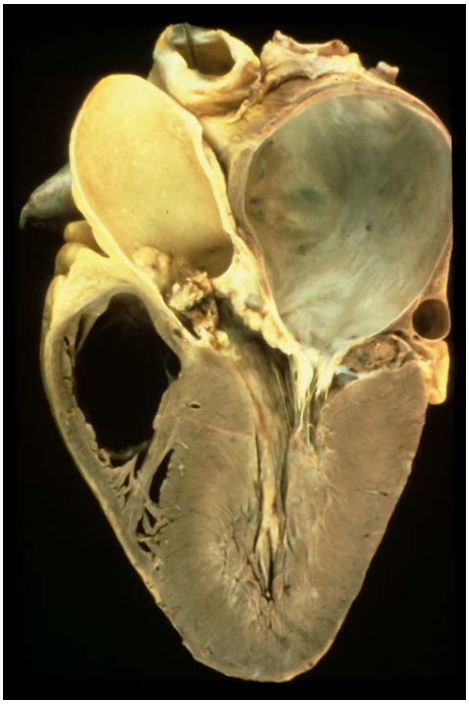

68. Heart: aortic stenosis with left ventricular hypertrophy
The left atrium is at the bottom of the screen and the left ventricle lumen is markedly diminished owing to LVH. The aortic valve just above the left atrium is markedly calcified. **(CV250)**

69. Heart: aortic insufficiency secondary to old rheumatic heart disease
Note that the aortic valve is fibrotic and plastered against the aorta, hence leaving an expanded AV orifice (blood will leak back into the LV during diastole). As expected, the LV was volume overloaded and exhibits both dilatation and hypertrophy. **(CV061)**

70. Aortic valve: infective endocarditis complicating a ventricular septal defect
A metal probe exits one of the two holes in the membranous portion of the IVS. This represents a VSD. Small vegetations line the valve cusps and the thread extends through a hole in the valve that developed from the infection. The edge of the other valve cusp looks half

eaten away. This underscores the increased incidence of infective endocarditis in patients with an underlying congenital defect. **(CV264)**

Previous | Next

Return to Top | Return to Image Index

Pathology I Images

Cardiovascular

It is against copyright laws to make
electronic or printed copies of these slides!!

		71. Mitral Valve: acute infective endocarditis The vegetations are on the atrial side of the valve leaflets. Note the bulky vegetations and chordae tendineae that has been ruptured. *Staphylococcus aureus* grew out in the blood culture. **(CV259)**
		72. Patient: splinter hemorrhages on your left and Oslerï¿½s nodes on your right This patient has acute infective endocarditis. Recall that these lesions are an example of immunocomplex vasculitis (type III hypersensitivity). **(CV064)**
		73. Retina: Roth's spot in a patient with acute infective endocarditis Note the red lesion with a pale center (arrow). This represents an immunocomplex vasculitis with hemorrhage. **(CV065)**
		74. Heart: Libman-Sack's endocarditis involving the mitral valve in a patient with SLE The warty vegetations located all over the valve and portions of the chordae are sterile, just like those in acute rheumatic fever. Both are examples of immunologic damage leading to immune deposits in the valve and fibrinoid necrosis. Pericarditis, rather than endocarditis, is the most common cardial lesion in patients with SLE. **(CV257)**

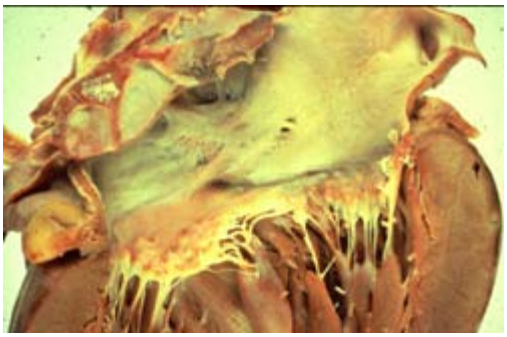

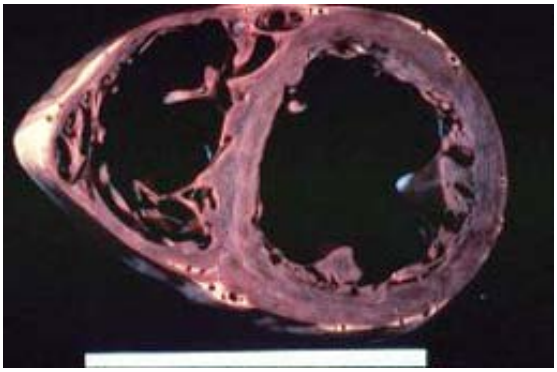

75. Heart: congestive cardiomyopathy
Note the extreme dilatation of both the left (on your right) and right ventricular chambers (on your left). The patient had a previous history of a coxsackie myocarditis. **(CV066)**

76. Heart: hypertrophic cardiomyopathy
Note the asymmetric thickening of the interventricular septum when compared to the thickened free LV wall. The anterior leaflet of the MV is stretched tautly and almost touches the bulging interventricular septal muscle. Note the very narrow orifice created by these two closely approximated structures. When blood passes through this narrow opening, the negative pressure behind it sucks the anterior leaflet against the IVS muscle and obstructs blood flow. **(CV067)**

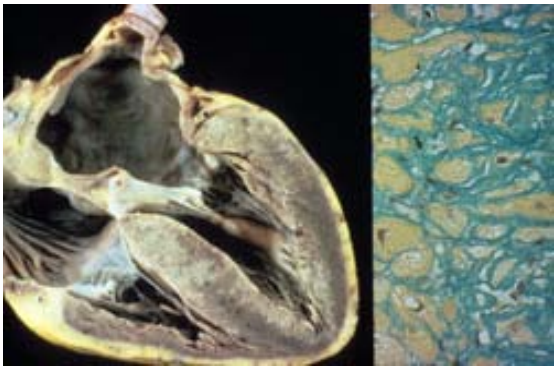

77. Heart: restrictive cardiomyopathy secondary to amyloidosis
Note the thickened myocardial tissue and the blotchy-white deposits of amyloid in the muscle. The special stain on the right demonstrates the blue-green staining amyloid encasing and destroying the myocardial fibers. **(CV068)**

78. Heart: left atrial myxoma
Note the huge ball-like structure attached to the wall of the left atrium. One can easily picture it dropping on top of the MV orifice and obstructing blood flow (syncope occurs) or pieces of the tumor embolizing into the systemic circulation. **(CV069)**

79. Heart: fibrinous pericarditis
This is a classic example of fibrinous inflammation involving the visceral pericardium ("bread and butter" pericarditis). Fibrinous inflammation is due to increased vessel permeability leading to the leakage of a sterile exudate with fibrin on to the surface of the heart. The patient would likely have had a pericardial friction rub. This particular patient had SLE. **(CV070)**

80. Chest x-ray: pericardial effusion
Note the "water bottle" configuration of the heart owing to a collection of fluid in the pericardial sac. The patient had a coxsackie myocarditis and pericarditis. **(CV071)**

81. Heart and Pericardium: constrictive pericarditis secondary to TB
Note the caseous necrosis in the hilar lymph nodes directly above the heart. The pericardium is markedly thickened and has chalky white area most likely representing dystrophic calcification. Note what little room the heart has to expand with blood and why a pericardial knock would likely be heard when the ventricle hit the thickened parietal pericardium during diastole. **(CV072)**

Previous | Next

Return to Top | Return to Image Index

Pathology I Images

Syllabus | Lecture Schedule | Images - Pathology I | Images - Pathology II

Respiratory

1 | 2 | 3 | 4 | 5 | 6

It is against copyright laws to make *electronic or printed* copies of these slides!!

1. Nasal passage: allergic rhinitis
Note the pale boggy mucosa in this patient with seasonal allergies. **(Res203)**

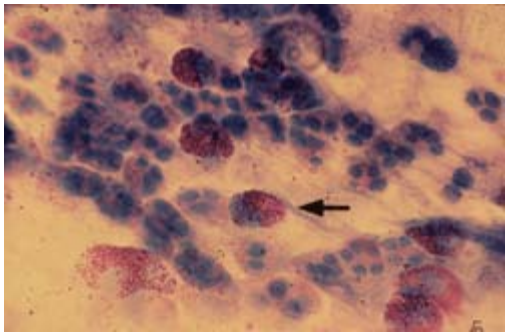

2. Nasal smear in above patient: eosinophils
A nasal smear of the above patient reveals predominantly eosinophils indicating the presence of a type I hypersensitivity reaction related to histamine release from mast cells. **(Res202)**

3. Laryngectomy: squamous cell carcinoma
The epiglottis is at the top. The false vocal cords are easily identified on your right, then a commissure, and then the true vocal cords. To your left, you see an ulcerated mass that has obliterated the true and false vocal cords. This is a squamous cell carcinoma. Smoking is the MCC followed by alcohol abuse. The two of them are synergistic. **(Neo056)**

4. Newborn lungs with hyaline membrane disease (respiratory distress syndrome)
RDS is due to a deficiency of surfactant, which normally reduces surface tension and keeps the airways from collapsing on

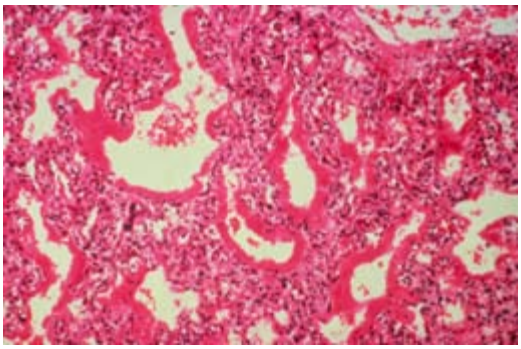

expiration. Note the collapsed alveoli throughout all lung fields. The ventilation defect related to massive atelectasis results in intrapulmonary shunting of blood and severe hypoxemia. The pink staining hyaline membranes are due to necrotic type II pneumocytes and fibrin from fibrinogen. **(Res261)**

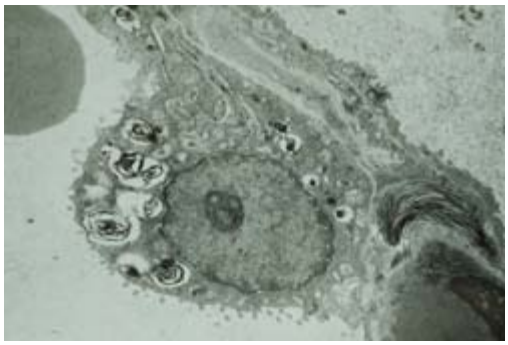

5. EM: type II pneumocyte with lamellar bodies
Note the concentric, lamellar bodies in the cytosol. These contain surfactant. The type II pneumocyte is also the repair cell of the lungs. When destroyed, as in RDS and ARDS, they contribute to the formation of hyaline membranes in both conditions. **(Res239)**

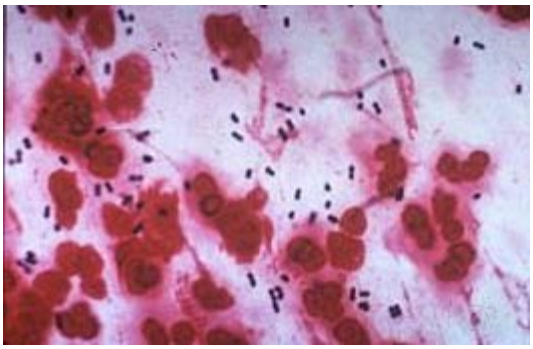

6. Gram stain of sputum with *Streptococcus pneumoniae*
Note the gram positive, lancet shaped diplococci. *S. pneumoniae* is the MCC of typical, community acquired pneumonia and is treated with penicillin G. **(Res007)**

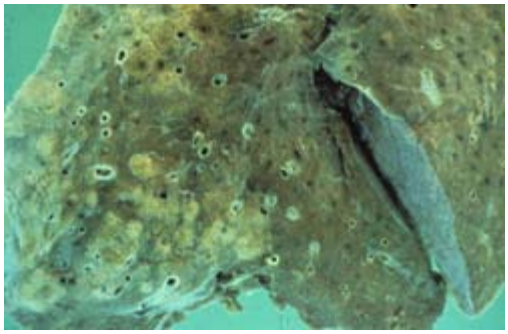

7. Lung: bronchopneumonia
Note the yellow white patches scattered throughout the lower lobe. These represent foci of consolidation in a patient with *S. pneumoniae* bronchopneumonia. **(Res205)**

8. Lung: lobar pneumonia
Note the pale consolidation of the entire upper lobe. This is lobar pneumonia, which is also most commonly caused by *S. pneumoniae*. **(Res206)**

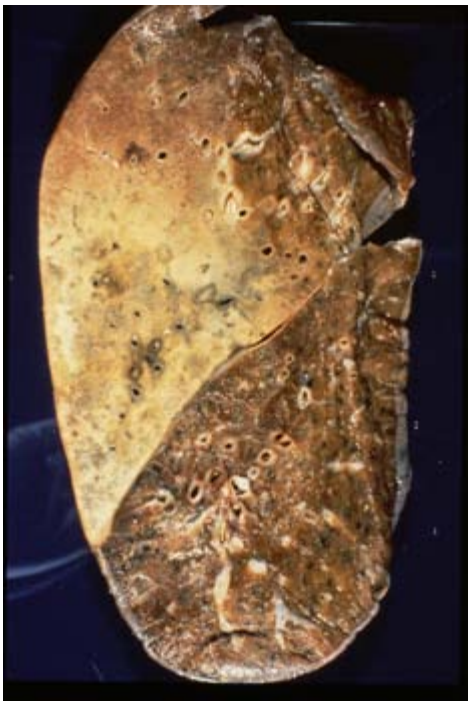

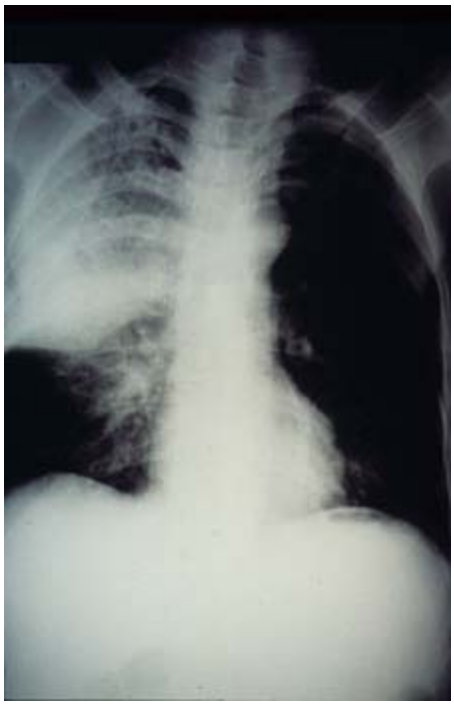

9. Chest x-ray: right upper lobe lobar pneumonia
Note the consolidation in the right upper lobe. Grossly, it would have looked like the previous slide. **(Res240)**

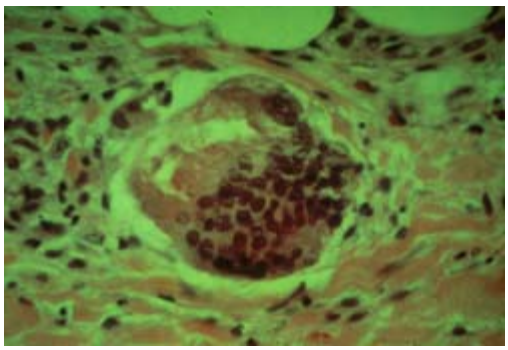

10. Lung biopsy: Warthin-Finkeldey multinucleated giant cell of measles
Measles pneumonia can be a serious complication. These are very characteristic giant cells that accompany measles. Measles along with adenovirus are also the most common antecedent infection predisposing to acute appendicitis in children. A tip off that measles was the cause is the presence of these giant cells in the inflammatory infiltrate of the appendix. **(Res243)**

Previous | Next

Return to Top | Return to Image Index

Pathology I Images

Respiratory

It is against copyright laws to make *electronic or printed* copies of these slides!!

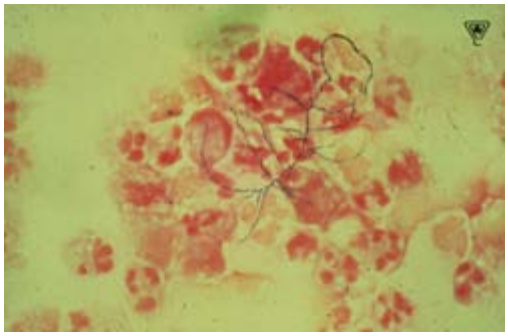

11. Gram stain of sputum in a cardiac transplant patient with pneumonia: Nocardiosis
Note the branched, gram positive, aerobic bacteria within the inflammatory infiltrate. These organisms are partially acid fast, unlike Actinomyces, which is a gram positive strict anaerobe. **(Res208)**

12. X-ray of lateral neck: thumbprint sign of acute epiglottitis due to *Hemophilus influenzae*
Note the "thumbprint" appearance of the swollen epiglottis. Inspiratory stridor was present in this child. **(Res201)**

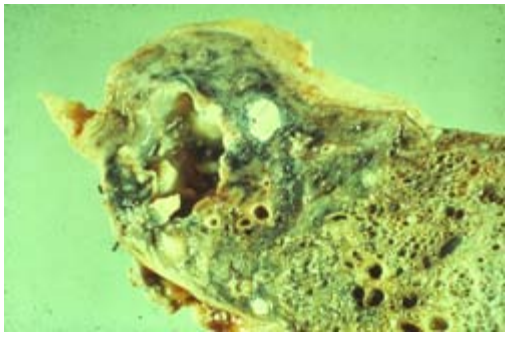

13. Cavitary lesion in the right upper lobe: reactivation tuberculosis
Note the cavitary lesion lined by caseous material. The apex has the highest oxygen content, which explains why TB, a strict aerobe, enjoys this location. Cavitation occurs, since the patient has previously been exposed to TB, which causes an intense inflammatory reaction involving T cells and their cytokines. **(Res244)**

14. Acid fast stain in TB
Mycolic acid in the cell wall is responsible for acid-fastness in TB. **(Res245)**

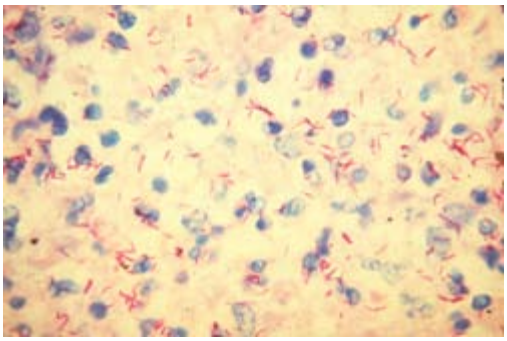

15. Chest x-ray with miliary tuberculosis
Careful observation reveals small densities throughout both lung fields representing miliary spread. This could have been due to a caseous focus extending into a bronchus or into the pulmonary artery. **(Res209)**

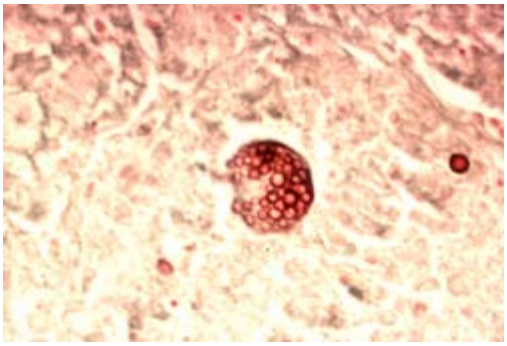

16. Spherule with endospores: *Coccidioides immitis*
Coccidioides is indigenous in the southwestern states. Arthrospores are inhaled in dust. **(Res247)**

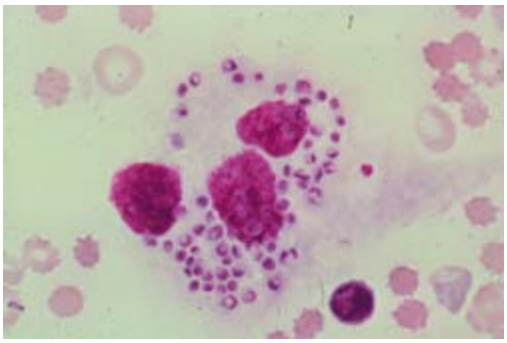

17. Macrophage with phagocytosed *Histoplasma capsulatum*
Note the yeast forms of *Histoplasma* in this macrophage in the bone marrow. *Histoplasma* is indigenous in the Ohio-Tennessee valley. Starlings, bats, and caves are the key words to remember. **(Res210)**

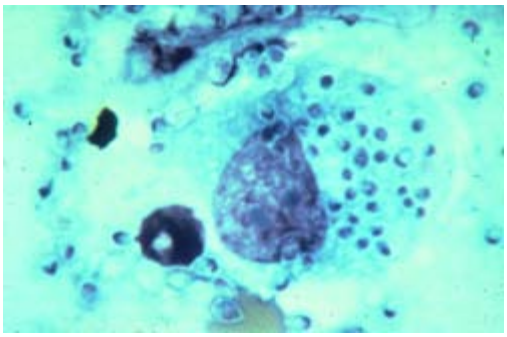

18. Macrophage with phagocytosed *Histoplasma capsulatum*
Note the yeast forms of *Histoplasma* in this alveolar macrophage in the lung. **(Res246)**

19. Verrucous skin lesion on

the face: *Blastomyces dermatitidis*
Note the raised, wart-like lesion on the face. This is characteristic of blastomycosis. **(Res250)**

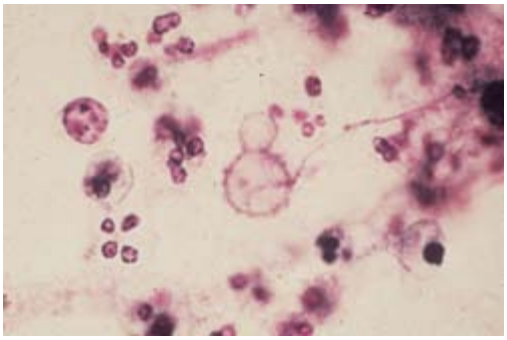

20. Broad based bud of *Blastomyces dermatitidis*
Blastomycosis frequents the southern states. **(Res251)**

Previous | **Next**

Return to Top | **Return to Image Index**

Pathology I Images

Respiratory

It is against copyright laws to make *electronic or printed* copies of these slides!!

21. Chest x-ray: bilateral apical cavities containing the fungus ball of *Aspergillus fumigatus*
Note the fuzzy appearance within the apical cavities (old abandoned TB cavities). These represent the fungus balls of *Aspergillus*. Massive hemoptysis is a potential complication. **(Res211)**

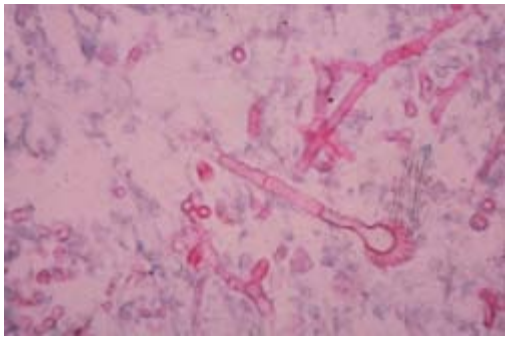

22. PAS stain of Aspergillus
Note the classic corona of *Aspergillus*. The hyphae are septate and have narrow angles. *Aspergillus* is a vessel invader. **(Res212)**

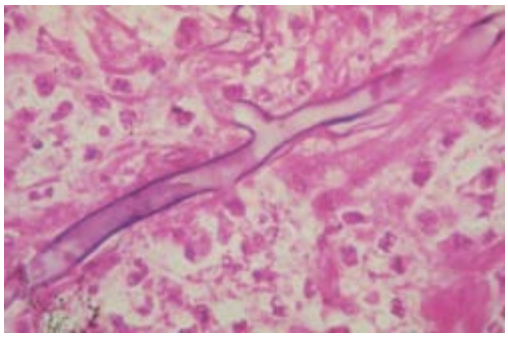

23. PAS stain of Mucor
Note the non-septate, wide angled hyphae of *Mucor*. *Mucor* is a vessel invader. **(Res213)**

24. Section of lung with *Pneumocystis carinii*
Note the foamy exudate in the alveoli. This is the MC AIDS defining infection. *Pneumocystis* is a fungus. **(Res214)**

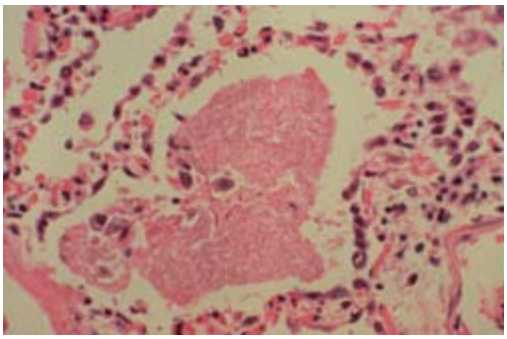

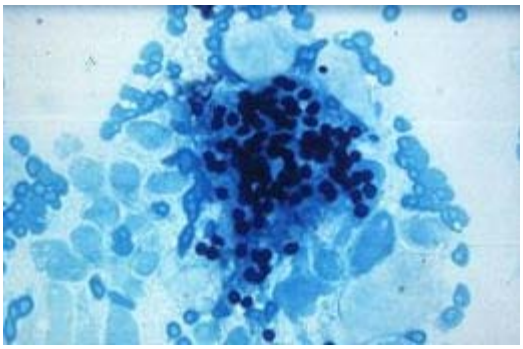

25. Silver stain of *Pneumocystis carinii*
Note the round and crushed cysts in the lavage specimen from the lungs of a patient with AIDS. TMP/SMX is the Rx of choice. **(Res013)**

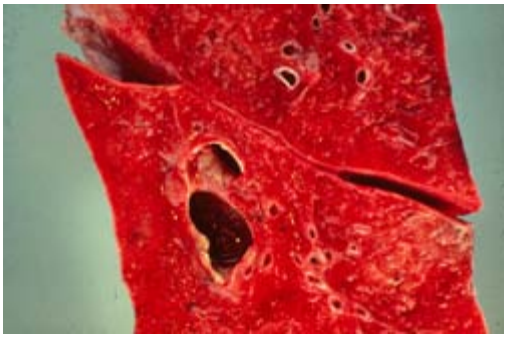

26. Superior segment of the right lower lobe: lung abscess
Note the cystic cavity lined by purulent material (liquefactive necrosis). The patient was an alcoholic who aspirated oropharyngeal material while sleeping on his back. Mixed aerobe/anaerobe organisms were present in culture. **(Res248)**

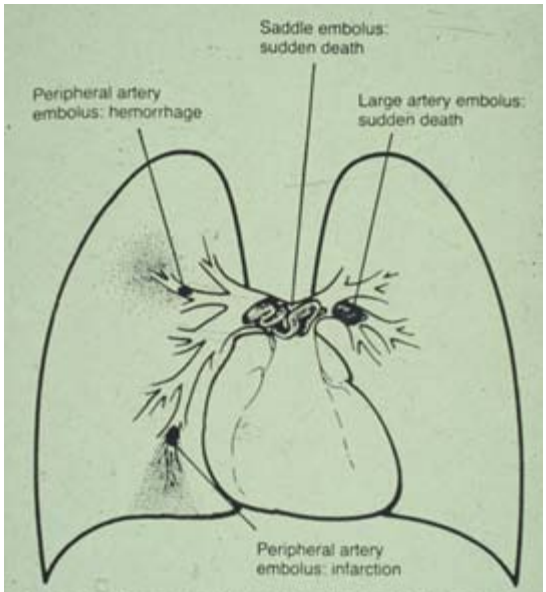

Figure 13–2. Diagram representing patterns of pulmonary emboli. The two large central emboli cause sudden death but do not induce infarction. The peripheral arterial embolus at the base causes infarction, whereas the analogous small embolus in a younger patient causes only hemorrhage.

27. Schematic of pulmonary embolus
Pulmonary emboli can be large leading to occlusion of the pulmonary artery orifices (saddle embolus) or small, the latter resulting in wedge shaped hemorrhagic infarctions (coagulation necrosis). Most emboli do not cause infarction unless the patient has preexisting lung disease. The majority of pulmonary emboli come from the femoral vein. **(Res215)**

28. Pulmonary artery: saddle embolus

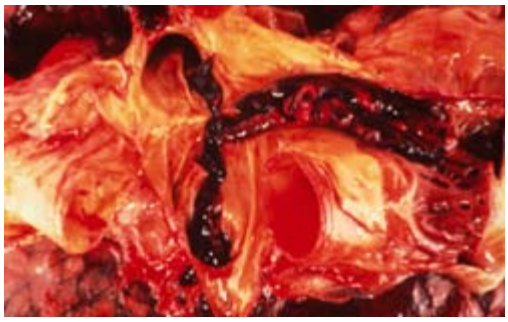

Note the large embolus essentially occluding the entire lumen of the PA. This produces sudden death due to acute right heart strain. There is no time for infarction. **(Res216)**

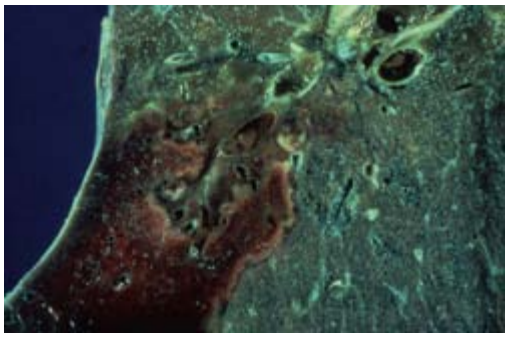

29. Hemorrhagic infarction of the lung
Note the wedge shaped infarction extending to the pleura (explains pleuritic chest pain and presence of a hemorrhagic pleural effusion). The vessel occluded by an embolus is located at the apex of the infarct. **(Res217)**

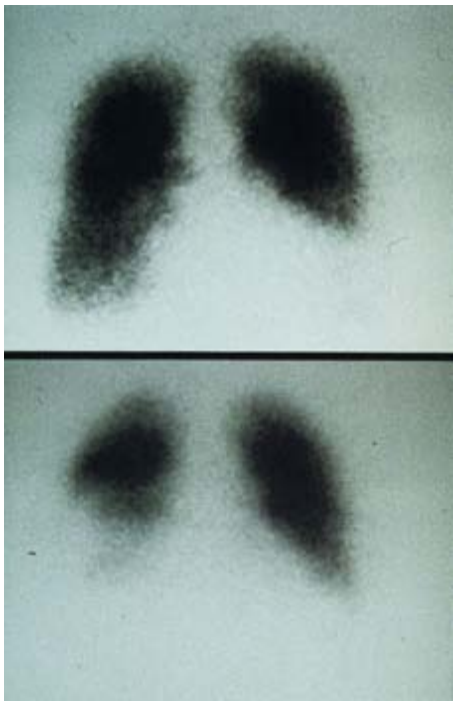

30. Ventilation perfusion scan in a patient with a pulmonary embolus to the right lower lobe (RLL)
The right lung is on your left. A ventilation scan is on the top and shows uptake of the scan material in both lungs, however, note the slightly fuzzy appearance at the base of the RLL. The perfusion scan is on the bottom and it clearly shows a lack of perfusion in the RLL. A V/P scan is the initial test of choice to screen for a PE. **(Res252)**

Previous | **Next**

Return to Top | **Return to Image Index**

Pathology I Images

Respiratory

It is against copyright laws to make *electronic or printed* copies of these slides!!

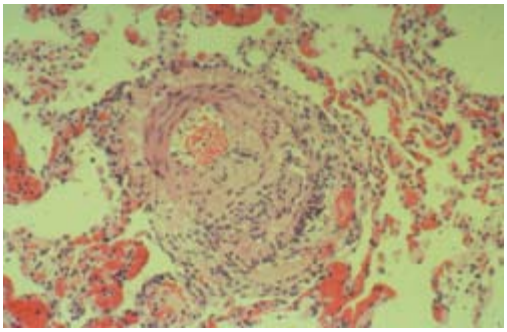

31. Histologic section of a thickened pulmonary vessel in a patient with pulmonary hypertension (PH)
Note the small calibre lumen of the vessel (space with RBCs). The vessel wall is thickened owing to hyperplasia and hypertrophy of smooth muscle cells.
(Res253)

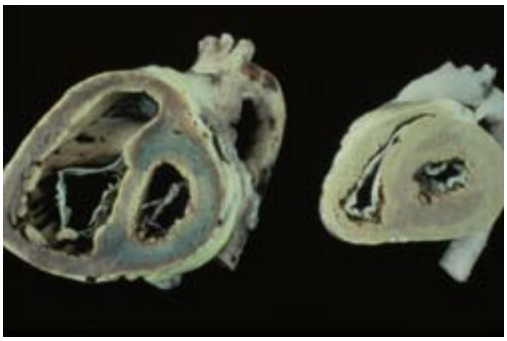

32. Normal heart on the right and heart with right ventricular hypertrophy (RVH) on the left in a patient with PH
Note the thick right ventricular wall on your left compared to the normal right ventricular wall on your right. It is thickened because of the afterload it had to contract against in the pulmonary vessel. The combination of PH and RVH is called cor pulmonale, if the PH is secondary to primary lung disease or a primary pulmonary artery hypertension. PH secondary to cardiovascular disease does not qualify. **(Res254)**

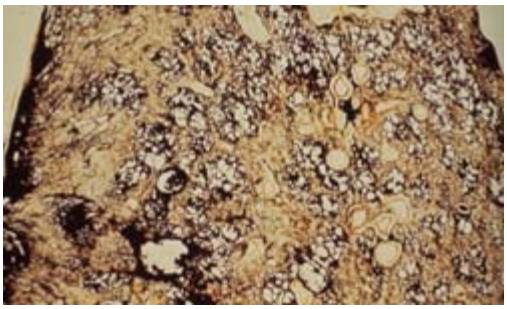

33. Coal worker's pneumoconiosis (restrictive lung disease)
The black pigment is anthracotic pigment. The dilated spaces represent centrilobular emphysema. There is an increase in fibrous tissue throughout the lungs (progressive massive fibrosis) in between the areas of emphysema. CWP is primarily a restrictive type of lung disease, however, there is a small component of emphysema, which is obstructive. Patients are susceptible to TB but not cancer.

(Res218)

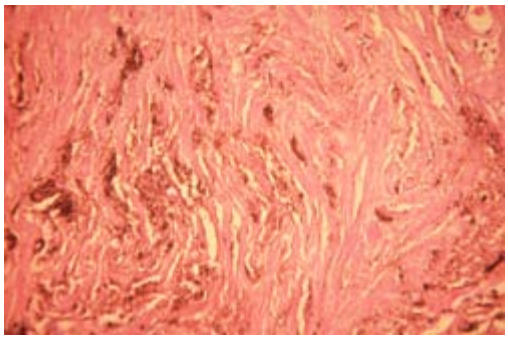

34. Silicotic nodule in the lungs in a patient with silicosis (restrictive lung disease)
Note the solid areas of fibrous tissue. If this was polarized, it would reveal silica crystals throughout the nodule. This disease commonly occurs in sandblasters. Patients are susceptible to TB but not cancer. **(Res219)**

35. Section of lung with asbestos fibers (ferruginous bodies, restrictive lung disease)
Note the rusty colored, dumbbell shaped bodies in the lung tissue. These represent asbestos fibers coated by iron. Benign pleural plaques are the MC manifestation of asbestos exposure. Primary lung cancer is more common than mesothelioma. Smoking + asbestos exposure has a synergistic effect on increasing risk for lung cancer rather than a mesothelioma. **(Res220)**

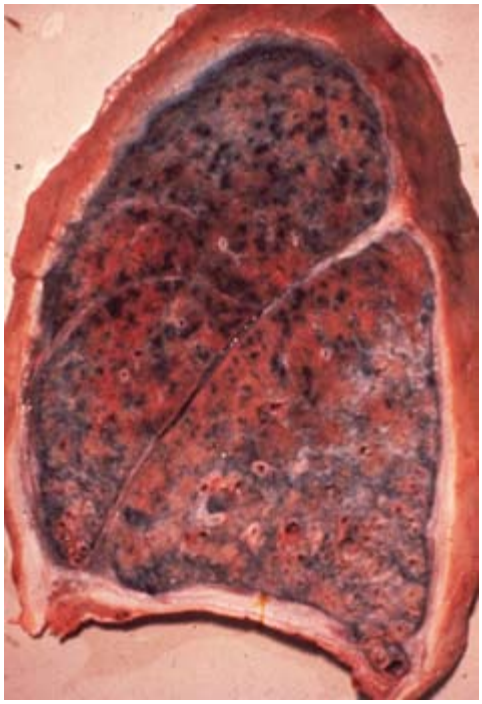

36. Mesothelioma (restrictive lung disease)
Note that the entire lung is encased by thickened pleura. This is characteristic of a mesothelioma, which is a highly malignant tumor. It requires at least 20-40 years for these to develop, unlike primary lung cancer, which explains why the latter is more common. There is no smoking relationship with mesotheliomas. **(Res221)**

37. Hamman Rich lung (restrictive lung disease)
HR lungs are the end result of an alveolitis. Note the cystic spaces resembling a honeycomb along the outer portions of the lung. Alveolar fibrosis leads to proximal dilatation of the small airways.

(Res257)

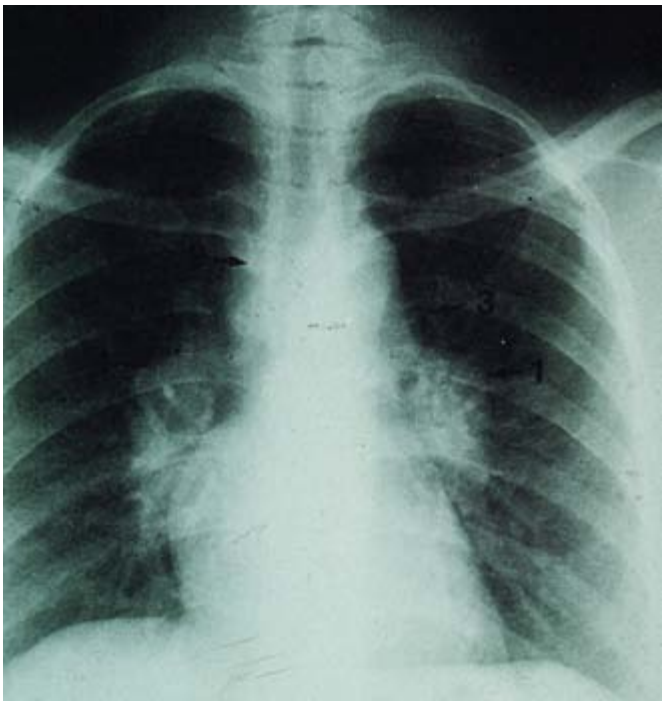

38. Chest x-ray in a patient with sarcoidosis (restrictive lung disease)
Note the markedly enlarged hilar lymph nodes ("potato nodes"). Along both lung bases there is a very fine reticulonodular pattern representing interstitial fibrosis. **(Res256)**

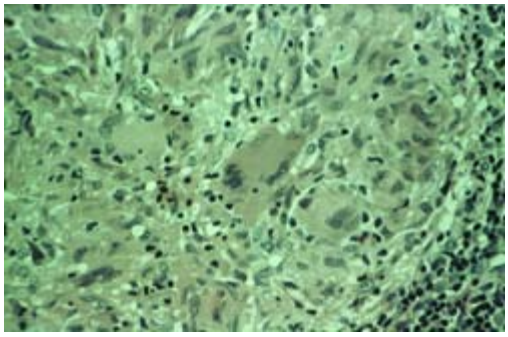

39. Non-caseating granuloma in a hilar lymph node in a patient with sarcoidosis (restrictive lung disease)
Note the multinucleated giant cells and the pink staining epithelioid cells representing activated macrophages. **(Res255)**

40. Pink puffer (left) and blue bloater (right): obstructive lung disease

Pink puffers predominantly have emphysema, which involves the respiratory unit, while blue bloaters have chronic bronchitis, which primarily obstructs the more proximal terminal bronchioles, hence the greater trapping of CO_2 leading to respiratory acidosis, hypoxemia, and cyanosis (note facial discoloration). **(Res222)**

Previous | **Next**

Return to Top | **Return to Image Index**

Pathology I Images

Respiratory

It is against copyright laws to make *electronic or printed* copies of these slides!!

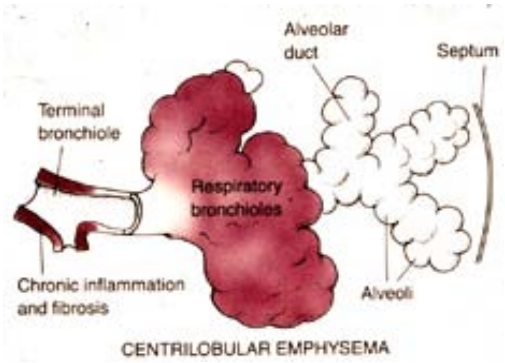

41. Schematic of centrilobular emphysema (obstructive lung disease)
The respiratory bronchiole is the primary site of destruction in this type of emphysema. It is most commonly due to smoking and less commonly to CWP. The upper lobes are primarily involved. **(Res223)**

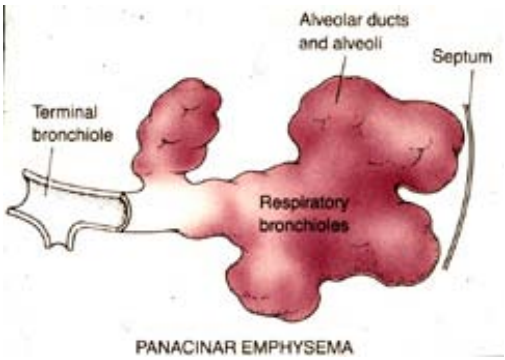

42. Schematic of panacinar emphysema (obstructive lung disease)
The entire respiratory unit is destroyed in this type of emphysema, which is due to a deficiency of AAT. It may be acquired in smokers and inherited as an AR disease. The lower lobes are primarily involved. **(Res224)**

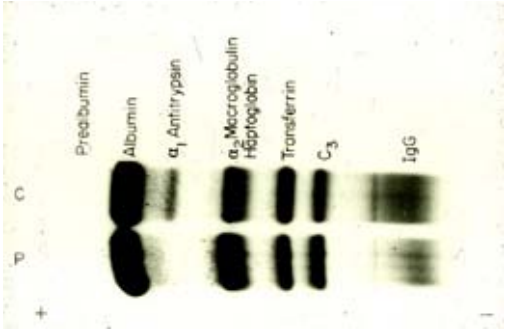

43. Serum protein electrophoresis in a patient with hereditary AAT deficiency (obstructive lung disease)
The top SPE pattern labeled C is normal. Compare this to the lower SPE labeled P. Note that the a1 globulin component is missing. This is due to lack of liver synthesis of the protein. **(Res226)**

44. Bronchiectasis (obstructive lung disease)
Note the dilated, pus-filled bronchi extending to the pleural surface of the lung. Obstruction and infection weaken the bronchi causing them to dilate. Cystic fibrosis is the MCC in this country and TB in other countries. **(Res258)**

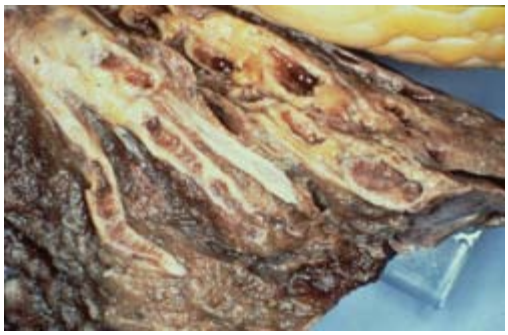

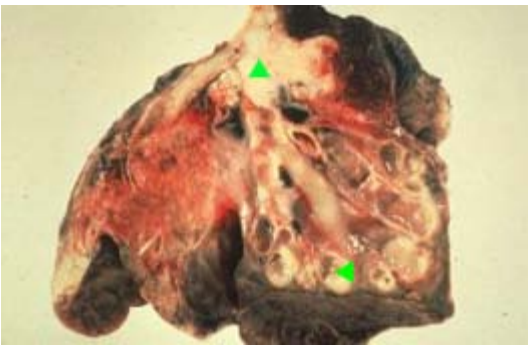

45. Main-stem bronchus cancer associated with bronchiectasis (obstructive lung disease)
At the top of the slide there is a white colored mass that has completely obstructed the main-stem bronchus. Behind the obstruction dilated, pus filled bronchi extend to the pleural surface. **(Res047)**

46. Patient with bronchial asthma (obstructive lung disease)
Note the increased anteroposterior diameter in the patient. This is due to air trapping behind the inflamed terminal bronchioles. **(Res225)**

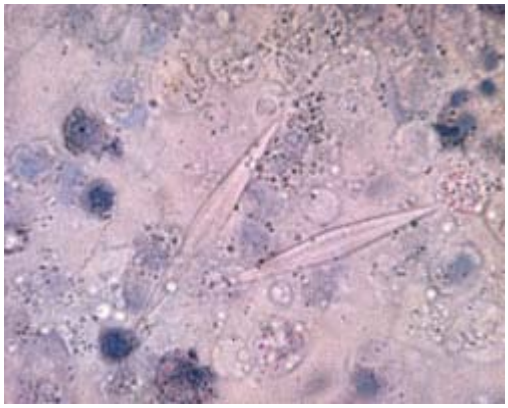

47. Sputum with Charcot-Leyden crystals in a patient with bronchial asthma (obstructive lung disease)
Note the spear-head shaped crystals representing crystalline material derived from degenerated eosinophils. **(Res200)**

48. Chest x-rays: left x-ray with a primary peripheral adenocarcinoma, right x-ray

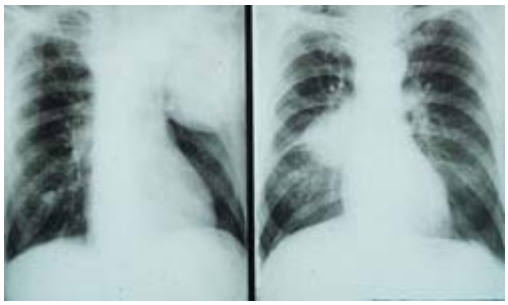

with primary centrally located cancer
Adenocarcinoma has replaced squamous cancer as the MC primary cancer. They are usually (not always) peripherally located. There are different variants of adenocarcinoma, some of which have no smoking relationship. Centrally located cancers include squamous cancer and small cell cancer. **(Res 228)**

49. Primary main-stem bronchus cancer
Toothpicks are necessary to keep the lumen open. Note the white material encircling and invading into the lumen of the main-stem bronchi. This could be either a squamous or small cell cancer. **(Neo058)**

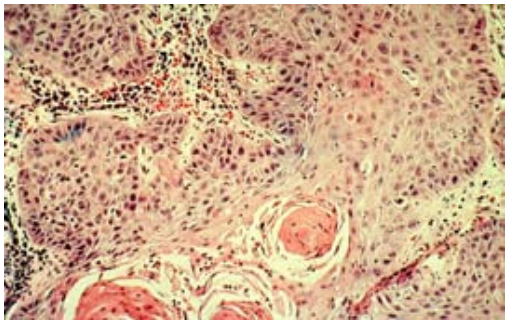

50. Well differentiated squamous cell carcinoma of lungs
Note the concentric areas of eosinophilic staining cells on the lower margin of the side. These are malignant squamous cells with keratin formation (called squamous pearls). **(Neo202)**

Previous | Next

Return to Top | Return to Image Index

Pathology I Images

Respiratory

It is against copyright laws to make *electronic or printed* copies of these slides!!

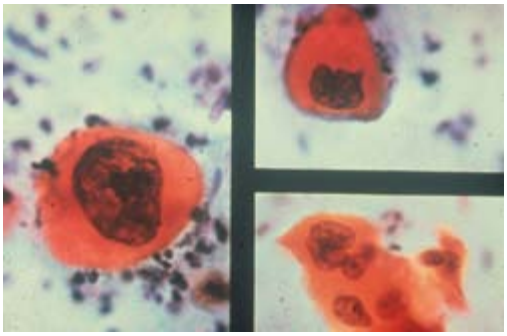

51. Pap smear of sputum with squamous cancer
Keratin stains bright red with a Papanicolaou stain. Note the malignant cells in each of the frames and the intense staining of the keratin. Squamous cancers may ectopically secrete PTH-like peptide leading to hypercalcemia. **(Res229)**

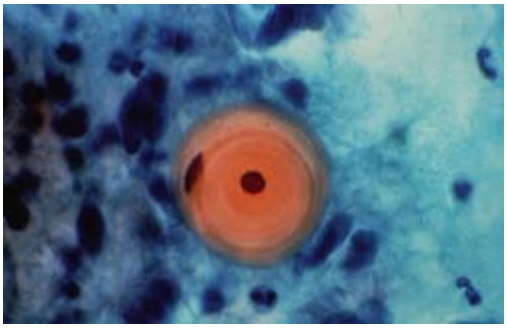

52. Pap smear with a malignant squamous pearl
Note the concentric appearance of this malignant cell containing keratin. **(Res231)**

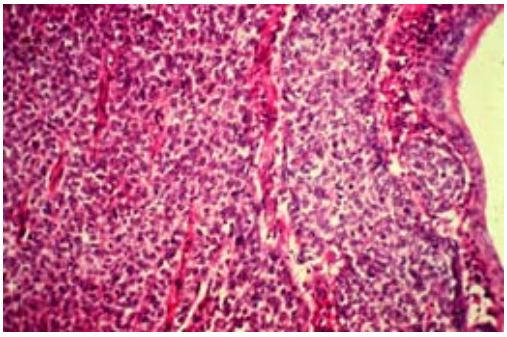

53. Lung biopsy in a patient with a small cell carcinoma
Note the diffuse infiltrate of small, dark cells throughout the tissue. Small cell cancers are of neural crest origin (neurosecretory tumors) and ectopically secrete ADH or ACTH in some cases. **(Res232)**

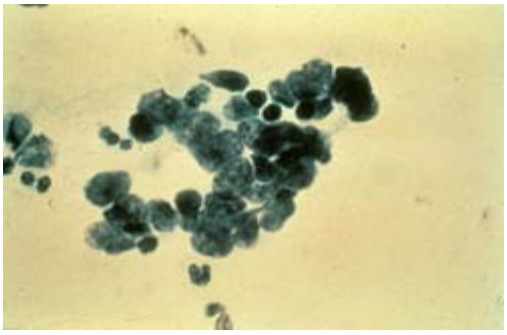

54. Pap smear of small cell cancer in sputum
The small cells resemble lymphocytes, hence they are frequently missed in sputum cytology. **(Res233)**

55. Lung with metastatic disease
Note the multifocal nature of

metastasis. Primary lung cancers are usually solitary. Breast cancer is the MC malignancy metastasizing to lungs. **(Res235)**



56. Lung with metastatic disease along the visceral pleural surface
Note the white nodular masses lining the pleura on your left. **(Res259)**

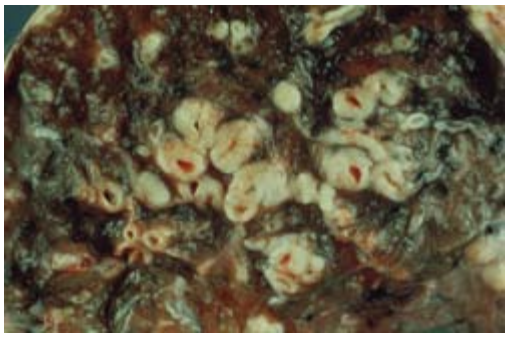

57. Lung with metastatic disease in lymphatics surrounding airways
Note the white tumor encircling small airways throughout the lungs. This produces intense dyspnea in the patient. **(Res237)**

58. Patient with Horner's syndrome
The patient has a Pancoast tumor (superior sulcus tumor), which is most often due to a primary squamous cancer at the lung apex involving the brachial plexus and superior cervical ganglion. Destruction of the superior cervical ganglion, located in the posterior mediastinum, produces Horner's syndrome. Horner's syndrome includes ipsilateral lid lag (drooped right

eyelid), miosis (look hard and note that the right pupil is constricted compared to the left), and anhydrosis (absence of sweating). **(Res234)**

Previous | **Next**

Return to Top | **Return to Image Index**

Pathology I Images

Gastrointestinal

It is against copyright laws to make *electronic or printed* copies of these slides!!

1. Cleft palate
Due to failure of fusion of the facial processes in the embryonic period. **(Gi200)**

2. Herpes simplex
Note the vesicular lesions above the vermilion border of the lip. The virus remains dormant in the cranial sensory ganglia. **(Gi201)**

3. Exudative tonsillitis
Note the pus covering both tonsils. The majority are viral in origin. *Streptococcus pyogenes* is the MC bacteria. **(Gi263)**

4. Hairy leukoplakia
Note the white plaque-like material on the lateral border of the tongue. It is a pre-AIDS EBV infection of the tongue. It is not precancerous. **(GI261)**

5. Oral thrush
Note the white exudate on the dorsal surface of the tongue. This patient is HIV positive. Oral thrush occurs

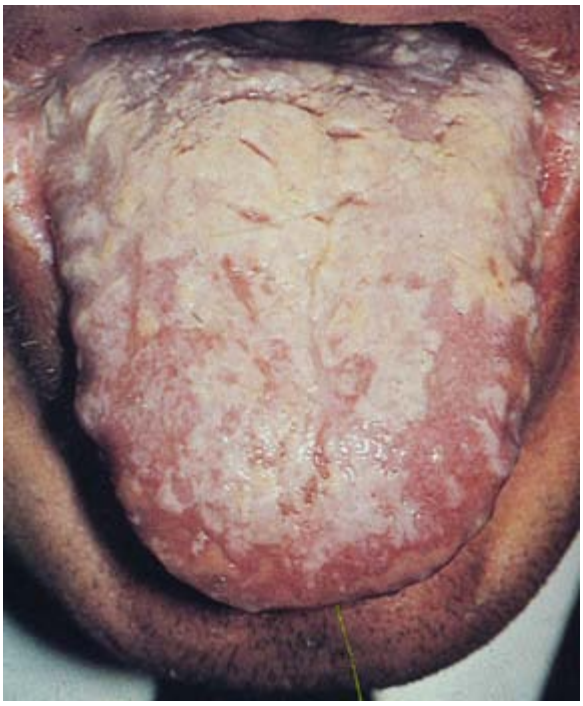

as a pre-AIDS infection and is not AIDS-defining. **(Gi208)**

6. Oral thrush in a child
See above description **(Gi008)**

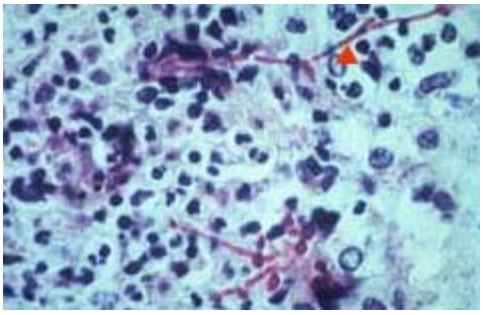

7. Stain of *Candida albicans*
Note the pseudohyphae and budding yeasts surrounded by an inflammatory infiltrate. **(Gi009)**

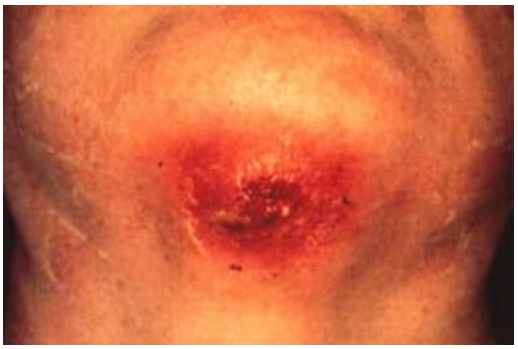

8. Draining sinus of *Actinomyces*
This patient had a dental abscess with tooth extraction a few weeks ago and now has a sinus draining pus. Yellowish granules are noted which contain the gram positive filamentous bacteria. The organism is a strict anaerobe. **(Gi205)**

9. Pseudomembrane of *Corynebacterium diphtheriae*
Note the toxic induced white pseudomembrane in the trachea. It is a non-invasive bacteria. Pathogenesis is similar to pseudomembranous colitis caused by the toxin of *Clostridium difficile*. **(Gi206)**

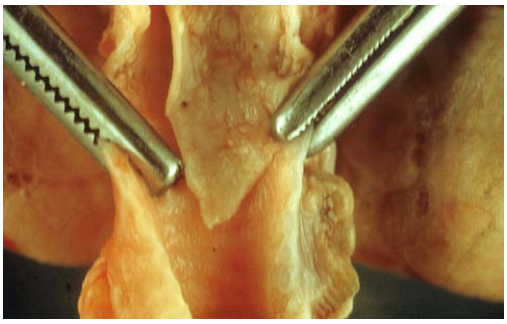

10. Scarlet fever
This slide shows a coated tongue with hyperemic fungiform papillae. This is predominantly a disease of children and is caused by several strains of ï¿½-hemolytic Streptococci. The organism produces an erythrogenic toxin with an associated rash. STRAWBERRY TONGUE. **(Gi013)**

Previous | Next

Return to Top | Return to Image Index

Pathology I Images

Gastrointestinal

It is against copyright laws to make
electronic or printed copies of these slides!!

11. Scarlet fever
This slide shows a tongue with the white material sloughed off. The underlying tongue appears red with hyperemic fungiform papillae. This is called a RASPBERRY TONGUE. **(Gi011)**

12. Dental caries
Note the black discoloration at the gingival margins. This represents a breakdown of the enamel of the teeth secondary to an interaction of bacteria, saliva, and dietary substances. **(Gi015)**

13. Child with mumps
Note the bilateral parotitis.
(Gi216)

14. Leukoplakia (right frame) and invasive squamous cancer (left frame)

leukoplakia is a clinical description for a white (sometimes red) plaque that does not scrape off. Biopsy is always necessary to exclude squamous dysplasia vs cancer. Invasive cancer in the tongue on your left is noted by change in color of the right half of the tongue. **(Neo064)**

15. Squamous cell carcinoma of lower lip
Note the raised crusted lesion on the lower lip. As a rule, squamous cancers frequent the lower lip and basal cell carcinoma the upper lip. **(Gi213)**

16. Pleomorphic adenoma (mixed tumor) of the parotid
Note the swelling at the angle of the jaw. This is the MC benign tumor of the major and minor salivary glands. **(Gi214)**

17. Zenker's diverticulum of the esophagus
Note the pouch (pulsion diverticulum) behind the esophagus. **(Gi217)**

18. Tracheoesophageal diverticulum schematic
Note that the proximal esophagus ends blindly and the distal esophagus arises from the trachea (reason for air in the stomach). Mothers have polyhydramnios. **(Gi218)**

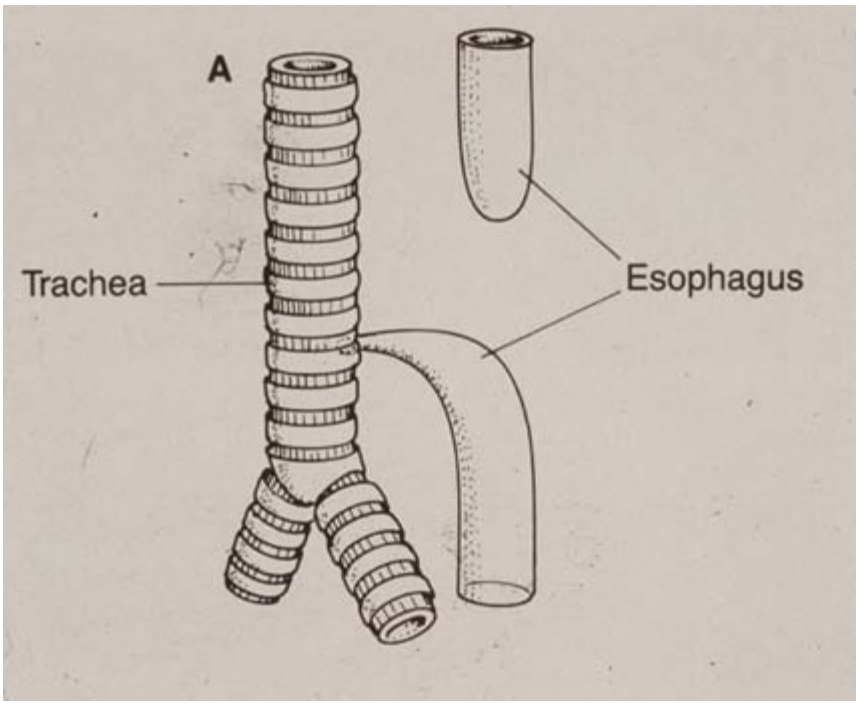

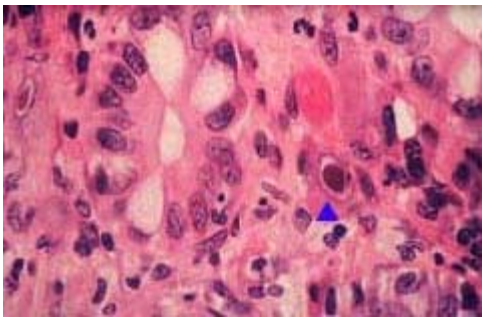

19. Cytomegalovirus infection of the esophagus
Note the enlarged cell with a nucleus containing a large intranuclear basophilic inclusion. This is characteristic of CMV which is a common pathogen in AIDS patients. **(Gi037)**

20. Achalasia
This is a gross specimen from a case of achalasia. Note that the wall of the esophagus is thickened or hypertrophic. The failure of the lower esophageal sphincter to relax is related to a decrease in the numbers of ganglion cells. **(Gi016)**

Previous | Next
Return to Top | Return to Image Index

Pathology I Images

Gastrointestinal

It is against copyright laws to make *electronic or printed* copies of these slides!!

21. Achalasia: See above description. **(Gi219)**

22. Reflux Esophagitis
This is the most common type of esophagitis. There is acid chemical damage to the mucosa of the esophagus, owing to relaxation of the LES. Barrett's esophagus is a complication of GERD and predisposes to distal adenocarcinoma. **(Gi017)**

23. Esophageal varices
Note the distention of the esophageal submucosal veins associated with portal hypertension. The left gastric vein is primarily involved. **(Gi021)**

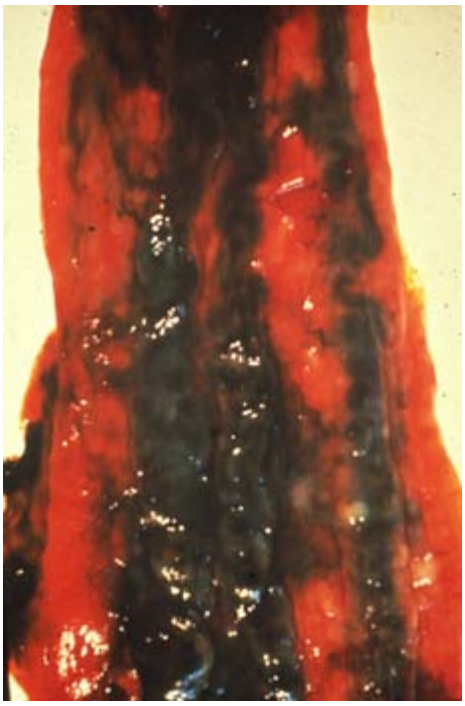

24. Mallory-Weiss syndrome
Note the lacerations in the upper stomach and lower esophagus. This syndrome is seen in alcoholics and bulimics followed by retching and vomiting. **(Gi224)**

25. Esophageal squamous cell carcinoma of mid-esophagus
Note the complete obstruction of the esophageal lumen by white tumor. It has metastasized to the lymph nodes on the opposite side. Smoking and alcohol are the major risk factors. **(Neo066)**

26. Squamous cell carcinoma
This slide shows an annular carcinoma of the esophagus which is extending into the surrounding

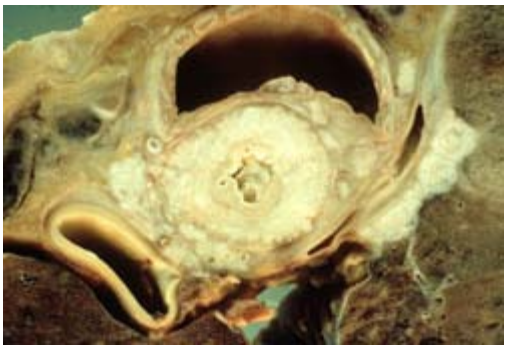

tissues. Tissues in the regional area include trachea and aorta. **(Gi023)**

27. Congenital Pyloric stenosis
This gross specimen of stomach shows hypertrophy of the pyloric sphincter with accompanying hypertrophy of the wall of the stomach. **(Gi024)**

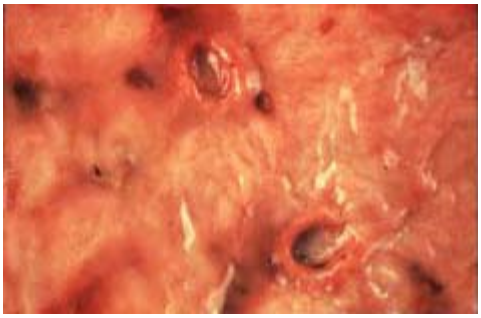

28. Acute hemorrhagic (erosive) gastritis
These ulcers are frequently multiple and are well-delineated craters of variable depth, usually below the muscular mucosa. They tend to bleed profusely. Associations include NSAIDs, debilitating illnesses, sepsis, and trauma. **(Gi025)**

29. Chronic atrophic gastritis
Note the atrophy of the rugal folds in this gross specimen of stomach. This is a descriptive diagnosis and the etiology is variable ranging from *Helicobacter pylori* infection (involves pylorus and anthrum) to pernicious anemia (involves body and fundus). **(Gi026)**

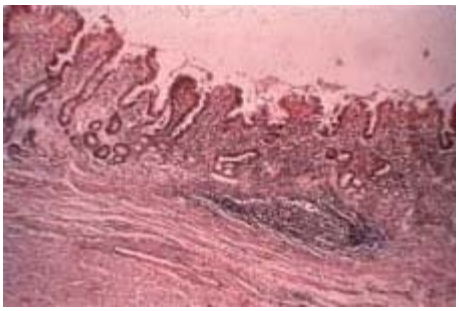

30. Chronic atrophic gastritis
This microscopic section shows atrophy of the stomach mucosa with an infiltrate of chronic inflammatory cells. **(Gi027)**

Previous | Next

Return to Top | Return to Image Index

Pathology I Images

Gastrointestinal

It is against copyright laws to make *electronic or printed* copies of these slides!!

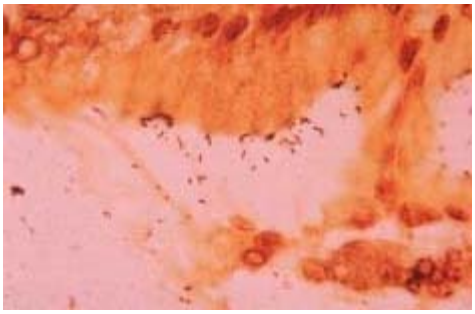

31. Helicobacter pylori gastritis
This slide demonstrates the gram-negative pleomorphic organism (stained with a silver stain) setting on the mucosal surface of the stomach. The organism is not invasive. **(Gi028)**

32. Menetrier's disease
Note the giant rugal folds. Patients lose protein in the mucus secretions. **(Gi264)**

33. Gastric ulcer
This slide demonstrates a gastric ulcer with hemorrhage in the base of the ulcer. The margins are uniform and cookie-cutter like. Most are located on the lesser curvature of the pylorus and antrum. **(Gi066)**

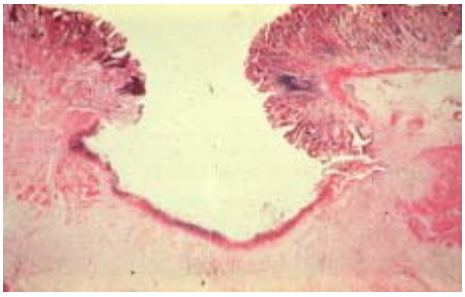

34. Gastric ulcer
This is a microscopic section of a healed gastric ulcer with fibrosis. **(Gi031)**

35. Leiomyoma
This is a benign smooth muscle tumor in the stomach which may occasionally bleed. The stomach in the most common location in the GI tract for this lesion. **(Gi032)**

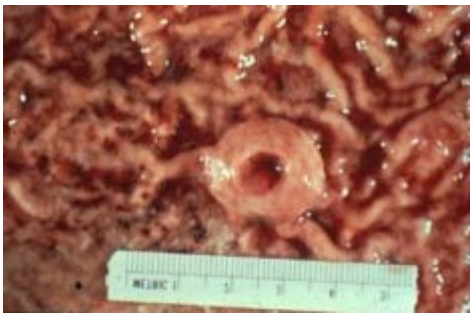

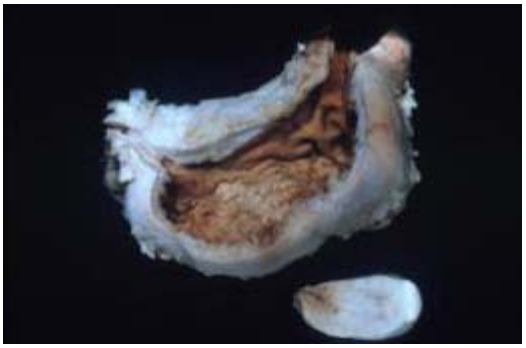

36. Linitis plactica (adenocarcinoma of the stomach) (signet ring carcinoma)
This tumor invades the wall of the stomach producing a desmoplastic response. The stomach becomes hard like a leather bottle. This tumor presents late in its course and has a tendency to metastasize to the ovaries. **(Neo068)**

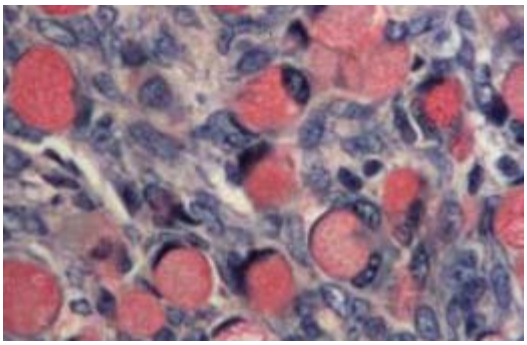

37. Krukenberg's tumor
This is a mucin stain of signet ring cells in the ovary. The tumor is a metastatic gastric carcinoma which has spread to the ovaries. **(Neo069)**

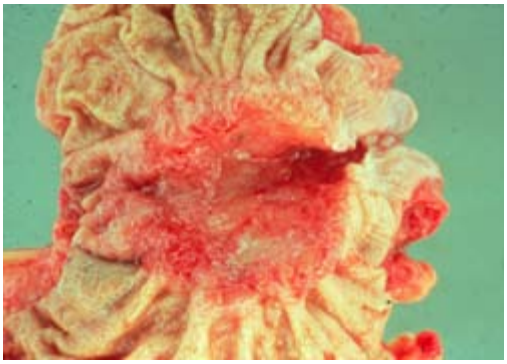

38. Gastric adenocarcinoma
Note the large ulcerated lesion in the stomach. **(Gi266)**

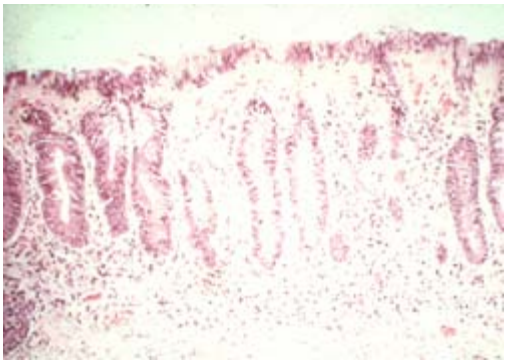

39. Celiac disease
Note the flattened villi and hyperplastic glands. Autoantibodies are directed against the gliadin fraction in gluten. **(Gi265)**

40. Dermatitis herpetiformis
Nnote the vesicular lesion on the elbows. This skin disorder has a high association with celiac disease. **(Gi267)**

Previous | Next
Return to Top | Return to Image Index

Pathology I Images

Gastrointestinal

It is against copyright laws to make
electronic or printed copies of these slides!!

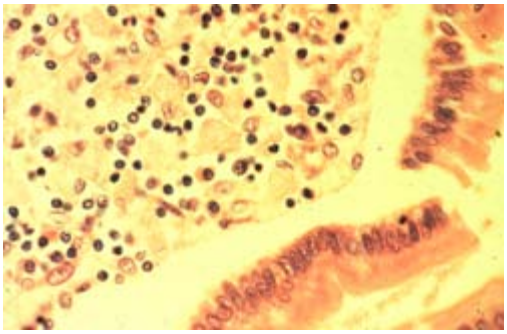

41. Whipple's disease
Note the foamy macrophages in the lamina propria of the small bowel. **(Gi268)**

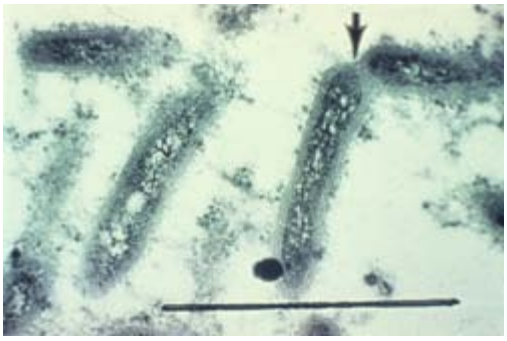

42. Whipple's disease
EM of the bacteria in the macrophages. **(Gi228)**

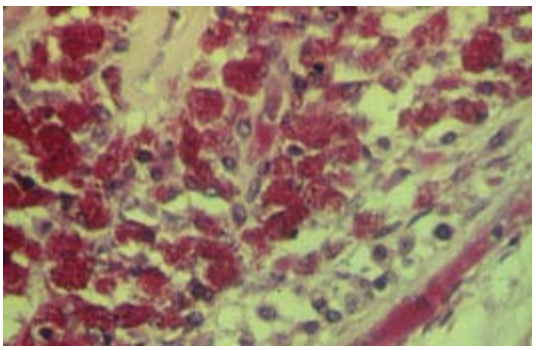

43. Mycobacterium avium intracellulare
This is a higher magnification of an acid-fast stain from a case of MAI in an AIDS patient. The disease simulates Whipple's disease in that it produces malabsorption. **(Gi229)**

44. Child with rotavirus infection
Note the volume depletion **(Gi230)**

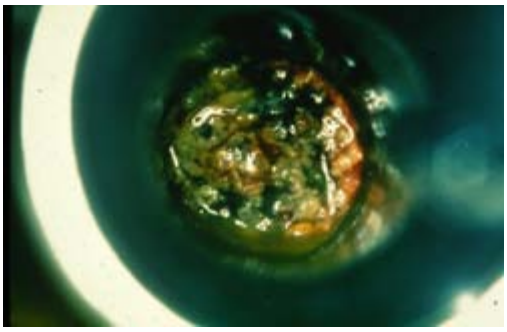

45. Shigellosis with pseudomembranes
Note the shaggy pseudomembranes **(Gi231)**

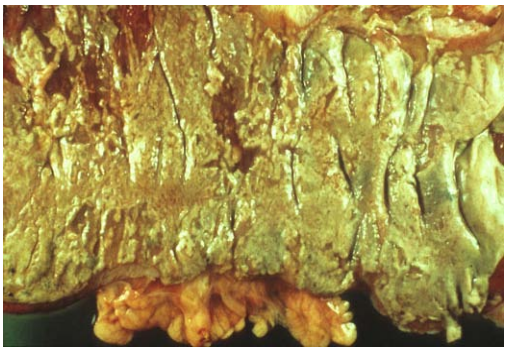

46. Pseudomembranous colitis due to *Clostridium difficile*
Note the shaggy membrane due to toxin-induced damage of the mucosa and submucosa. **(Gi269)**

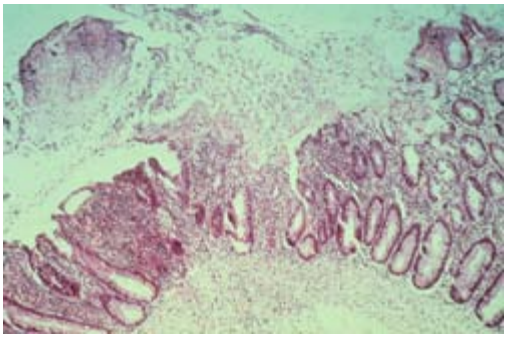

47. Flask shaped ulcer in cecum in amebiasis
Note the centrally located area of ulceration due to *Entameba histolytica*. **(Gi271)**

48. Amebiasis
This slide shows a colon biopsy on the right and a high magnification of amebic trophozoites on the left. The characteristic of the trophozoite is erythrophagocytosis. **(Gi036)**

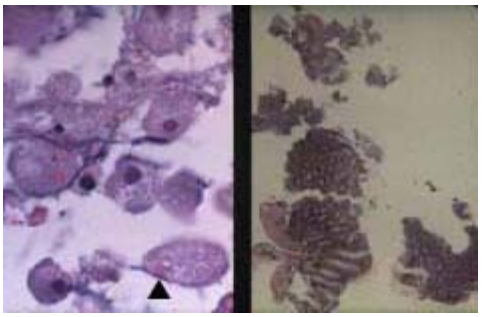

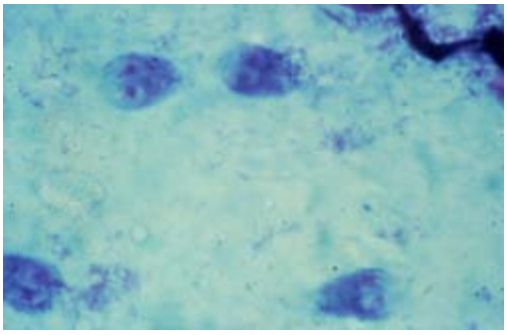

49. Giardiasis
This slide shows Giardia trophozoites. The organism is a flagellated protozoan that produces diarrhea, cramps, flatulence, and malabsorption by infecting the small intestine. **(Gi270)**

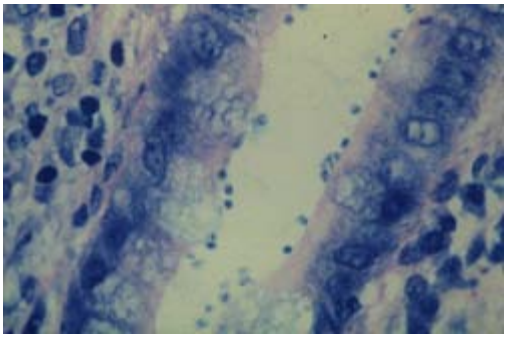

50. Cryptosporidiosis
Note the blue staining oocysts. They are acid-fast. **(Gi272)**

Previous | **Next**

Return to Top | **Return to Image Index**

Pathology I Images

Gastrointestinal

It is against copyright laws to make
electronic or printed copies of these slides!!

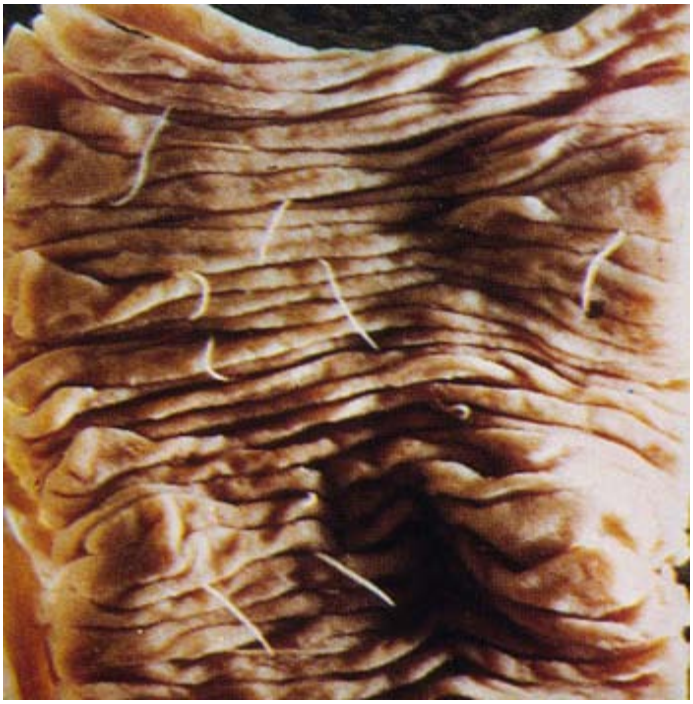

51. Necator (hookworm) infestation of the bowel
Note the worms attached to the surface of the mucosa. Iron deficiency is a complication. **(Gi235)**

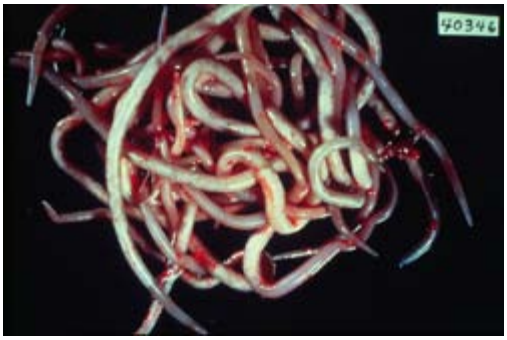

52. Ascariasis of bowel
Note the conglomeration of worms that obstructed the bowel lumen. **(Gi236)**

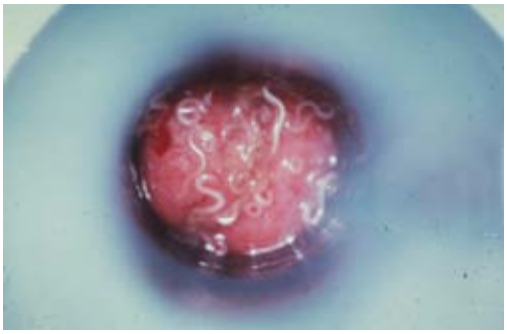

53. Trichuriasis
Note the thread-like worms attached to the bowel mucosa. Rectal prolapse is common. **(Gi237)**

54. Strongyloidiasis
Note the adult worms

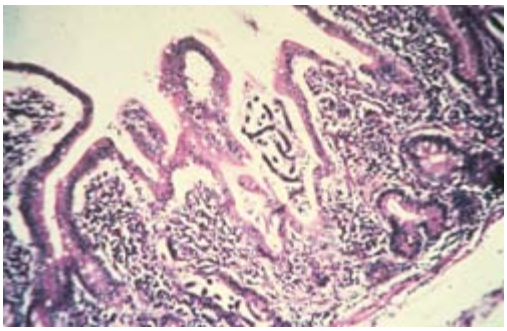

embedded in the bowel mucosa. **(Gi239)**

55. Enterobiasis (pinworm)
Note the characteristic embryonated egg with a flat side. **(Gi240)**

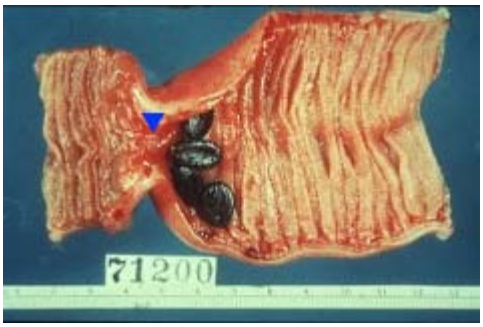

56. Bowel adhesion
Note the constriction in the wall of the bowel which has trapped several seeds. Obstruction in the bowel is most often due to adhesions post surgery. **(Gi045)**

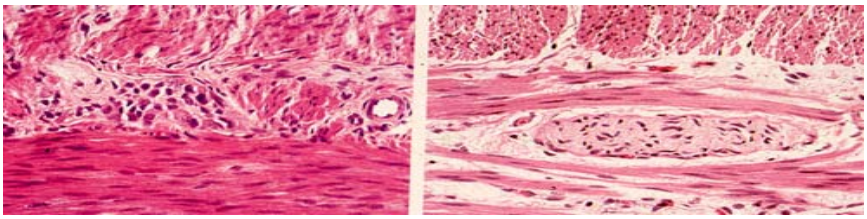

57. Hirschsprung's disease
The frame on your left depicts ganglion cells and the one on your right the absence of ganglion cells in the rectosigmoid. **(Gi243)**

58. Volvulus
Note how the colon is twisted around the mesentery. **(Gi246)**

59. Schematic of intussusception
Note how the terminal ileum has intussuscepted into the cecum. **(Gi244)**

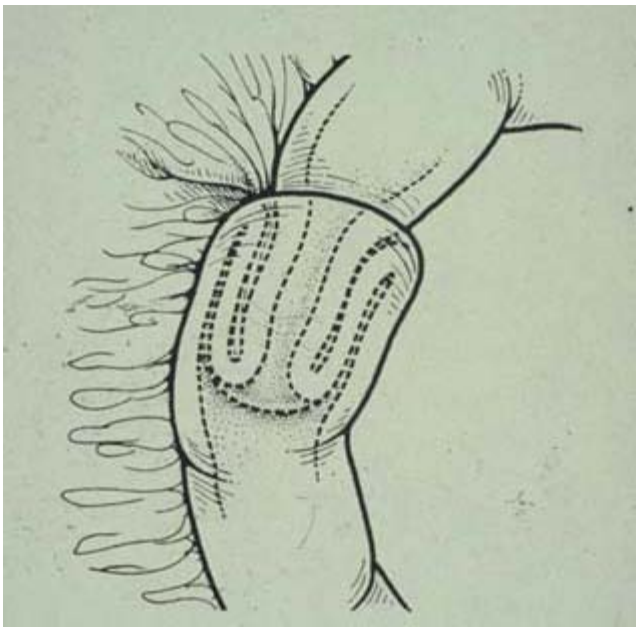

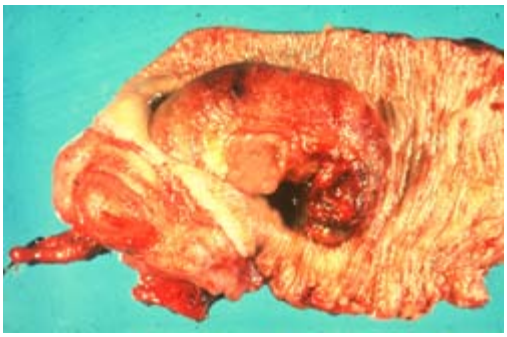

60. Intussusception
The sausage shaped mass in the lumen of the cecum is the terminal ileum **(Gi274)**

Previous | **Next**
Return to Top | **Return to Image Index**

Pathology I Images

Gastrointestinal

It is against copyright laws to make
electronic or printed copies of these slides!!

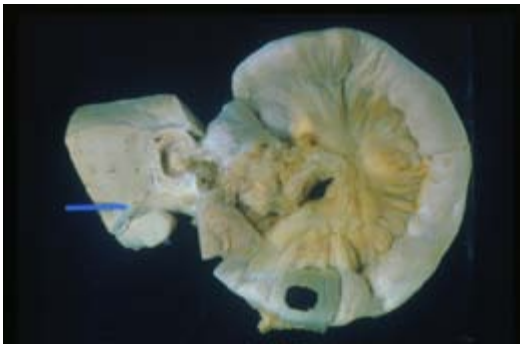

61. Gallstone ileus
A chunk of liver and thickened gallbladder is on the left. There is an opening between the gallbladder and the small bowel lumen. The black stone used to be in the gallbladder but passed through the fistula and is now in the small intestine lumen. Air would be present in the biliary tree. **(Gi245)**

62. Radiograph with the air fluid levels and step-ladder effect of a small bowel obstruction
self explanatory **(Gi273)**

63. Crohn's disease
This slide shows a gross specimen of Crohn's disease demonstrating fissuring, serpiginous ulcers and cobblestone mucosa. **(Gi174)**

64. Crohn's disease
This slide demonstrates cobblestone change in the

mucosa of the colon. **(Gi252)**

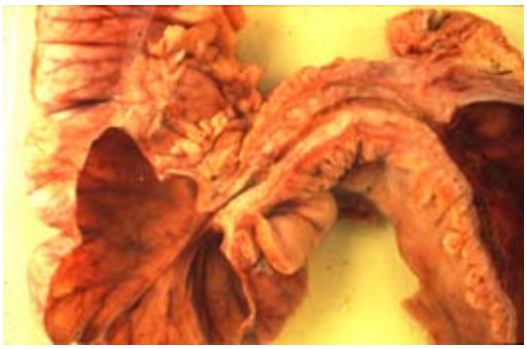

65. Crohn's disease
Note the thickened terminal ileum emptying into the cecum. The lumen is extremely narrow and would show up as a string sign on a barium enema. **(Gi279)**

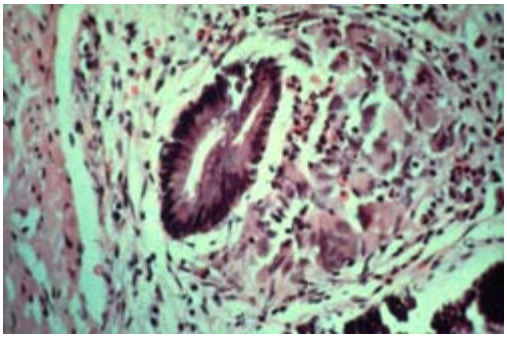

66. Crohn's disease
Note the ill-defined non-caseating granuloma to the right of the gland lumen **(Gi280)**

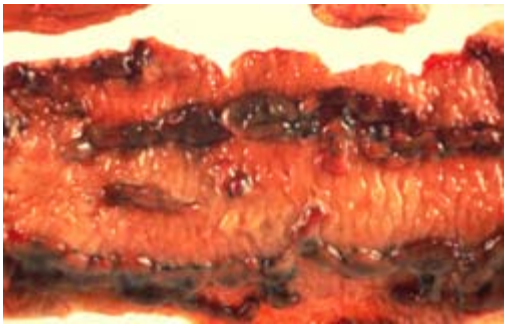

67. Ulcerative colitis
Note the islands of red, inflamed mucosa representing pseudopolyps and the gray-yellow ulcerated mucosa **(Gi281)**

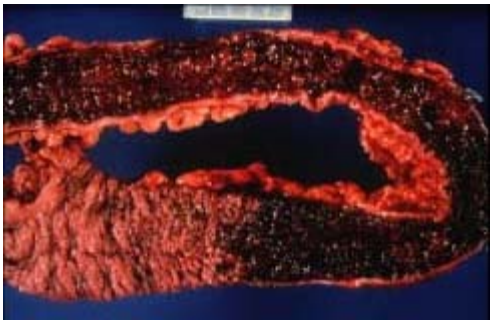

68. Ulcerative colitis
This slide is a gross specimen from a case of UC. Note the hemorrhagic ulcerated appearance of the mucosa and the continuous involvement without skip areas. **(Gi042)**

69. Ulcerative colitis
Note the crypts filled with neutrophils. **(Gi282)**

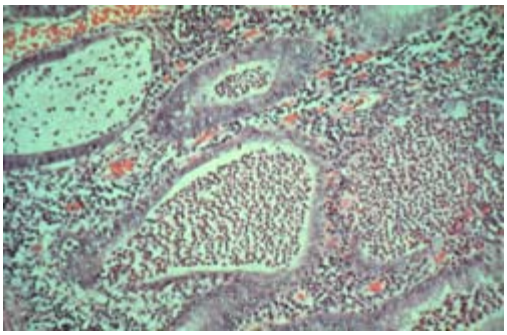

70. Infarcted small bowel
note the localized hemorrhagic infarction of the small bowel. It may have been entrapped in the external inguinal canal of an indirect inguinal hernia. **(Gi275)**

Previous | **Next**

Return to Top | **Return to Image Index**

Pathology I Images

Gastrointestinal

It is against copyright laws to make *electronic or printed* copies of these slides!!

71. Ischemic stricture at splenic flexure
Note the thick wall of the bowel and narrow lumen from repeated small infarcts with repair by fibrosis. **(Gi276)**

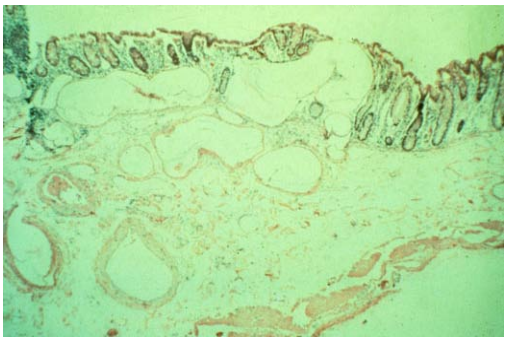

72. Angiodysplasia of cecum
Note the dilated vessels in the submucosa. One opens into the lumen at the top of the slide. **(Gi277)**

73. Diverticulosis
This gross specimen demonstrates the development of diverticuli where the artery penetrates the muscular wall of the colon. **(Gi043)**

74. Diverticulosis
This slide is a microscopic section of a diverticulum in the colon. Note that the wall of the diverticulum does no contain all layers of the colon wall, which makes it a false diverticulum. **(Gi044)**

75. Barium enema with diverticulosis
Note the numerous outpouchings.

(Gi278)

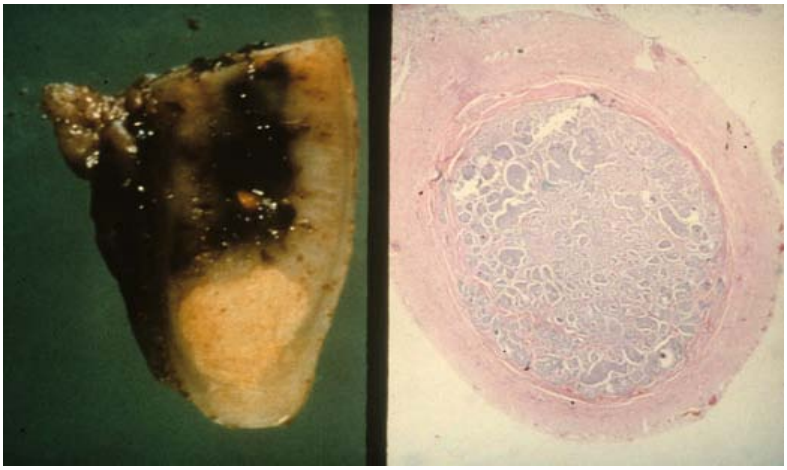

76. Carcinoid tumor
This slide shows a gross and microscopic section of an appendiceal carcinoid tumor. The photograph on the left shows the tail of the appendix with the carcinoid tumor at the tip. The slide on the right shows a cross-section of the well demarcated tumor. Most carcinoid tumors in the appendix are asymptomatic. **(Gi046)**

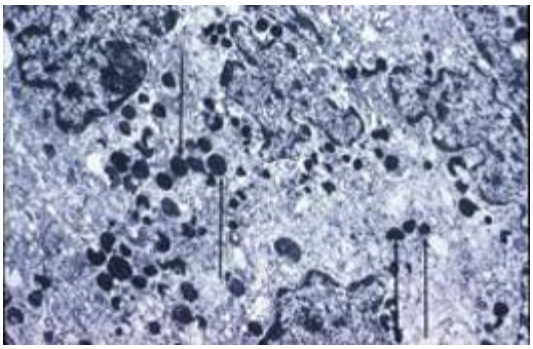

77. Carcinoid tumor-neurosecretory granules
The arrows point to dark staining cytoplasmic organelles which are features of neuroendocrine tumors. **(Neo071)**

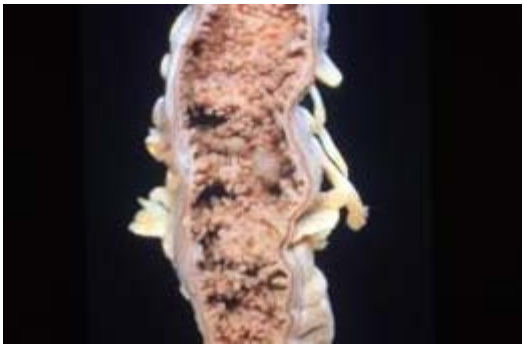

78. Familial polyposis
This autosomal dominant condition is associated with multiple tubular adenomas and tubulovillous tumors in the colon. The patient has greater than 100 polyps and is at risk for colon cancer. There is an association with the APC tumor suppressor gene. **(Neo072)**

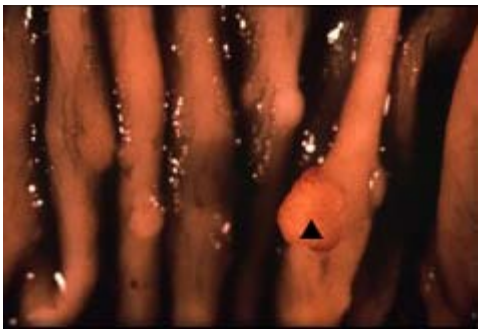

79. Hyperplastic polyps
This slide also shows multiple hyperplastic polyps, most being sessile (without a stalk). **(Gi48)**

80. Juvenile polyp

This is a hamartomatous polyp which is solitary and occurs mostly in the rectum. Juvenile polyps readily undergo torsion and present with rectal bleeding. They also frequently self-amputate. **(Gi049)**

Previous | **Next**

Return to Top | **Return to Image Index**

Pathology I Images

Gastrointestinal

It is against copyright laws to make *electronic or printed* copies of these slides!!

81. Tubular adenoma
There are four slides demonstrating a tubular adenoma. The slide on the upper left is an endoscopic view of the pedunculated tumor. A barium outlines the polyp. The last two slides show the pedunculated polyp. There is a slight risk of malignant transformation with tubular adenomas. **(Neo073)**

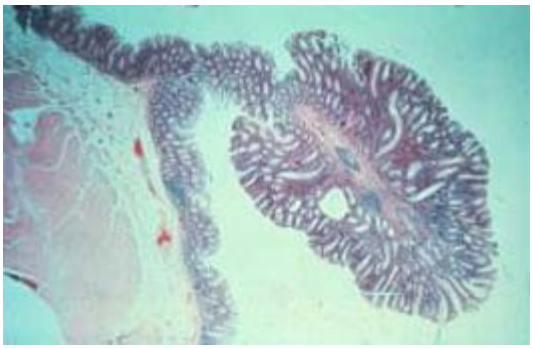

82. Tubular adenoma
This is a microscopic section of a neoplastic polyp arising from the colon mucosa. The polyp is pedunculated and is composed of colonic glands which have lost many of the normal goblet cells. This is called an adenomatous change. **(Neo003)**

83. Villous adenoma
This slide demonstrates the velvety appearance of a villous adenoma of the colon.
(Gi051)

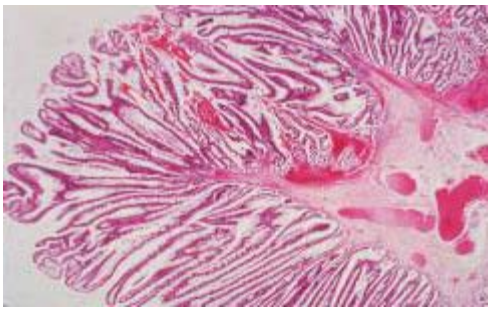

84. Villous adenoma
This is a microscopic section of a villous adenoma. Note the long stalk-like papillary projections of the tumor. These tumors are typically sessile and have a high incidence of malignant transformation. **(Neo074)**

85. Adenocarcinoma of colon
This tumor is a fungating mass with central necrosis which arises from colonic mucosa. It

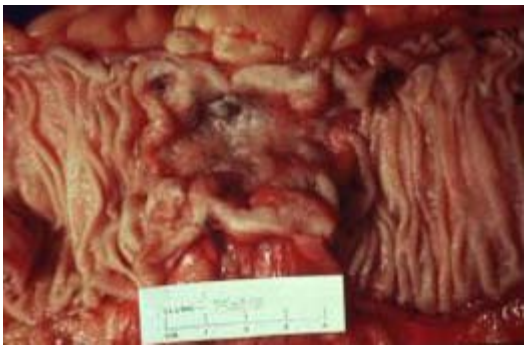

tends to infiltrate the wall of the colon in a "napkin-ring" fashion producing obstruction. Obstructive lesions occur in the descending colon. **(Neo075)**

86. Adenocarcinoma of the colon
This lesion is growing as a polypoid mass into the lumen of the ascending colon. Right sided colonic masses typically present with anemia and bleeding. **(Neo076)**

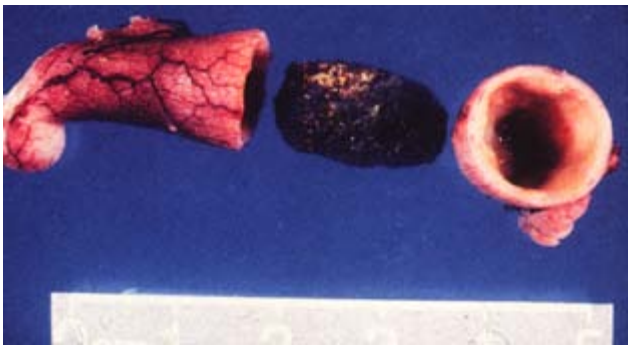

87. Acute appendicitis with fecalith
Fecaliths are more commonly associated with adult rather than childhood appendicitis, which is more often secondary to a viral infection (measles, adenovirus). **(Gi285)**

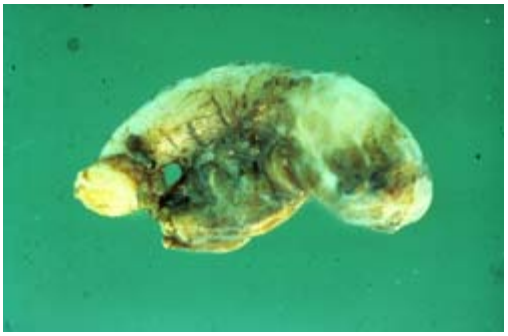

88. Acute appendicitis
Note the purulent material covering the surface of the appendix. **(Gi284)**

Previous | Next
Return to Top | Return to Image Index

Pathology I Images

Hepatobiliary

It is against copyright laws to make *electronic or printed* copies of these slides!!

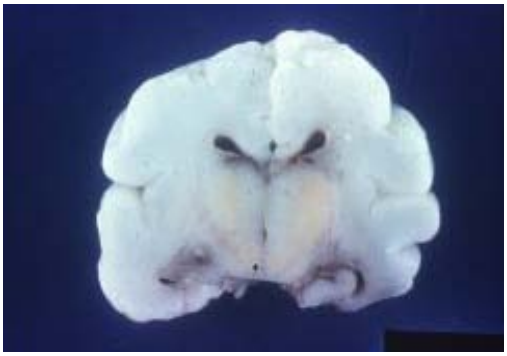

1. Kernicterus
Note the yellowish discoloratioin representing free UCB (not bound to albumin) in the brain. The child had Rh incompatibility. **(Hep001)**

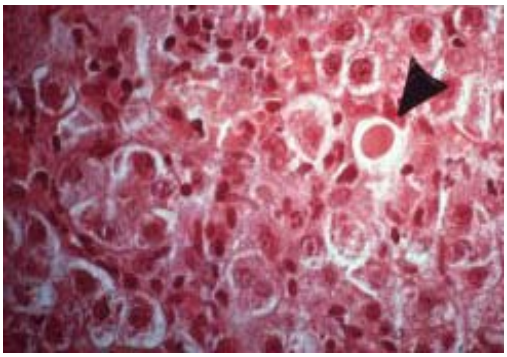

2. Viral hepatitis with Councilman body (apoptosis)
Note the deeply eosinophilic, anucleate hepatocyte that has undergone apoptosis (individual cell death). The cord-sinusoid-cord pattern of the liver is disrupted by regenerating hepatocytes. **(Hep002)**

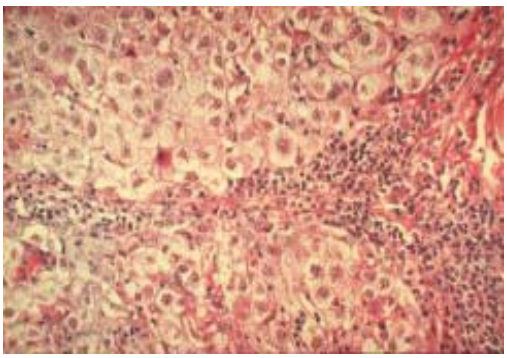

3. Viral hepatitis with bridging necrosis
Note the round cell infiltrate that streams out from a portal triad. This is called bridging necrosis and will likely end up as bridging fibrosis, which is a band histologic sign (chronic hepatitis). The infiltrate in viral hepatitis is lymphocytic (cytotoxic T cells), while in alcoholic hepatitis it is neutrophilic. **(Hep003)**

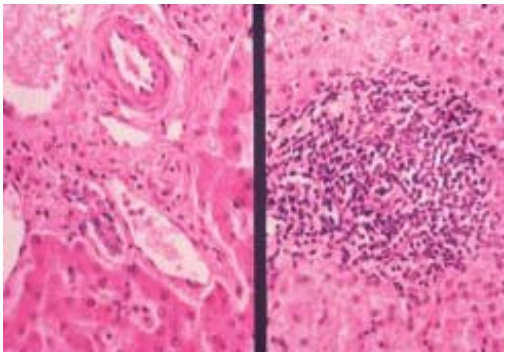

4. Chronic persistent viral hepatitis with a portal "triaditis"
Note the frame on the left with the well circumscribed infiltrate of lymphocytes in the triad. The limiting plate separating the triad from the parenchyma is intact and no inflammation is noted in the parenchyma. CPH due to chronic HBV corresponds with a "healthy carrier" state and usually subsides with reappearance of anti-HBs antibodies. **(Hep004)**

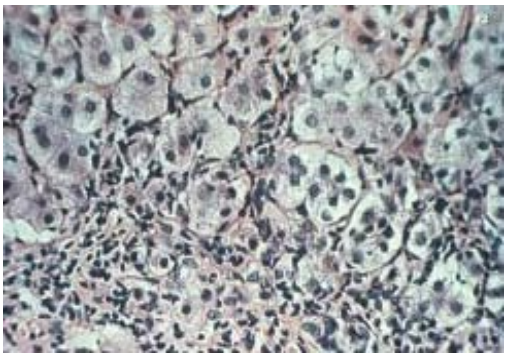

5. High power of the limiting plate of a patient with chronic aggressive (active) hepatitis B
Note that the lymphocytic infiltrate obscures the line of demarcation between triad (top) and parenchyma (bottom). This is a bad sign and is usually associated with the infected carrier state and a greater chance for progression into postnecrotic cirrhosis. **(Hep005)**

6. Multiple liver abscesses
Note the shaggy craters (liquefactive necrosis) and pus in some of the cavities. **(Hep008)**

7. Nutmeg in cross-section
Note the similarity of a real nutmeg to a nutmeg liver. **(Hep014)**

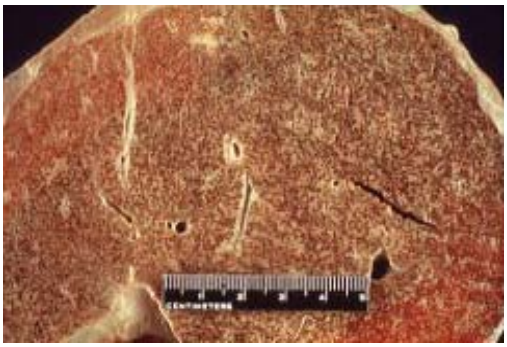

8. Congestive hepatomegaly ("nutmeg liver"): The red dots represent congested terminal hepatic venules. Right heart failure is the most common cause. **(Hep015)**

9. Hydatid cyst in the liver.
Note the grape-like hydatids associated with *Echinococcus granulosis.* **(Hep018)**

10. *Entamoeba histolytica*
Note the trophozoites with erythrophagocytosis, a pathognomonic finding with this protozoal disease. **(Hep019)**

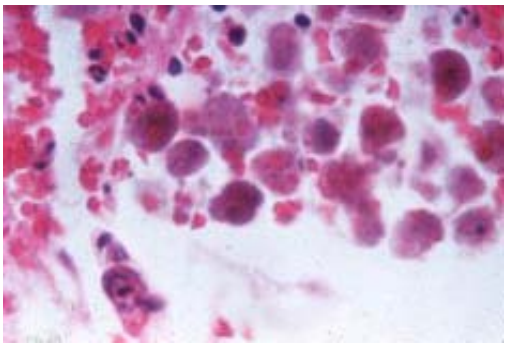

Previous | Next

Return to Top | Return to Image Index

Pathology I Images

Hepatobiliary

It is against copyright laws to make *electronic or printed* copies of these slides!!

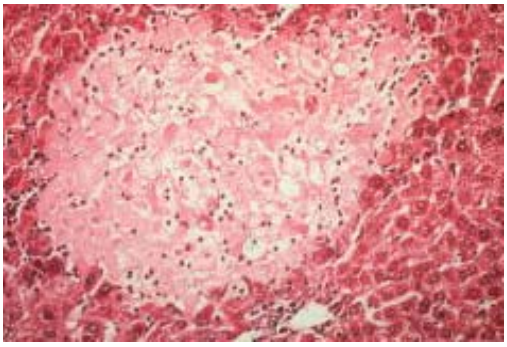

11. Liver infarction (microscopic)
Note the outlines of dead hepatocytes indicating classic coagulation necrosis. It is likely that students could mistake this for a granuloma. **(Hep021)**

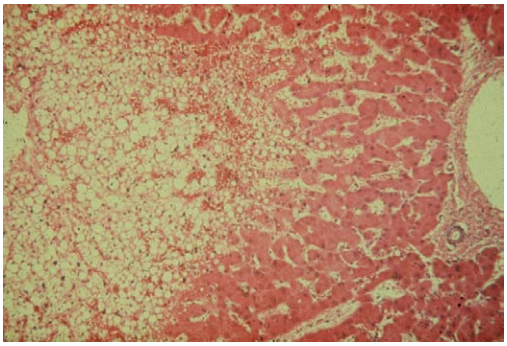

12. Fatty change in the liver (microscopic) The triad is to the right and the THV surrounded by fatty change (zone III) to the left. Since zone III has the least amount of oxygenated blood (blood flows from the triad to the THV), hepatocytes in this zone are most likely susceptible to hypoxia, alcohol, and other toxic insults. **(Hep023)**

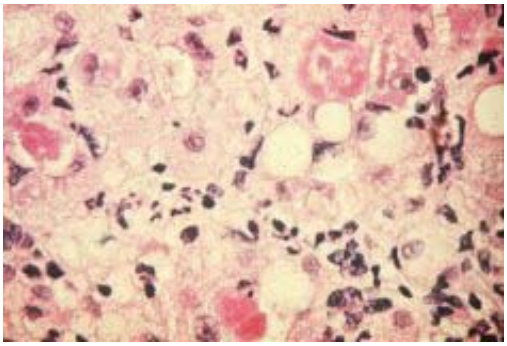

13. Alcoholic hepatitis
Note the blotchy eosinophilic staining Mallory bodies at 2-, 6-, and 10 o'clock. The clear spaces are fatty change and the infiltrate is neutrophils. **(Hep024)**

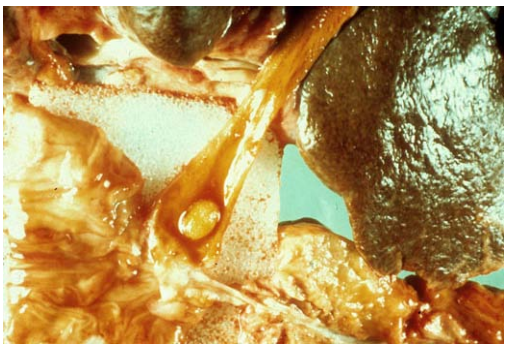

14. Stone in the common bile duct and extrahepatic cholestasis
Note the round yellow stone blocking the CBD (sponge is pushing it up) before it empties into the duodenum. The duct is dilated and the liver is green, indicating complete obstruction. Hyperbilirubinemia would primarily be due to CB and the stools would be clay colored. **(Hep026)**

15. Cross-section of the above liver

Note the mottled dark green appearance of the liver parenchyma. **(Hep027)**

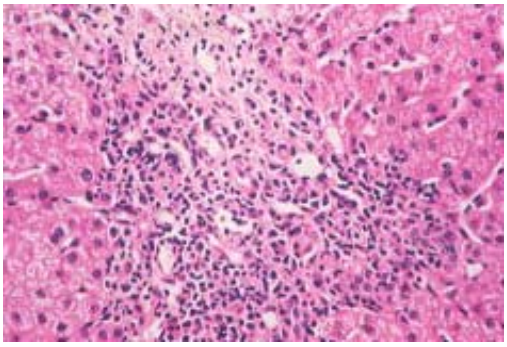

16. Primary biliary cirrhosis
Note the round cell infiltrate in the triad. The limiting plate is destroyed. This is stage 2, where there is bile duct proliferation. Eventually the ducts will be destroyed and jaundice will become evident in the patient. **(Hep030)**

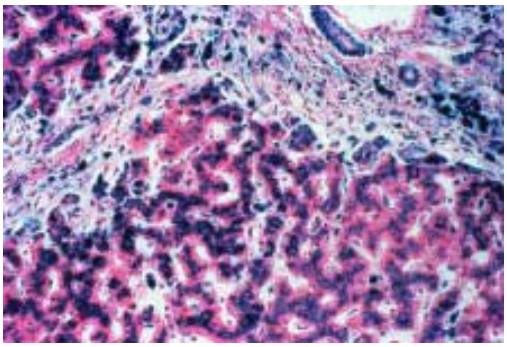

17. Prussian blue stain of a liver in a patient with hemochromatosis
Note the abundant blue staining iron deposited in the hepatocytes, Kupffer cells, and in the fibrous bands surrounding micronodules of regenerating liver (micronodular cirrhosis). **(Hep031)**

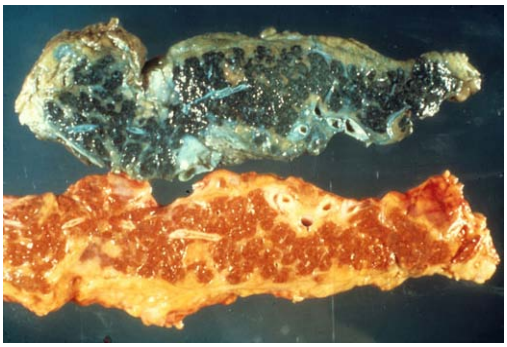

18. Prussian blue stain of pancreas and unstained pancreas in a patient with hemochromatosis
Note the intense blue staining of the pancreas and the abundant amount of fibrous tissue replacement of the gland. Exocrine deficiency occurs before endocrine deficiency. **(Hep032)**

19. Hyperpigmented patient with hemochromatosis
Note the brownish discoloration of the skin secondary to melanocyte stimulation by iron and iron itself deposited in the dermis. **(Hep033)**

20. Kayser-Fleischer ring in Wilson's disease
Note the copper colored rim around the outside of the eye. **(Hep034)**

Previous | Next
Return to Top | Return to Image Index

Pathology I Images

Hepatobiliary

It is against copyright laws to make *electronic or printed* copies of these slides!!

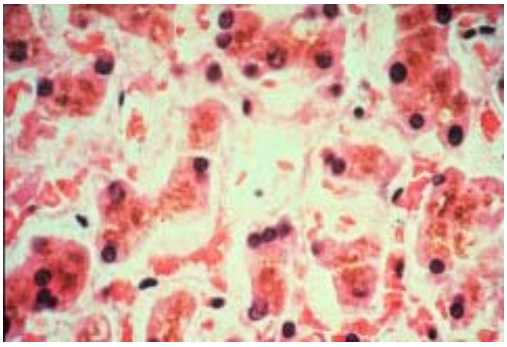

21. Lipofuscin pigment in the liver.
Note the brown colored pigment in the hepatocytes representing undigestible lipid. Special stains would have to be performed to rule out other pigments before this could be called lipofuscin. **(Hep037)**

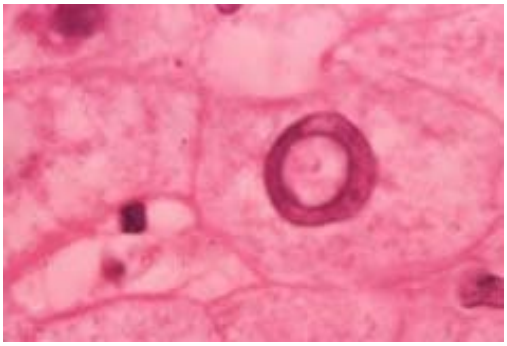

22. Intranuclear deposition of glycogen in the hepatocyte:
The material would be PAS positive. **(Hep038)**

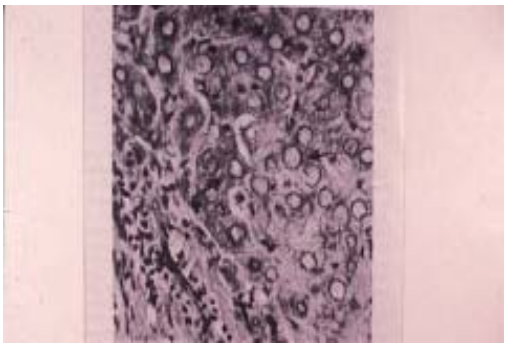

23. Diffuse intranuclear deposition of glycogen in hepatocytes (Hep039)

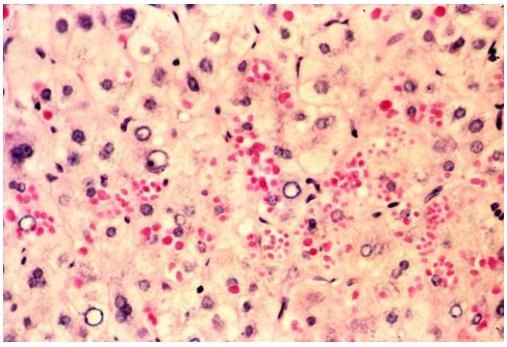

24. Globules of PAS positive AAT in a liver from a child with neonatal cholestasis secondary to AAT deficiency (Hep040)

25. EM showing mitochondrial swelling in the hepatocytes of a child with Reye's syndrome

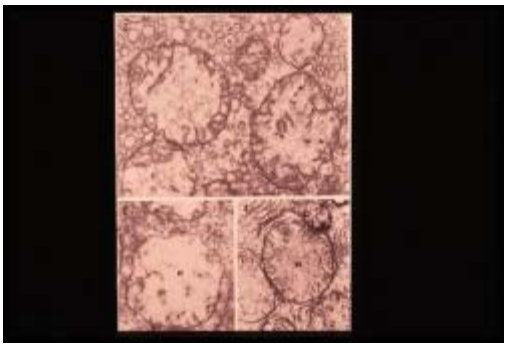

(Hep043)

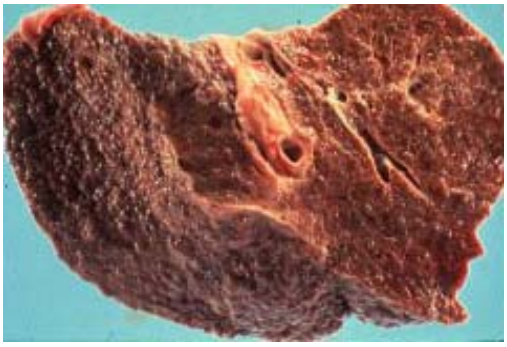

26. Mixed micro- and macronodular alcoholic cirrhosis
Note the diffuse nature of the disease and the regenerative nodules. **(Hep044)**

27. Close-up of postnecrotic (macronodular) cirrhosis in a patient with chronic HBV (Hep045)

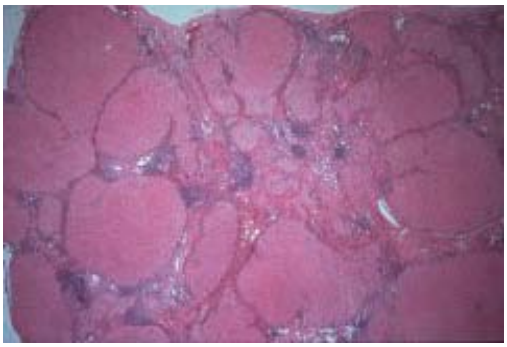

28. Histologic section of a mixed micro-, macronodular cirrhosis
Note the thin bands of fibrosis and inflammation. **(Hep046)**

29. Esophageal varices
Note the dilated veins in the submucosa and areas of hemorrhage. **(Hep047)**

30. Jaundiced patient with fulminant hepatic failure. (Hep048)

Previous | Next
Return to Top | Return to Image Index

Pathology I Images

Hepatobiliary

It is against copyright laws to make *electronic or printed* copies of these slides!!

31. Gynecomastia in the right breast of a patient with alcoholic cirrhosis. (Hep049)

32. Palmar erythema (hyperestrinism) in a male with cirrhosis of the liver. (Hep050)

33. Close-up of a spider angioma in a male with cirrhosis of the liver
These are AV fistulas and will disappear when the central portion of the lesion is compressed. **(Hep051)**

34. Feminized male with cirrhosis
Note bilateral gynecomastia and the female distribution of pubic hair. **(Hep052)**

35. Glossitis (folate deficiency) and Dupuytren's contracture in an alcoholic

Dupuytren's contractures are a fibromatosis of the palmar tendon sheath with subsequent contraction of the fingers. It is commonly seen in alcoholics. **(Hep054)**

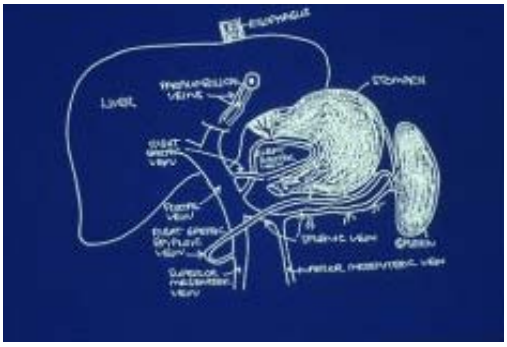

36. Schematic of the portal vein system. (Hep055)

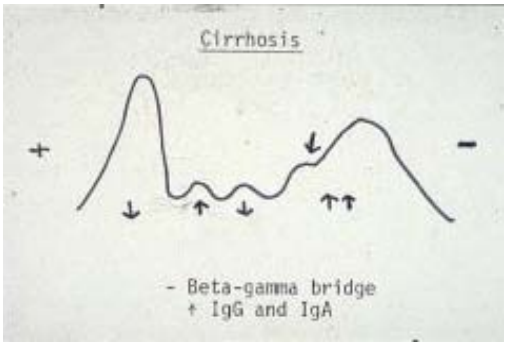

37. Serum protein electrophoresis with a b-g-globulin bridge in a patient with alcoholic cirrhosis
Alcoholics have an increase in IgA and IgG. IgA migrates at the junction of the b-g peaks, hence filling in the valley between the two peaks. Note the diffuse elevation of the g-globulin region from the increase in IgA. This pattern is pathognomonic for alcoholic cirrhosis. **(Hep056)**

38. Endoscopy showing metastatic tumor nodules on the liver surface. (Hep057)

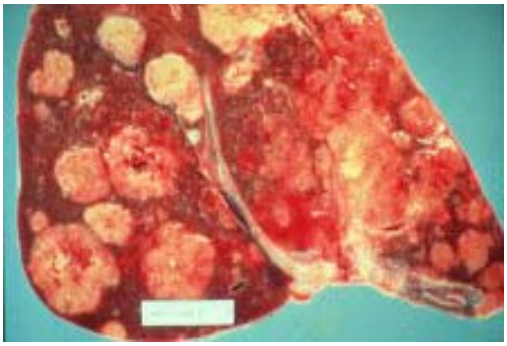

39. Liver with multiple metastatic nodules. (Hep058)

40. Micronodular cirrhosis with hepatocellular carcinoma
Note the large mass at one corner of the liver. This underscores the relationship of a background of cirrhosis in the development of hepatocellular

carcinoma. **(Hep059)**

Previous | **Next**
Return to Top | **Return to Image Index**

Pathology I Images

Hepatobiliary

It is against copyright laws to make *electronic or printed* copies of these slides!!

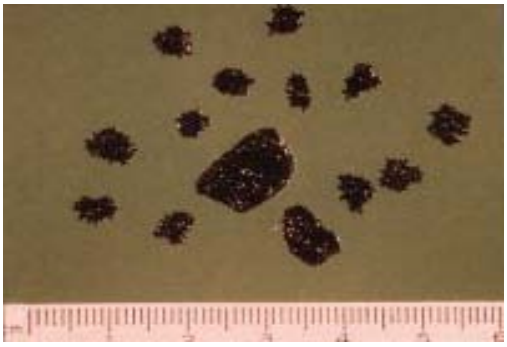

41. Jet black calcium bilirubinate stones in a patient with an extravascular hemolytic anemia (Hep064)

42. Ultrasound showing a single stone in the gallbladder (white arrows) (Hep065)

43. Chronic cholecystitis with a thick wall and a lumen containing yellow cholesterol stones. (Hep066)

44. Gallbladder cancer
Note the white sheets of tumor and metastasis to the cystic duct lymph node (cut in half). Gallstones are present. **(Hep067)**

45. CT scan showing a porcelain gallbladder
This is dystrophic calcification of a chronically

inflamed gallbladder. It predisposes to gallbladder cancer and is always electively removed. **(Hep068)**

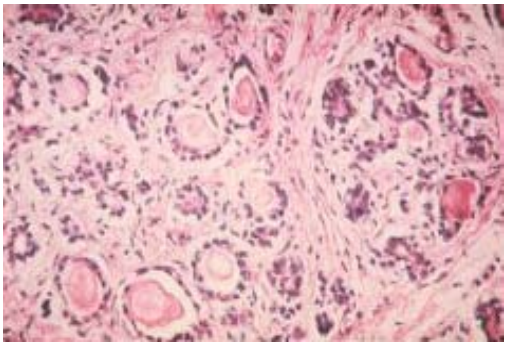

46. Pancreas in a patient with cystic fibrosis. Note the dilated ducts filled with pink material. The surrounding parenchyma is fibrotic. **(Hep069)**

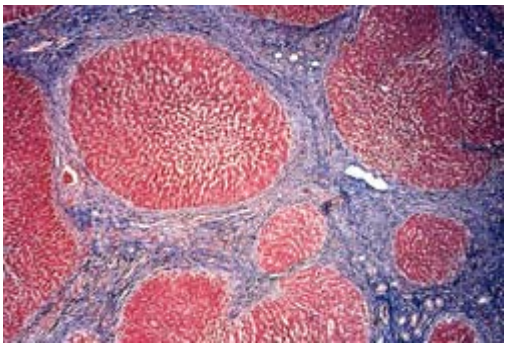

47. Trichome stain showing bridges of collagen connecting one triad with the next in a patient with cystic fibrosis and secondary biliary cirrhosis. (Hep070)

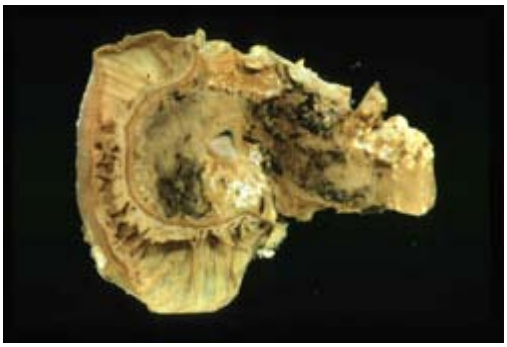

48. Acute pancreatitis
Note the duodenum and the hemorrhagic pancreas with focal chalky white areas representing enzymatic fat necrosis. The duodenum juxtaposed to this inflamed pancreas would likely have lacked peristalsis and would dilate with air producing a classic sentinel loop on a x-ray. Sentinel loops occur wherever there is localized inflammation in the bowel (e.g., pancreatitis, retrocecal appendicitis). **(Hep071)**

49. Hemorrhage into the flanks (Gray-Turner sign) in a patient with hemorrhagic pancreatitis. (Hep072)

50. Stippled calcification (dystrophic) in the pancreas in a patient with chronic pancreatitis. (Hep073)

Previous | Next
Return to Top | Return to Image Index

Pathology I Images

Hepatobiliary

It is against copyright laws to make *electronic or printed* copies of these slides!!

51. Carcinoma of the head of pancreas with local invasion of the duodenal wall. (Hep074)

52. Carcinoma of the head or pancreas with local invasion of the duodenal wall. (Hep075)

53. Dilated and inflamed veins representing Trousseau's superficial migratory thrombophlebitis in a patient with pancreatic cancer. (Hep076)

Previous | Next

Return to Top | Return to Image Index

Pathology II Images

Renal

It is against copyright laws to make *electronic or printed* copies of these slides!!

1. Horseshoe kidney
This specimen shows fusion of the lower poles of the kidney. Note that the kidney is trapped by the inferior mesenteric artery. Patients are also predisposed for infections and stone formation. This syndrome is associated with Turner's syndrome. Notice also the large cystic structure at the upper portion of the specimen. This is a simple retention cyst. **(Ren265)**

2. Autosomal recessive polycystic renal disease
This is an autopsy from an infant with bilateral markedly enlarged cystic kidneys. This is a very common cause of a palpable abdominal mass in a newborn and the kidneys may reach such a large size that it may impede delivery of the infant. It is incompatible with life. Mothers have oligohydramnios. **(Ren005)**

3. Potter's facies
This infant has low set ears, beak-like nose, and a receding chin. This syndrome is associated with bilateral autosomal recessive polycystic renal disease, renal dysplasia and renal agenesis. **(Ren001)**

4. CT scan of kidneys in adult polycystic kidney disease
Note the bilaterally enlarged and cystic kidneys as well as cysts in the liver. **(Ren264)**

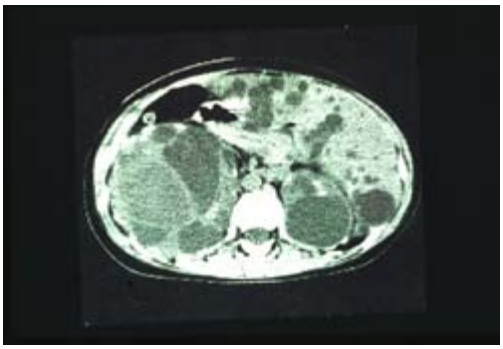

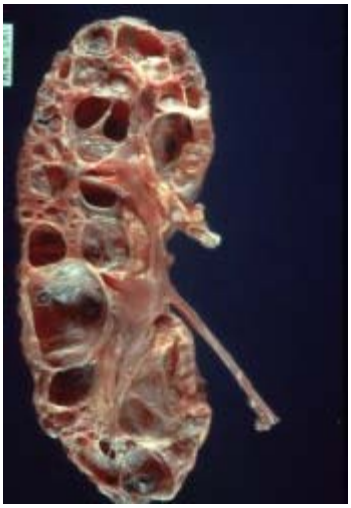

5. Autosomal dominant polycystic kidney disease (adult polycystic renal disease)
This slide is a gross specimen showing an enlarged cystic kidney. This is the most common inherited renal disease. It has an aberrant gene on the short arm of chromosome 16. Patients present in the fourth decade with hypertension and progress into renal failure within 10 years. **(Ren079)**

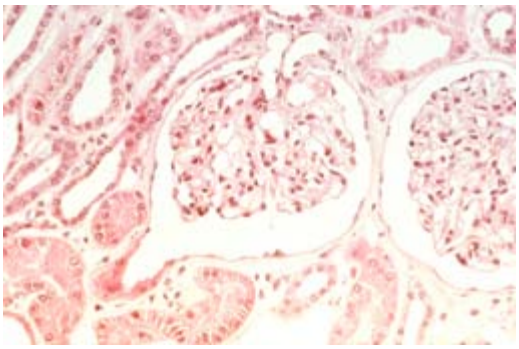

6. Normal glomerulus
This light microscopic photograph shows a normal glomerulus with the normal number of cells. Remember that within the glomerulus there are endothelial cells and visceral epithelial cells with podocytes which share the basement membrane. These are mesangial cells and a small amount of mesangila matrix in a normal glomerulus. The cells lining Bowman's space are called parietal epithelial cells. **(Ren085)**

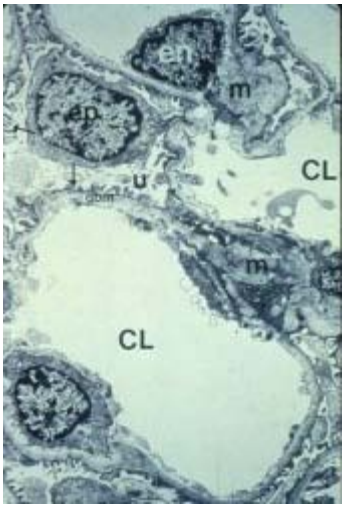

7. Normal glomerulus-electron micrograph
This slide shows 2 capillary lumens (CL) and associated endothelial cells. These are podocytes on epithelial side of the basement membrane. M designates mesangial cell. **(Ren020)**

8. Normal glomerulus-electron micrograph
This slide demonstrates podocytes or foot processes of the visceral epithelial cell on the right side of the basement membrane. Lining the basement membrane on the opposite side of the basement membrane are endothelial cell cytoplasmic extensions. **(Ren021)**

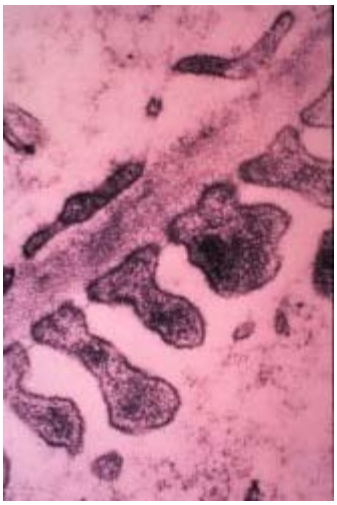

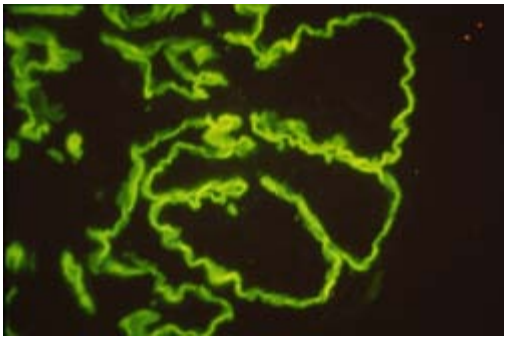

9. Linear immunofluorescence in a patient with anti-GBM antibodies
The patient has Goodpasture's syndrome. Type II hyper-sensitivity reaction. **(Ren290)**

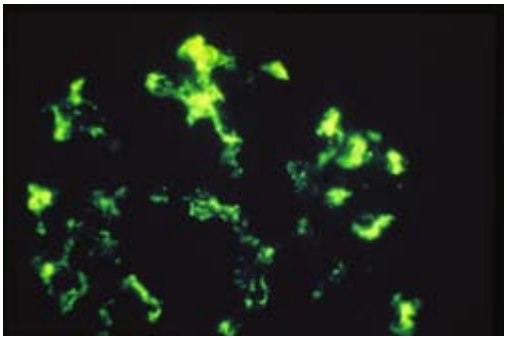

10. Lumpy bumpy (granular) immunofluorescence in immuno-complex type III glomerulonephritis. (Ren291)

Previous | Next

Return to Top | Return to Image Index

Pathology II Images

Renal

It is against copyright laws to make *electronic or printed* copies of these slides!!

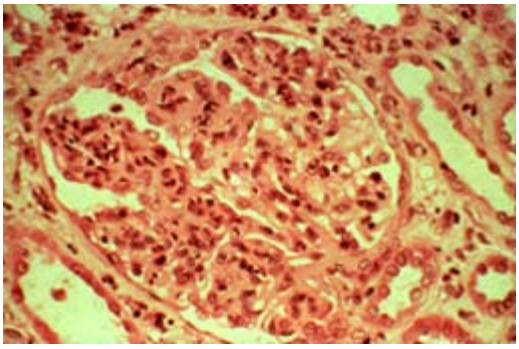

11. Acute diffuse proliferative glomerulonephritis
The glomerulus shows an increase in the number of cells (hypercellularity). The basement membranes are not thickened. This is consistent with a proliferative glomerulonephritis and it is diffuse since it involved all of the glomeruli in the renal biopsy. This biopsy is from a patient with acute post-streptococcal glomerulonephritis (nephritic syndrome). **(Ren214)**

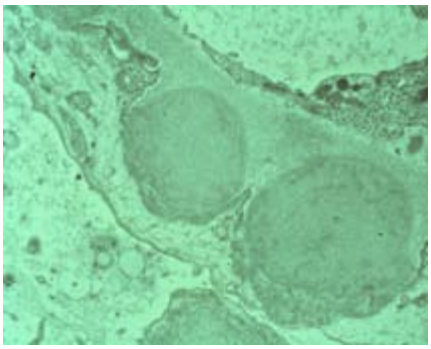

12. Acute diffuse proliferative glomerulonephritis
This is an electron micrograph which shows electron dense deposits (look like balls) on the epithelial side of the basement membrane. This is consistent with the the subepithelial deposits of acute post streptococcal glomerulonephritis. **(Ren268)**

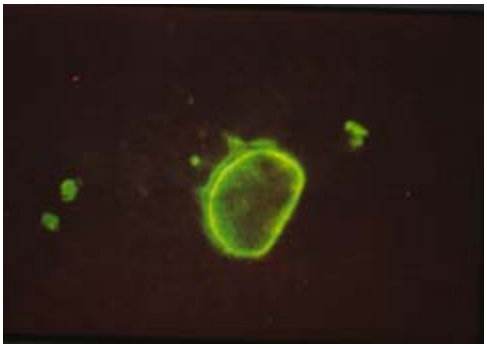

13. Immunofluorescent study (serum antinuclear antibody study)
This is a fluorescent antinuclear antibody study demonstrating a rim pattern around the nucleus in a patient with systemic lupus erythematosus. Rim patterns correlate with anti-dsDNA and the presence of acute glomerulonephritis in SLE patients. **(Ren293)**

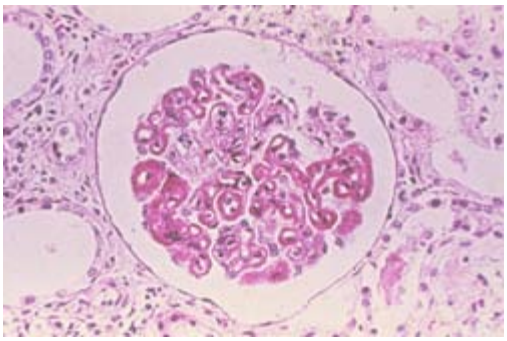

14. Systemic lupus erythematosus
This is a light microscopic section of a glomerulus with thickening of the basement membranes which is particularly prominent around capillaries. This is called wire-looping of the capillaries. The depositions are composed of circulating immune complexes of DNA plus antibodies directed against DNA which have been deposited in the subendothelial portion of the basement membrane. **(Ren292)**

15. Systemic lupus erythematosus

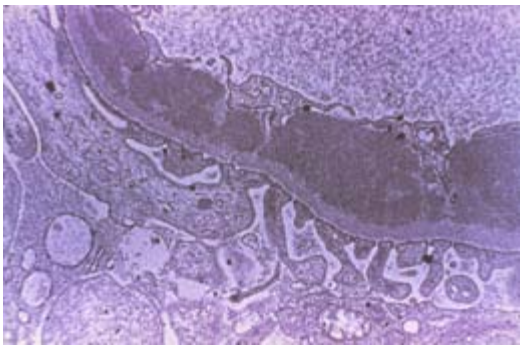

This demonstrates a subendothelial deposition of immune complexes in the basement membrane of the glomerulus. This deposition is responsible for the wire-looping pattern noted in the previous slide. **(Ren269)**

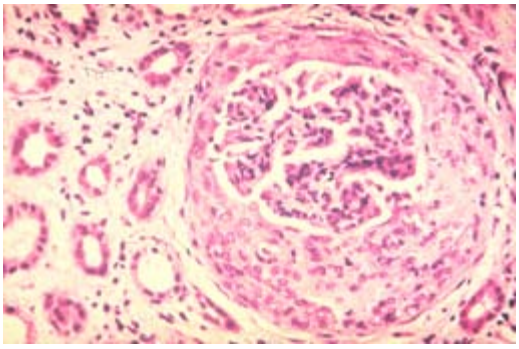

16. Rapidly progressive crescentic glomerulonephritis (nephritic)
Note the crescent shaped proliferation of parietal epithelial cells encroaching on the glomerulus. This is the worst type of glomerulonephritis and is the type associated with Goodpasture's syndrome. **(Ren270)**

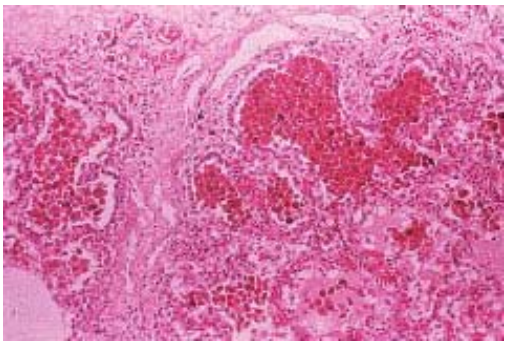

17. Goodpasture's syndrome (nephritic)
This is a section of pulmonary parenchyma showing many red blood cells collected within alveolar spaces. This type of hemorrhage is **classic** for Goodpasture's disease and produces the hemoptysis that is the first presentation in these patients prior to their developing renal disease. **(Ren080)**

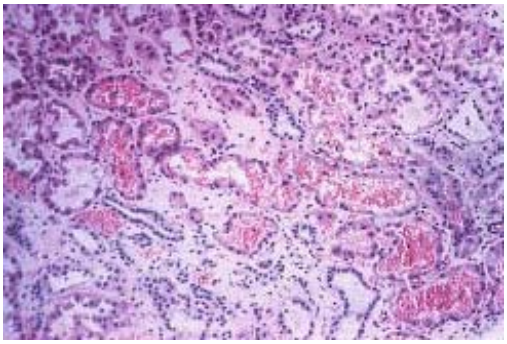

18. Goodpasture's syndrome (nephritic)
This is a section of kidney that shows many red blood cells contained within the tubules in the kidney. Most patients with Goodpasture's are young males. The pathogenesis of Goodpasture's is related to formation of antibasement membrane antibodies which are directed against glomerular and pulmonary capillary alpha-3 chains of type IV collagen in the basement membrane. Immunofluorescence shows a smooth linear pattern of IgG, C3 and fibrin. **(Ren081)**

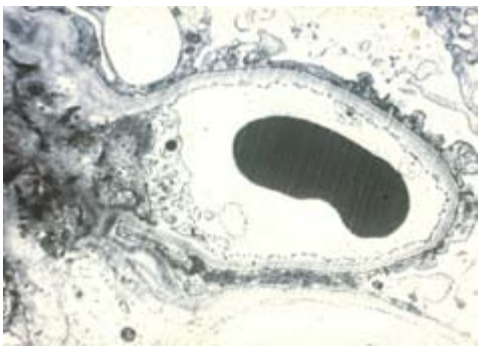

19. Lipoid nephrosis
This is an electron micrography from a case of nephrotic syndrome in a child. Note the widespread fusion of the foot processes on the epithelial side of the GBM. This is the most common cause of nephrotic syndrome in children. There is a loss of the negative charge in the GBM. **(Ren271)**

20. Focal segmental glomerulosclerosis (nephrotic)
Note how only part of the glomerulus is sclerotic. VEC's are destroyed, which destroys the GBM. This is the MC type of glomerular disease in HIV patients and intravenous drug abusers. **(Ren216)**

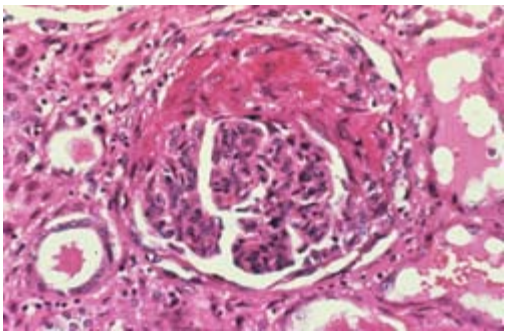

Previous | Next

Return to Top | Return to Image Index

Pathology II Images

Renal

It is against copyright laws to make *electronic or printed* copies of these slides!!

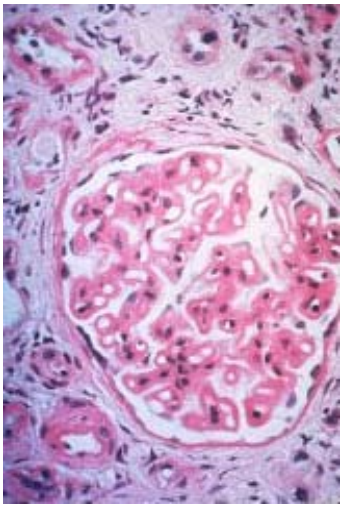

21. Membranous glomerulonephritis-nephrotic syndrome (nephrotic)
This is a light microscopic section of kidneys showing a glomerulus in the center portion of the slide. The basement membranes are thickened throughout the glomerulus. There is no evidence of hypercellularity. This is the most common cause of nephrotic syndrome in adults. **(Ren082)**

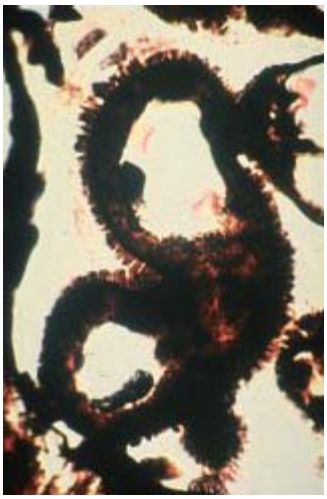

22. Membranous glomerulonephritis
This is a silver stain that demonstrates the subepithelial immunocomplex deposits characteristic of membranous GN. Note that the spikes are on the epithelial side of the basement membrane. **(Ren055)**

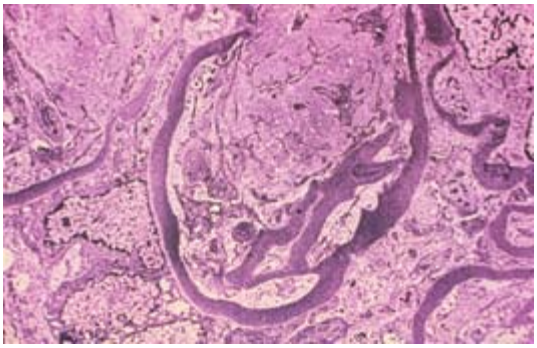

23. Electron micrograph of type II membranoproliferative glomerulonephritis (nephrotic)
This is also called dense deposit disease owing to the intramembrane deposition of the immunocomplexes. An autoantibody against C3 called the C3 nephritic factor continually activates C3, hence the very low complement levels in these patients. **(Ren274)**

24. Diabetic nephropathy (nodular glomerulosclerosis

This slide demonstrates nodular thickening of the

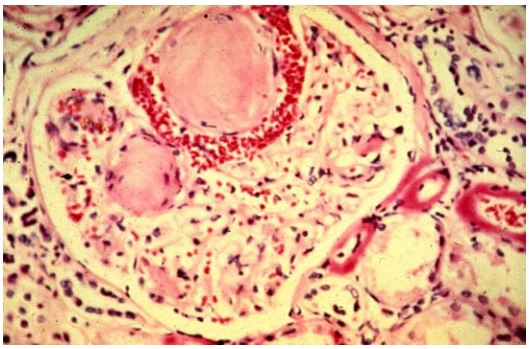

glomerular mesangium (type IV collagen). There is also hyalinization of the arteriolar wall of both afferent and efferent vessels. **(Ren275)**

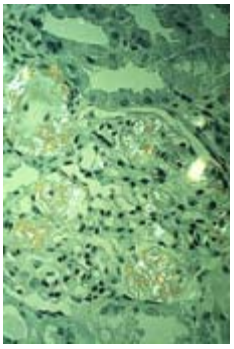

25. Renal amyloidosis-Congo red stain
This slide demonstrates the Congo red staining in a case of amyloidosis which, when polarized under the light microscope results in an apple green birefringence pattern. Amyloidosis is a reactive response associated with underlying diseases such as multiple myeloma, where the light chains are converted into amyloid. **(Ren077)**

26. Patient with chronic renal failure and uremic frost
Note the crystals representing urea that are deposited on the face of this patient. Since the kidneys cannot excrete urea, the urea is excreted in sweat. **(Ren279)**

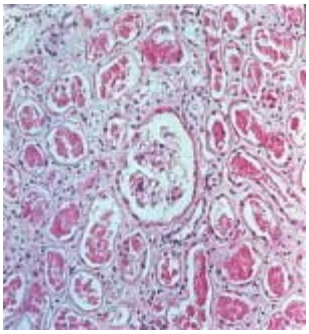

27. Acute tubular necrosis
This is a microscopic photograph of a section of kidney from a case of acute tubular necrosis demonstrating collections of necrotic tubules within tubular lumina. These pigmented renal tubular casts are the **classic** finding in acute tubular necrosis. Both forms, ischemic and nephrotoxic type, produce tubular casts. **(Ren010)**

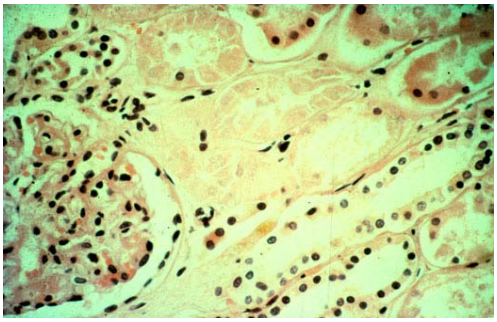

28. Acute tubular necrosis
This is another microscopic photograph of a kidney with acute ischemic tubular necrosis. Note the ghost-like outlines of many of the tubular cells (coaguation necrosis). **(Ren011)**

29. Acute pyelonephritis
This is a gross photograph of a kidney showing scattered grey-white areas representing collections of acute inflammatory cells. The pelvis is dilated, which is consistent with hydronephrosis. The most common pathogen associated with acute pyelonephritis is *E. coli.*

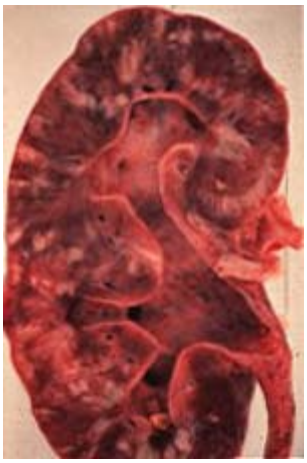

Acute PN is secondary to an ascending infection usually beginning in the bladder. Vesicoureteral reflux is the most common cause of acute pyelonephritis. **(Ren012)**

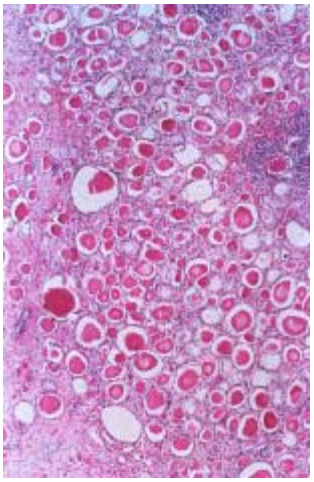

30. Chronic pyelonephritis
This slide demonstrates scattered eosinophilic protein casts in the tubular lumina. This process is again due to obstruction of the tubules. This feature is called thyroidization of the kidney because the tubules resemble thyroid acini. **(Ren017)**

Previous | **Next**

Return to Top | **Return to Image Index**

Pathology II Images

Renal

It is against copyright laws to make *electronic or printed* copies of these slides!!

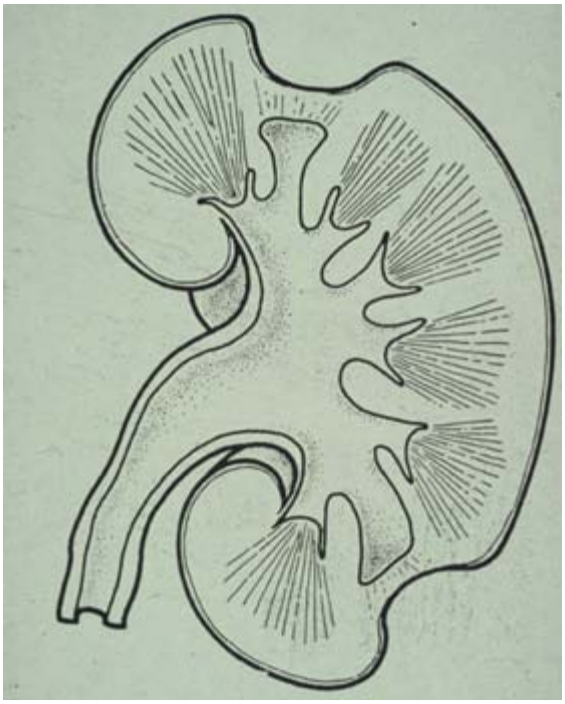

31. Chronic pyelonephritis
In chronic pyelonephritis, blunt calyces underlie cortical scars. **(Ren294)**

32. Papillary necrosis
This slide demonstrates necrosis of the renal papillae. The causes of this change include analgesic abuse, sickle cell anemia, acute pyelonephritis and diabetes. The medullary portion of the kidney is susceptible to ischemic insult because of the low oxygen tension. Note the absent papilla in the middle of the kidney. This produces a ring defect on an IVP. **(Ren018)**

33. Renal papillary necrosis
Note the necrotic renal papillae. The patient consumed large quantities of aspirin and acetaminophen for chronic pain. **(Ren070)**

34. Benign nephrosclerosis
This kidney demonstrates the fine granular change of benign nephrosclerosis, which is the most common renal disease associated with hypertension. The surface of the kidney resembles that of a football. Hyaline arteriosclerosis is the cause of the renal changes in hypertension. **(Ren280)**

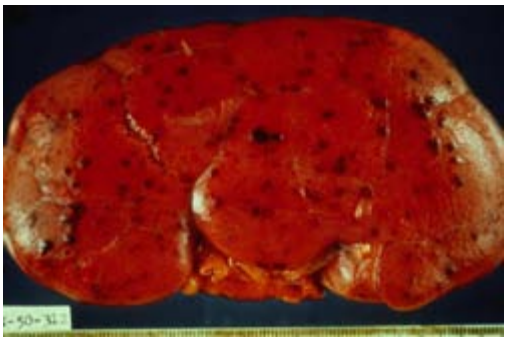

35. Malignant hypertension
This slide is a gross specimen showing multiple hemorrhages on the surface of the kidney. This is called a flea-bitten kidney and is associated with glomerular damage, glomerulitis, arteriolitis and hemorrhage in a case of malignant hypertension. **(Ren229)**

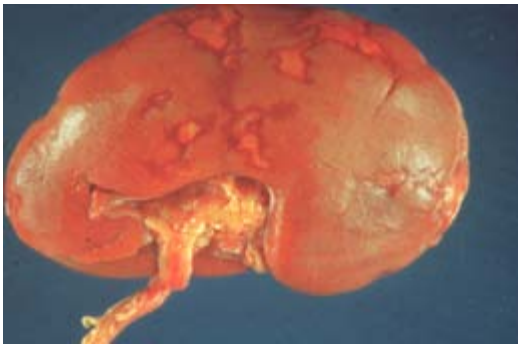

36. Multiple pale renal infarcts
Note the irregular white areas on the cortical surface. Most infarcts occur from embolic disease from the left heart. **(Ren285)**

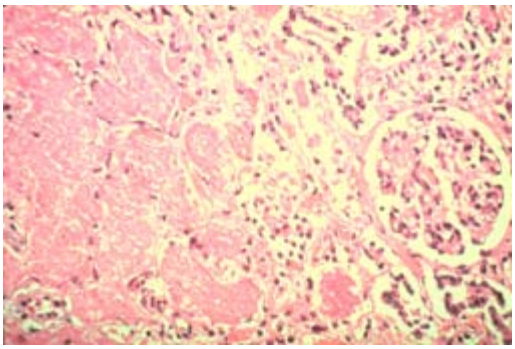

37. Renal infarction
Renal infarct with classic coagulation necrosis of tubules and glomerulus. **(Ren286)**

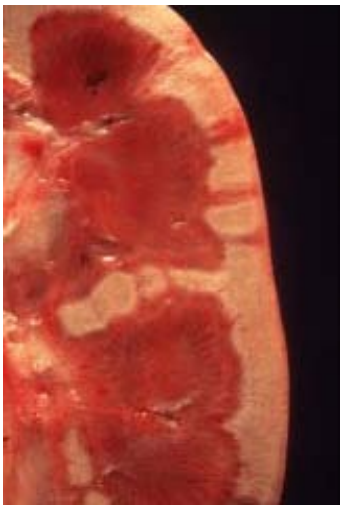

38. Diffuse cortical necrosis
This slide shows coagulation necrosis involving the cortex of the kidney. This pattern is consistent with disseminated intravascular coagulation in a patient who has been pregnant or has developed preeclampsia or eclampsia in the third trimester. **(Ren086)**

39. Hydronephrotic kidney
Note the dilated renal pelvis. Urinary stones are the MCC of hydronephrosis. **(Ren287)**

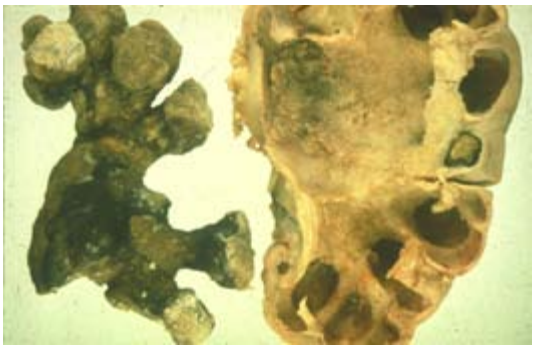

40. Staghorn calculus of the kidney
Note the large stone corresponding with the dilated renal pelvis of the kidney. The stone is composed of magnesium ammonium phosphate and is due to chronic urinary tract infections from urease producing organisms (e.g., Proteus). The urine is alkaline and smells like ammonia. Triple phosphate crystals are present in the urine. **(Ren284)**

Previous | Next

Return to Top | Return to Image Index

Pathology II Images

Renal

It is against copyright laws to make *electronic or printed* copies of these slides!!

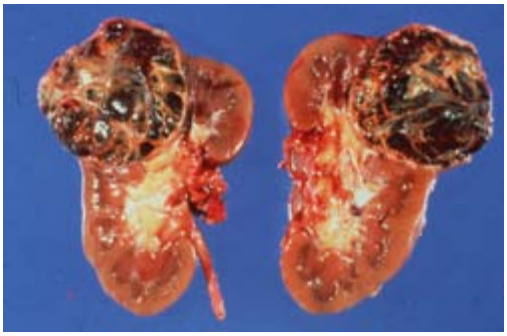

41. Renal cell carcinoma
This slide shows a renal cell carcinoma in the upper pole. This is a well demarcated cystic and hemorrhagic mass. Prognosis is related to the extent of involvement of the renal vein. The tumor has a tendency to metastasize to the lungs as cannonball metastasis. Renal cell carcinomas usually manifest in the 6th to 7th decade. They most commonly present with hematuria. They are associated with von Hippel-Lindau syndrome. Smoking is the most common cause of this cancer. **(Ren236)**

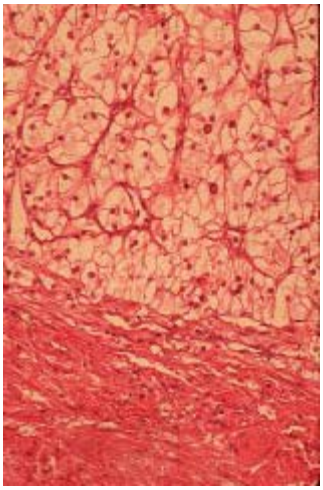

42. Renal cell carcinoma
This slide demonstrates the microscopic findings of a renal cell carcinoma. The tumor cells derived from the proximal tubule are clear and vacuolated in appearance. **(Ren039)**

43. Wilm's tumor
The kidney on the left is almost completely replaced by a yellow-white mass, representing a Wilm's tumor. Hypertension (due to renin) and a palpable flank mass are commonly present. **(Ren238)**

44. Wilm's tumor
Note the primitive mesenchyme and abortive glomerulus to the left of the slide. **(Ren239)**

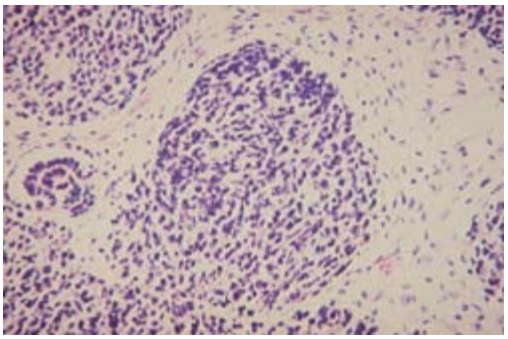

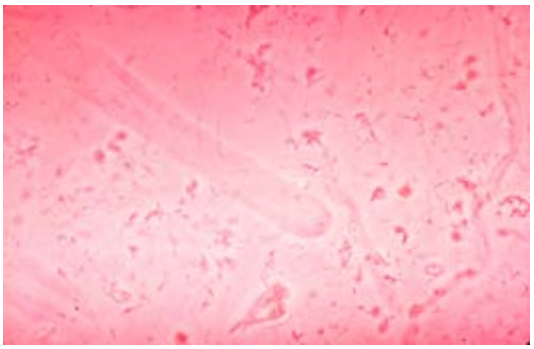

45. Hyaline cast
Note the shadowy, acellular cast with round ends
This may be a normal finding (e.g., after a viral illness) or it may be associated with proteinuria. **(Ren254)**

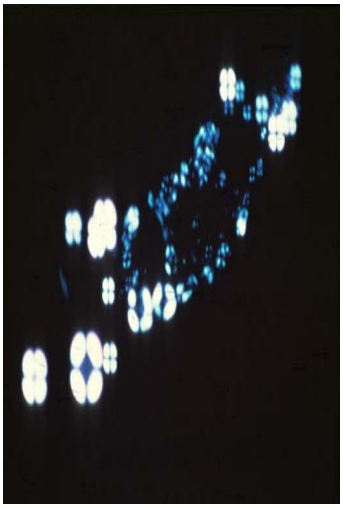

46. Maltese cross-nephrotic syndrome
This slide demonstrates a polarized specimen of urine with a cast filled with free cholesterol, which produces Maltese crosses. Fatty casts, oval fat bodies and Maltese crosses are all features of nephrotic syndrome. **(Ren043)**

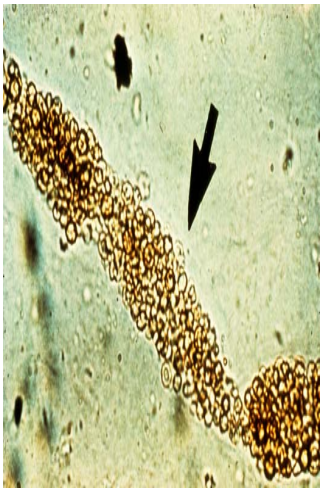

47. Red blood cell casts
This slide shows a cast filled with red blood cells. This finding is classic for a nephritic syndrome where the patient presents with hypertension, oliguria, red cell casts, red blood cells, mild to moderate proteinuria, and periorbital edema. **(Ren044)**

48. Pigmented tubular cast
A cast such as this is representative of acute tubular necrosis. The necrotic tubules which have been damaged either from ischemia or a nephrotoxin are sloughed off and form a cast. This cast appears in the urine and gives an appearance of a muddy or dirty urine because of the necrotic debris. These findings may also be accompanied

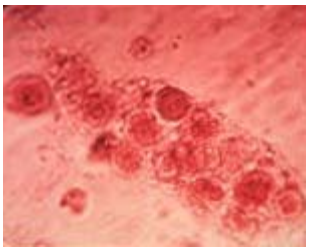

by some red blood cells or white blood cells. **(Ren045)**

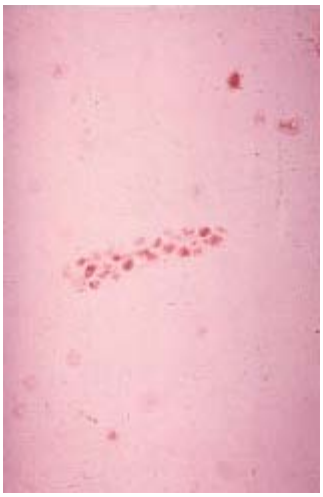

49. White blood cell casts
A white blood cell cast is a typical finding with acute pyelonephritis and acute drug-induced tubulointerstitial disease. It may be accompanied by bacteruria, scattered white blood cells, and occasionally red blood cells. The white blood cell cast separates cystitis from pyelonephritis. **(Ren046)**

50. Fatty casts
This slide shows a refractile cast which if polarized would have the appearance of the Maltese crosses. Fatty casts or oval fat bodies are associated with nephrotic syndromes because a patient typically has hypercholesterolemia. **(Ren047)**

Previous | **Next**

Return to Top | **Return to Image Index**

Pathology II Images

Renal

It is against copyright laws to make *electronic or printed* copies of these slides!!

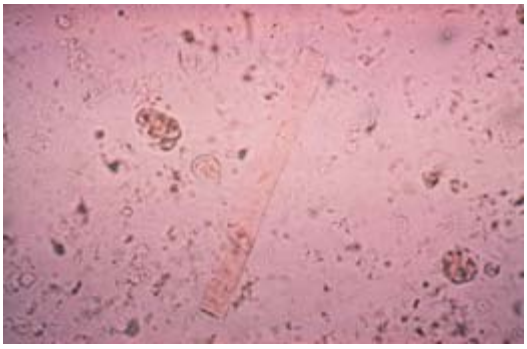

51. Waxy casts
This slide shows a pale cast with sharp margins. This represents a waxy cast. Waxy casts are the end stage of breakdown of coarse and finally granular casts and they are **classic** for chronic renal failure. **(Ren260)**

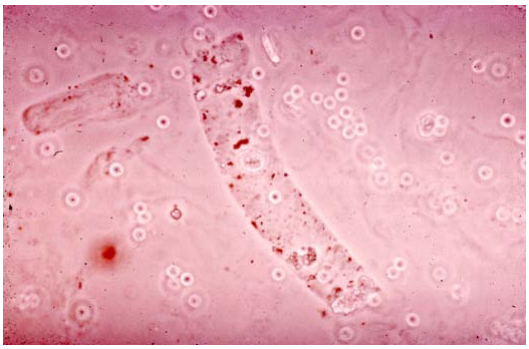

52. Broad cast in chronic renal failure
The cast is broad owing to tubular dilatation from obstruction of the lumens by casts. **(Ren261)**

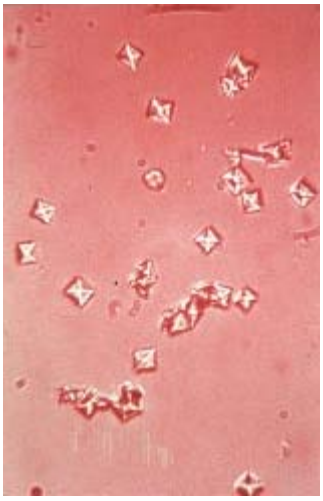

53. Calcium oxalate crystals
Calcium oxalate and/or phosphate crystals are the most common type of crystal found in the urine. They are independent of urine pH for formation. They appear like an unfolded envelope. They are associated with hypercalcemia states and commonly accompany calcium oxalate stones. Additional causes include Crohn's disease, excessive intake of vitamin C, and ethylene glycol poisoning. **(Ren050)**

54. Triple phosphate crystals
The urine sediment shows scattered rhomboid shaped crystals that resemble coffin-lids. These are the crystals of magnesium ammonium phosphate which is the substance that forms struvite or staghorn calculi. The crystals form in alkaline urine and are

associated with infections caused by *Protease spp.* **(Ren051)**

55. Uric acid crystals
This slide shows scattered stellate or star-shaped crystals which are **classic** for uric acid crystals. These crystals form in acid urine. They are seen in states where there is a high rate of turnover of cells as in leukemias or lymphomas or multiple myeloma. They can also be seen in gout. **(Ren206)**

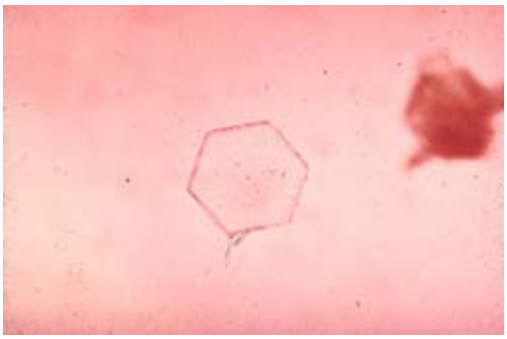

56. Cystine crystal
Note the hexagonal shape. It occurs in the AR disorder called cystinuria and can be associated with cystine stones. **(Ren263)**

57. Hematuria with dysmorphic RBCs
Note the crenated appearing RBCs. Dysmorphic RBCs indicate acute glomerulonephritis. **(Ren250)**

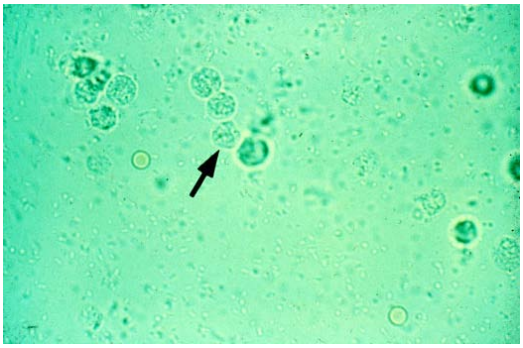

58. Classic urine sediment in a lower urinary tract infection
The arrow points to a clump of neutrophils (+ leukocyte esterase). Round, slightly red biconcave discs representing RBCs are present (+ blood). The granular material in the background represent bacteria (+ nitrite). **(Ren251)**

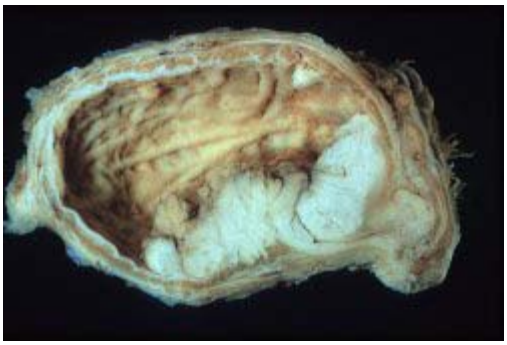

59. Transitional cell carcinoma of the bladder
This gross specimen has been opened in lognitudinal plane to show the white exophytic mass protruding into the lumen of the bladder. These tumors are typically found in the trigone of the bladder and may produce obstruction of the ureter and hydronephrosis. They are of transitional cell origin. **(Ren053)**

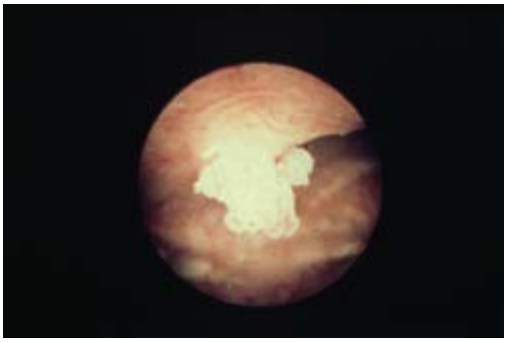

60. Transitional cell carcinoma of the bladder (cytoscopy).
Note the papillary nature of the tumor. Smoking is the MCC of TCC. **(Ren245)**

Previous | Next
Return to Top | Return to Image Index

Pathology II Images

Renal

It is against copyright laws to make *electronic or printed* copies of these slides!!

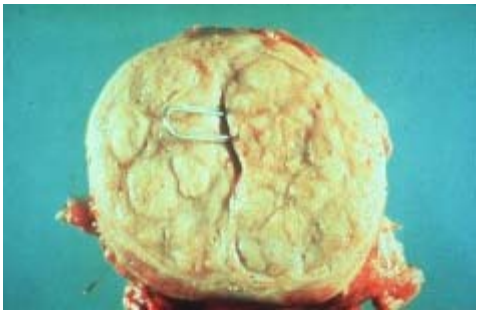

61. Nodular hyperplasia of the prostate (paper clip in urethra)
This slide shows a cross-section through the prostate gland with multiple nodules which have encroached on the prostatic urethra. This finding is associated with estrogen-enhanced sensitivity to dihydrotestosterone. The nodular areas arise in the periurethral areas, which leads to obstructive uropathy. **(Ren057)**

62. Nodular hyperplasia of the prostate, hypertrophy of the bladder, hemorrhagic cystitis
This slide shows the bladder that has been opened with extension into the prostatic urethra. The bladder mucosa shows hemorrhage which is consistent with having had an indwelling catheter. The wall of the bladder is hypertrophied. The prostate gland shows the nodularity which is characteristic of nodular hyperplasia. Small indentations are noted in the bladder mucosa representing the openings of diverticular sacs which developed from increased intravesical pressure. **(Ren058)**

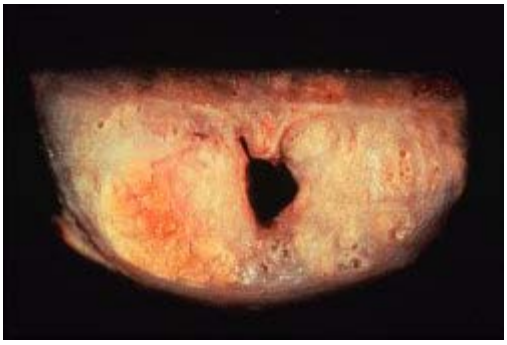

63. Carcinoma of the prostate
This slide shows the cross-section through a prostate gland with scattered foci of yellow-tan areas which represent the carcinoma. Carcinoma of the prostate arises in the posterior lobe and produces a firm or hard prostate gland on rectal exam. PSA is increased. **(Ren059)**

64. Carcinoma of the prostate
This slide is a microscopic section of a prostatic adenocarcinoma showing well-formed glands that are fairly monotonous in appearance. **(Ren060)**

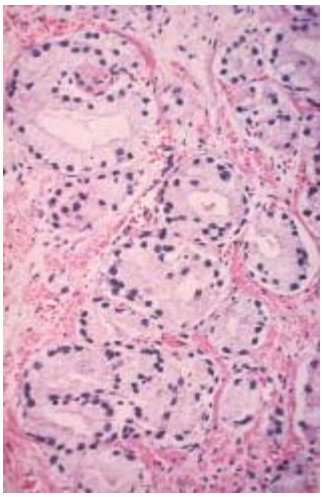

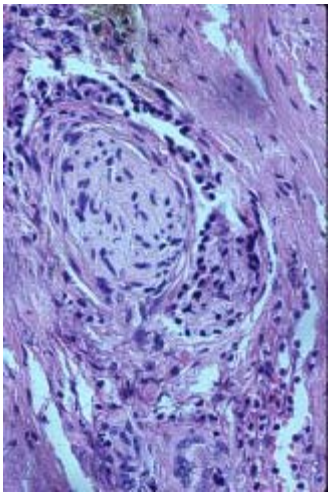

65. Adenocarcinoma of the prostate
This slide shows a nerve with perineural invasion by a carcinoma of the prostate. Notice the glandular structures in the area surrounding the nerve. **(Ren061)**

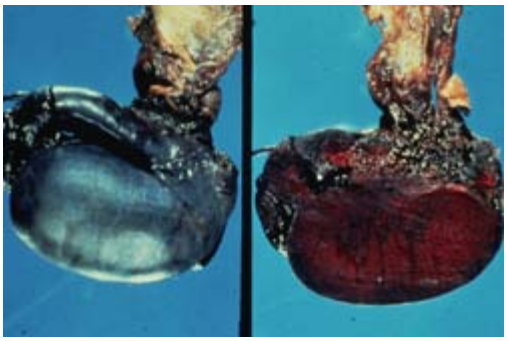

66. Torsion of the testicle with hemorrhagic infarction
Patients lose the cremasteric reflex. The testicle rides high in the inguinal canal from vessel torsion. **(Ren246)**

67. Seminoma
Note the yellow-tan tumor that does not completely replace the testicle (usually they do, but not in this case).
(Ren298)

68. Seminoma
The microscopic appearance of this tumor shows collections of germ cells in nests or cords with a stroma that has scattered lymphocytes present. This is the same histologic pattern that you would see in a dysgerminoma of the ovary.
(Ren299)

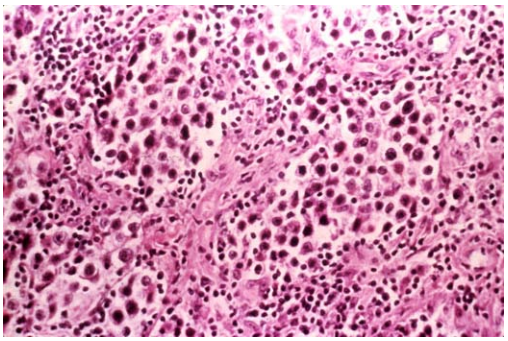

Previous | Next
Return to Top | Return to Image Index

Pathology II Images

Syllabus | Lecture Schedule | Images - Pathology I | Images - Pathology II

Gynecology

1 | 2 | 3 | 4 | 5 | 6 | 7 | 8 | 9 | 10 | 11 | 12

It is against copyright laws to make *electronic or printed* copies of these slides!!

1. Herpes genitalis on labia
Note the grouping of the areas of ulceration on the labia. **(Gyn310) 765**

2. Herpes genitalis on shaft of penis
Note the ulcers and vesicular lesions. **(Gyn201)**

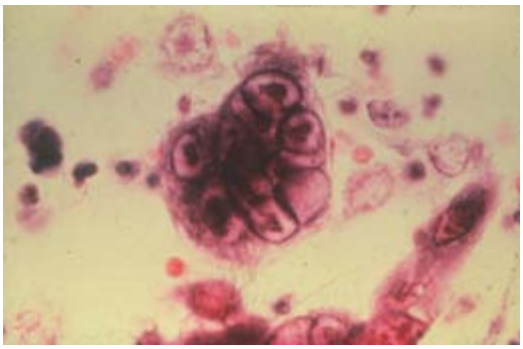

3. Tzanck prep of Herpes genitalis lesion
Note the multinucleated squamous cell and the dark red intranuclear inclusions surrounded by a halo. **(Gyn309)**

4. *Herpes genitalis* cervicitis

Note the erosive nature of the inflammation **(Gyn202)**

5. *Herpes genitalis* proctitis
Note the vesiculoulcerative nature of the lesions **(Gyn203)**

6. Condyloma acuminata ("venereal wart") Note the fern-like appearance of the lesion on the shaft of the penis. It is caused by HPV 6 or 11. **(Derm012)**

7. *Chlamydia trachomatis* urethritis
Note the watery exudate exuding from the meatus of the penis. Gram stain reveals neutrophils but no visible organisms (sterile pyuria). Symptoms occur the second week after sexual exposure. **(Gyn204)**

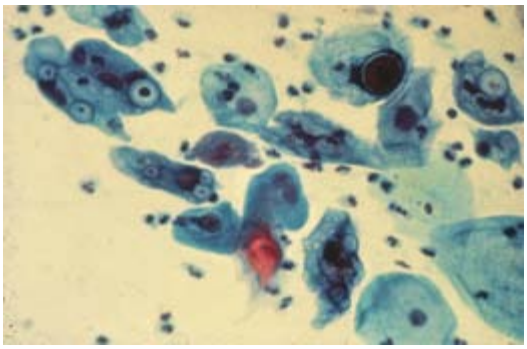

8. *Chlamydia trachomatis* in cervical Pap smear
Note the cytoplasmic inclusions with the vacuoles (lysosomes) and centrally located elementary bodies. **(Gyn308)**

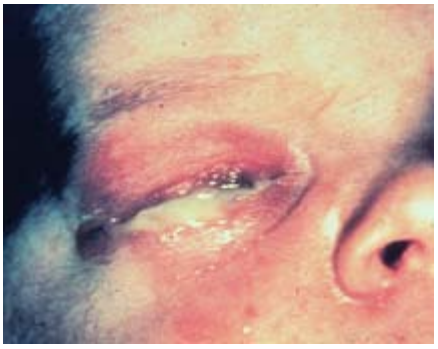

9. *Chlamydia trachomatis* conjunctivitis in a newborn (ophthalmia neonatorum)
Conjunctivitis is usually bilateral and occurs during the second week after delivery. Infection occurs from contamination of the eyes on passage through an infected endocervical canal. *Chlamydia trachomatis* pneumonia also commonly occurs at the same time. **(Gyn205)**

10. *Neisseria gonorrhoeae* urethritis/ cervicitis
Note the thick exudate from the penis and surrounding the external os of the cervix. Symptoms appear within the first week after sexual exposure. **(Gyn206)**

Previous | Next

Return to Top | Return to Image Index

Pathology II Images

Syllabus | Lecture Schedule | Images - Pathology I | Images - Pathology II

Gynecology

1 | 2 | 3 | 4 | 5 | 6 | 7 | 8 | 9 | 10 | 11 | 12

It is against copyright laws to make *electronic or printed* copies of these slides!!

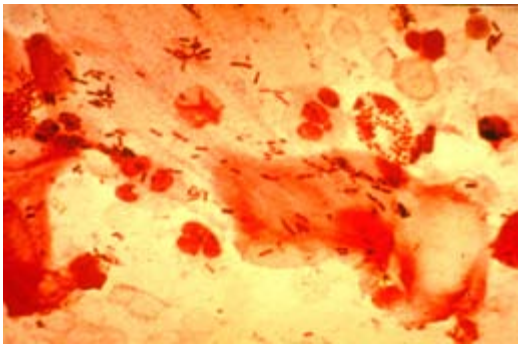

11. *Neisseria gonorrhoeae* gram stain
Note the neutrophil on the right of the screen. It contains numerous gram negative diplococci. The gram negative rods are *Lactobacilli*. **(Gyn311)**

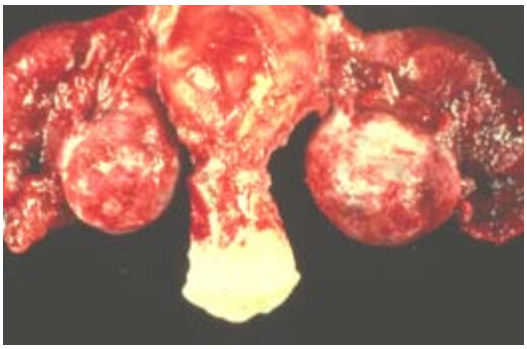

12. Pelvic inflammatory disease due to *Neisseria gonorrhoeae*
Note the inflamed fallopian tubes and enlarged ovaries (contain abscesses). **(Gyn208)**

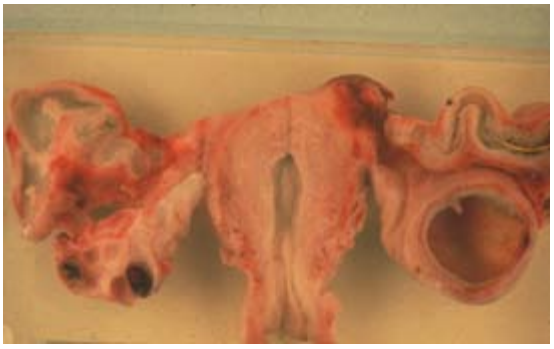

13. Pelvic inflammatory disease due to *Neisseria gonorrhoeae*
Note the pus in the lumens of both fallopian tubes and the multiloculated abscesses in both ovaries. **(Gyn307)**

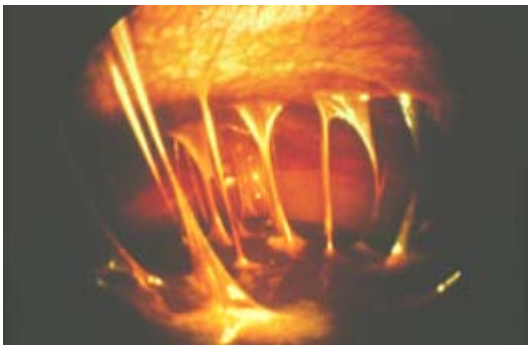

14. Fitz-Hughes-Curtis syndrome
Note the adhesions between the parietal peritoneum and the capsule of the liver. Pus from pelvic inflammatory disease due to *Neisseria gonorrhoeae* and/or *Chlamydia trachomatis* may produce these adhesions. Patients complain of chronic pain in the RUQ. **(Gyn209)**

15. Vulvar lymphedema secondary to

lymphogranuloma venereum
LGV is due to a variant of *Chlamydia trachomatis*. Unlike other STDs, this STD has **papular lesions** (not visible) rather than ulcers and granulomatous microabscesses in the inguinal lymph nodes. Obstruction of lymphatics leads to localized lymphedema. Rectal strictures are also common in women. **(Gyn314)**

16. Chancroid (*Hemophilus ducreyi*)
Note the ulcer on the shaft of the penis. Unlike syphilis, it is painful. Gram stain demonstrates a school of fish orientation of the gram negative organisms. **(Gyn306)**

17. Granuloma inguinale (*Calymmatobacterium granulomatis*)
Note the serpiginous ulcers. Unlike other STDs, there is **no lymphadenopathy**. **(Gyn217)**

18. Donovan bodies in macrophages in granuloma inguinale
Note the phagocytosed organisms. They are very similar in appearance to *Histoplasma* yeasts and leishmanial forms in leishmaniasis. **(Gyn312)**

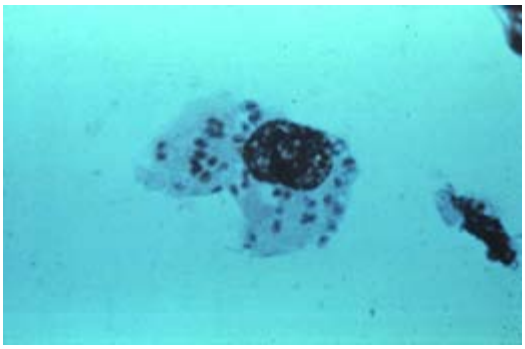

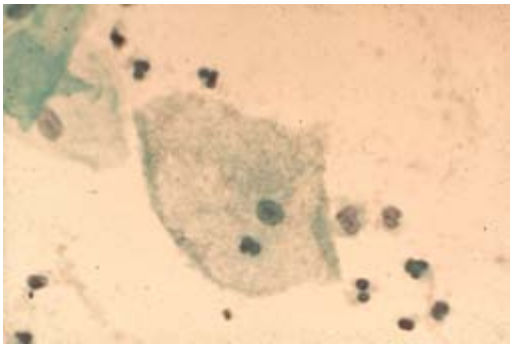

19. Clue cell in bacterial vaginosis due to Gardnerella vaginalis
Note the granular material (adherent bacteria) covering the surface of the superficial squamous cell. These are called **clue cells**. **(Gyn304)**

20. Dark field of *Treponema pallidum*
Note the tightly wound spirochete. Dark field is considered the gold standard for diagnosing syphilis. **(Gyn210)**

Previous | Next

Return to Top | Return to Image Index

Pathology II Images

Gynecology

It is against copyright laws to make *electronic or printed* copies of these slides!!

31. Squamous cell carcinoma of the labia majora
Note the ulcerated lesion on the labia minora. HPV 16 and 18 are the primary causes. **(Neo091)**

32. Vulvar leukoplakia
Note the white discoloration of the thin epidermis. This patient has lichen sclerosis **(Gyn224)**

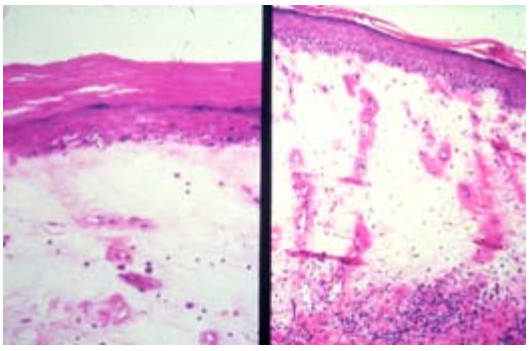

33. Lichen sclerosis of vulva
Note the thinning of the epidermis and hypocellular area in the superficial dermis. It is not a precursor for cancer **(Gyn225)**

34. Squamous hyperplasia of vulva

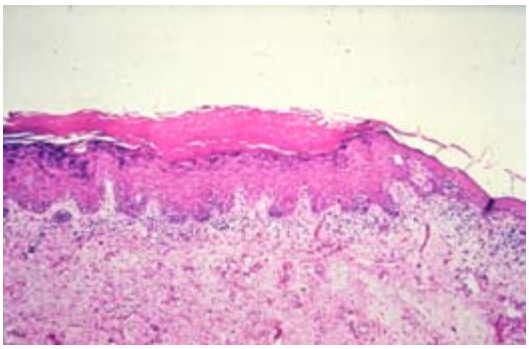

Clinically, this would have looked like leukoplakia. Note the increased stratum corneum, increased thickness of the epidermis, and underlying inflammation. This is a precursor for squamous cancer. **(Gyn226)**

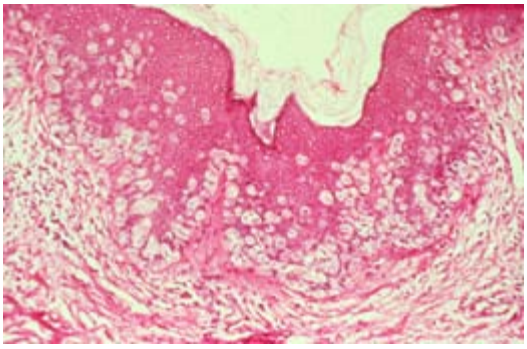

35. Vulva with Paget's disease
Note the large cells surrounded by a clear halo in the epidermis. These are malignant glandular cells (mucin positive, S100 antigen negative). Paget's is a cancer limited to the epithelium. **(Gyn294)**

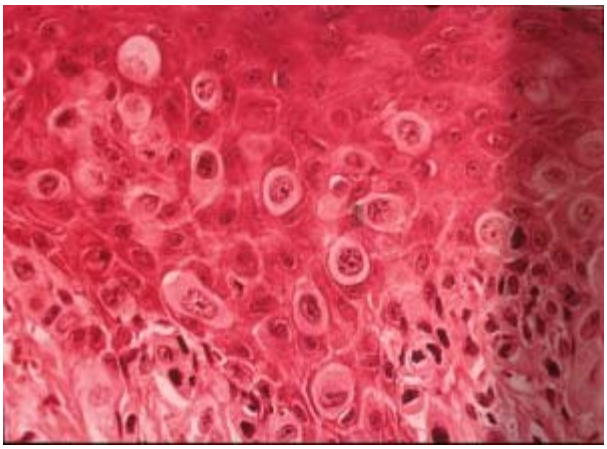

36. Paget's disease of the vulva
This slide shows large cells with clear appearing cytoplasm present in the lower portion of the epidermis. These represent Paget's cells and would stain positive for mucin. **(Gyn016)**

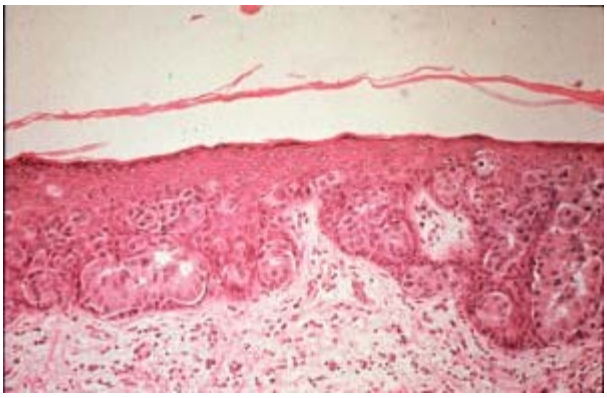

37. Paget's disease of the vulva
Notice that there are several nests of large clear cells present in the owner portion of the epidermis. These represent Paget's cells. **(Gyn017)**

38. Gartner's duct cyst
Note the cyst in the lateral wall of the vagina. Remnant of Wolffian duct (mesonephric duct). **(Gyn227)**

39. Rokitansky-Kuster-Hauser syndrome (Mullerian agenesis)
Note absence of the vagina. The uterus is often absent as well. The patient has primary amenorrhea due to an end-organ defect. **(Gyn228)**

40. Imperforate hymen with blood behind the membrane (Gyn229)

Previous | **Next**
Return to Top | **Return to Image Index**

Pathology II Images

Gynecology

It is against copyright laws to make *electronic or printed* copies of these slides!!

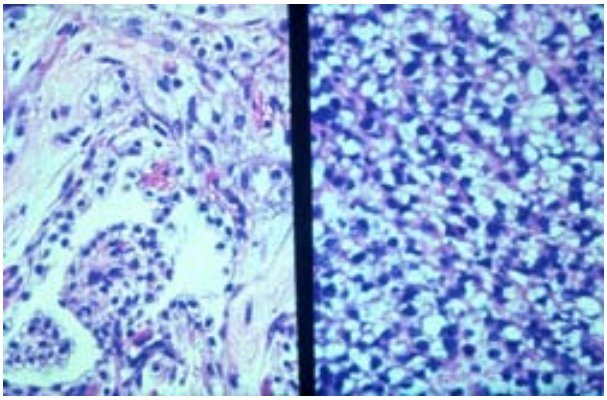

41. Clear cell carcinoma of the vagina
This lesion is found in the daughters of women who took DES. Daughters are predisposed to vaginal adenosis (benign Mullerian epithelium), which is the precursor for clear cell adenocarcinoma. It occurs in the age group of 17-22 and occurs on the anterior wall of the upper third of the vagina where Mullerian epithelium joins with the urogenital sinus. Notice that the tumor forms glandular structures on the left or sheets of clear staining cells on the right. **(Gyn022)**

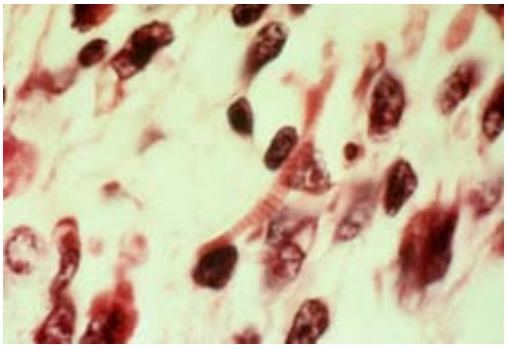

42. Embryonal rhabdomyosarcoma
This slide shows a classic feature of the embryonal rhabdomyosarcoma (skeletal muscle sarcoma), mainly cross striations. **(Neo205)**

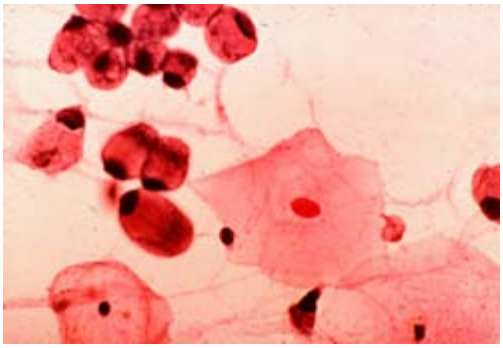

43. Cervical pap smear with endocervical cells
Note the glandular appearing endocervical cells on your left. These indicate that there is adequate sampling of the transformation zone, the primary site for squamous dysplasia and cancer. **(Gyn231)**

44. Cervical pap smear with superficial squamous cells
Note the eosinophilic cytoplasm (may be blue) and pyknotic nucleus. These cells indicate estrogen stimulation. **(Gyn315)**

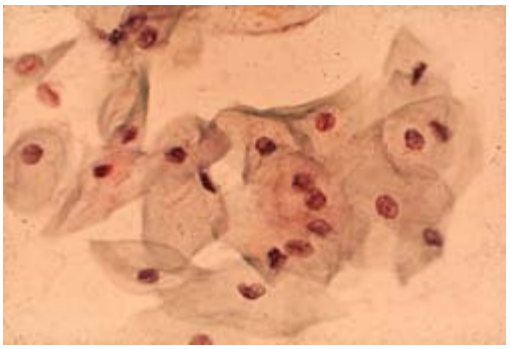

45. Cervical pap smear with intermediate squamous cells
Note the blue cytoplasm (may be eosinophilic) and less dense appearing nuclei. These indicate progesterone stimulation. **(Gyn316)**

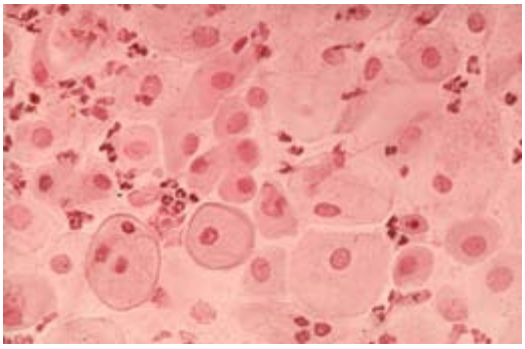

46. Cervical pap smear with parabasal cells: parabasal cells indicate the absence of estrogen and progesterone stimulation. **(Gyn317)**

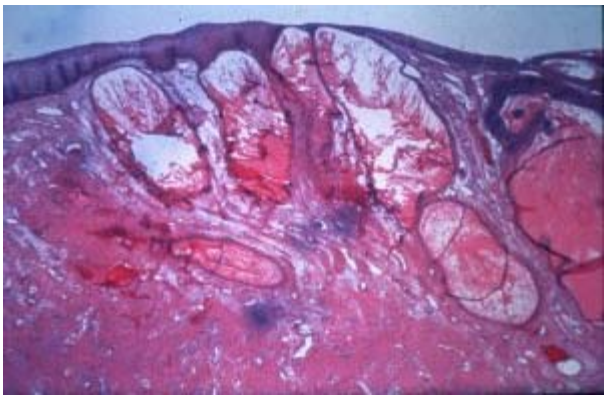

47. Nabothian cysts
Nabothian cysts arise in endocervical glands where the gland duct has been blocked by squamous epithelium that has replaced endocervical epithelium. Nabothian cysts are a feature of chronic cervicitis. **(Gyn038)**

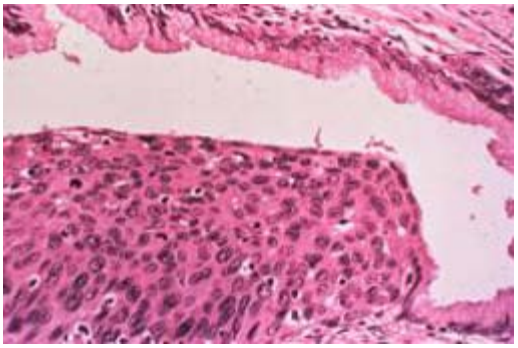

48. Carcinoma-in-situ (CIN III) of the cervix
Note the full thickness dysplasia of the epidermis and lack of surface maturation. HPV 16 or 18 are the MC causative agent. **(Neo093)**

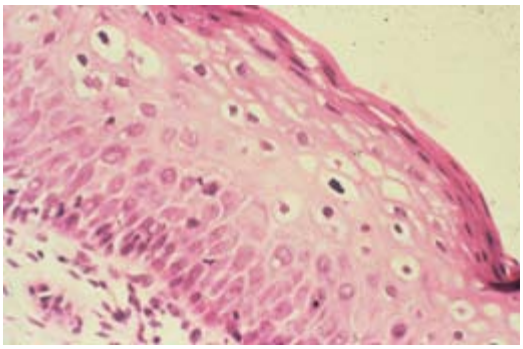

49. Koilocytosis of cervix
Note the squamous cells with the pyknotic nuclei surrounded by a clear space (called koilocytosis). These cells have been infected by HPV. **(Gyn318)**

50. Cervical dysplasia mosaic pattern
This pattern is associated with dysplasia of the cervix. It is produced when acetic acid is applied to

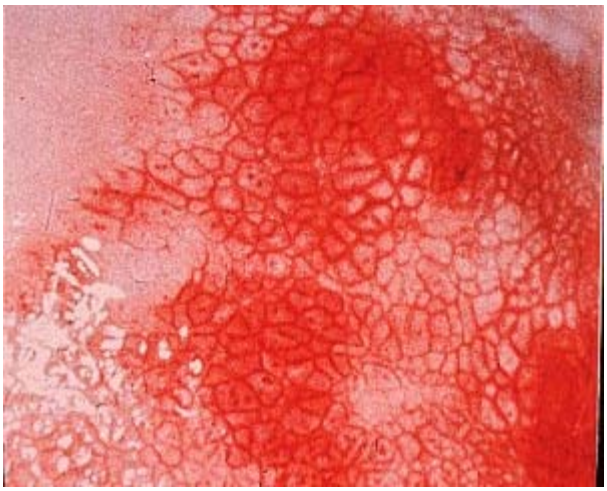

the surface of the cervix. This application coagulates the proteins of the nucleus and cytoplasm of the cervical cells and makes the proteins opaque and white. The term referring to this change is called acetowhite epithelium. The mosaic pattern is caused by terminal capillaries surrounding roughly circular or polygonal shaped blocks of acetowhite epithelium crowded together which causes the mosaic pattern similar to mosaic tile. The vessels form a basket around the blocks of abnormal epithelium. **(Gyn047)**

Previous | **Next**

Return to Top | **Return to Image Index**

Pathology II Images

Gynecology

It is against copyright laws to make
electronic or printed copies of these slides!!

51. Invasive cervical squamous carcinoma
The rectal vault is to your left. A portion of distal vagina and ulcerated cervix, representing squamous cancer, is in the middle. The urinary bladder is on your right. Note the white appearing cancer extending through the wall of the cervix into the wall of the subjacent urinary bladder. Although not visible, the ureterovesical junction is in this area and is most likely blocked by the cancer. This explains why renal failure is the MC cause of death. **(Gyn319)**

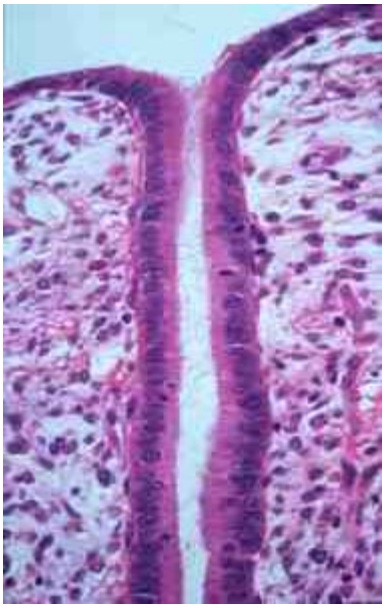

52. Endometrial cycle
This slide shows the early proliferative phase which is evidenced as elongation of the endometrial glands. The cells lining the glands show scattered mitotic figures. There is no obvious stratification at this time. **(Gyn051)**

53. Endometrial cycle
This slide shows a gland that is representative of a later stage of the proliferative phase. The nuclei within the gland demonstrate stratification and there

are scattered mitotic figures present. **(Gyn052)**

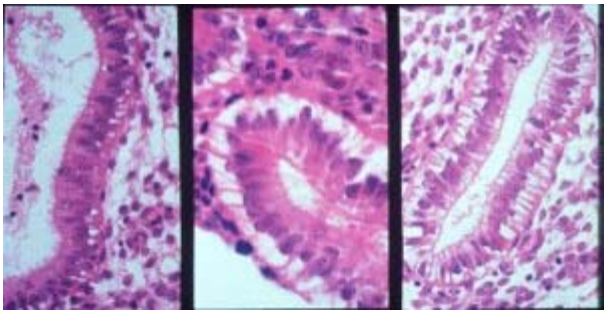

54. Endometrium-ovulation
The presence of **subnuclear vacuoles** is consistent with the ovulatory phase of the cycle. The secretory products will then progress toward the lumen as the glands enter the secretory phase. The subnuclear vacuoles typically appear around cycle day 16. **(Gyn053)**

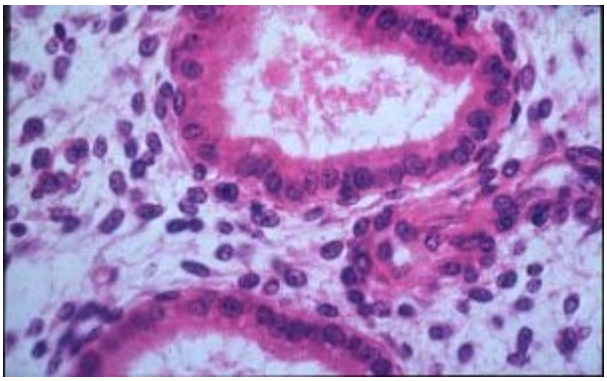

55. Early secretory phase-endometrium
This slide demonstrates several vacuoles which are on the luminal side of the glands. This is consistent with the migration of the vacuole toward the lumen. This usually occurs by cycle day 19-20. **(Gyn054)**

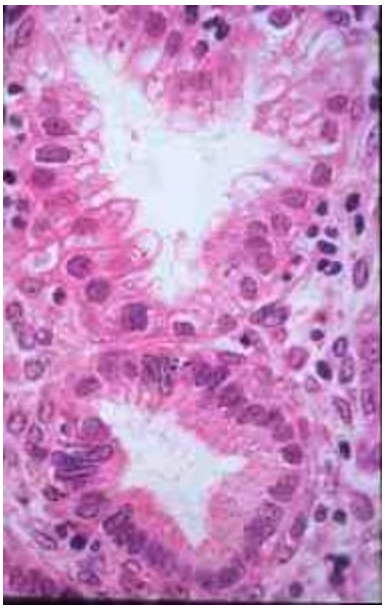

56. Secretory phase-endometrium
This slide demonstrates a slightly later stage of the secretory phase in the previous slide. Notice the marked vacuolization projecting toward the lumen and the presence of secretory material within the lumen of the glands. **(Gyn055)**

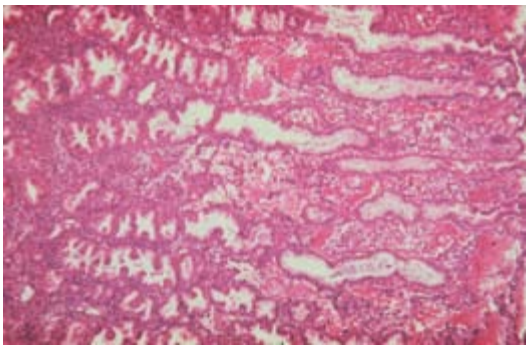

57. Late secretory phase of the menstrual cycle
Note the prominent tortuosity of the glands. **(Gyn242)**

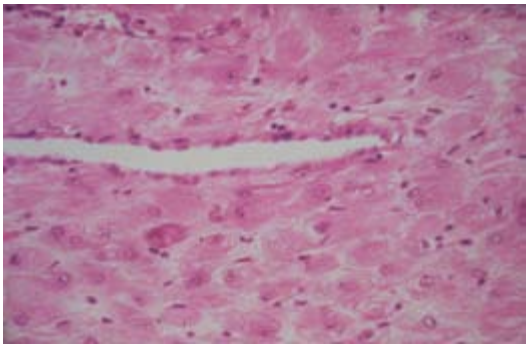

58. Decidualized stroma
Decidualization of stromal cells is a sign of pregnancy. **(Gyn243)**

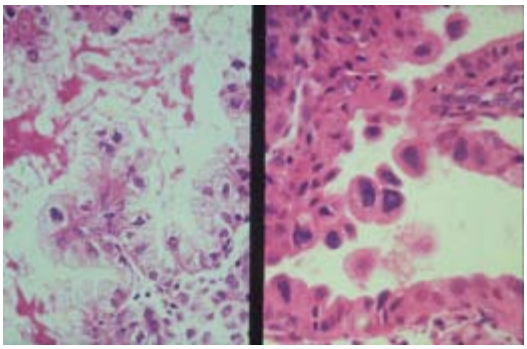

59. Arias-Stella phenomenon
An exaggerated secretory phase as evident in this slide is a sign of pregnancy. **(Gyn244)**

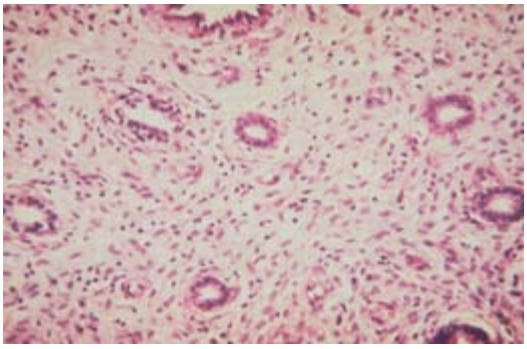

60. Endometrial mucosa in a patient on birth control pills
Note the atrophy of the endometrial glands (progesterone effect) and prominent pseudodecidualized stroma. **(Gyn246)**

Previous | **Next**

Return to Top | **Return to Image Index**

Pathology II Images

Gynecology

It is against copyright laws to make *electronic or printed* copies of these slides!!

61. Hirsutism
Note the increase in hair in normal hair bearing areas. Virilization is hirsutism + signs of male secondary sex characteristics (e.g., clitoromegaly). **(Gyn320)**

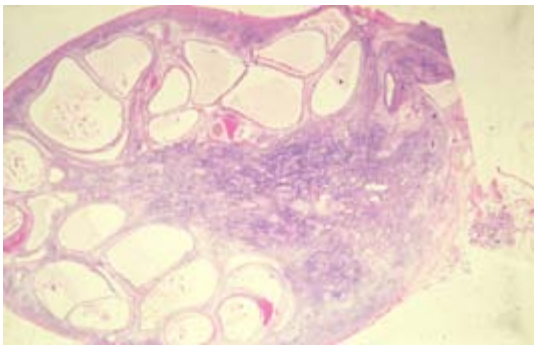

62. Ovary with subcortical cysts in polycystic ovarian syndrome
Note the cysts that are devoid of follicles. Constant suppression of FSH causes the follicles to degenerate. **(Gyn321)**

63. Turner's syndrome
Patient is XO. Note the poor female secondary sex characteristics and prominent webbed neck. **(Gyn248)**

64. Intrauterine device (Gyn249)

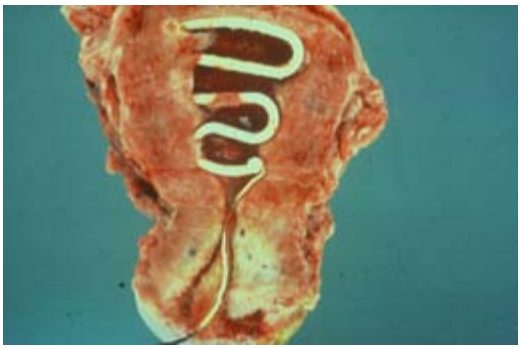

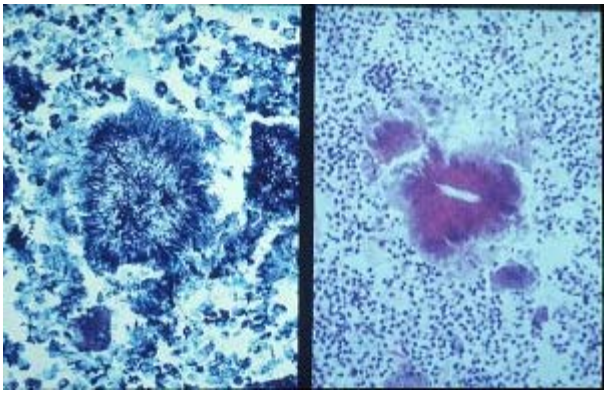

65. Chronic endometritis
Both of the microscopic sections represented on this slide show sulfur granules associated with *Actinomyces israelii*. This organism is associated with the presence of an IUD. The diagnosis of endometritis of the chronic type is based on finding plasma cells in the stroma. The sulfur granules represent tangles of organisms which are filamentous. **(Gyn060)**

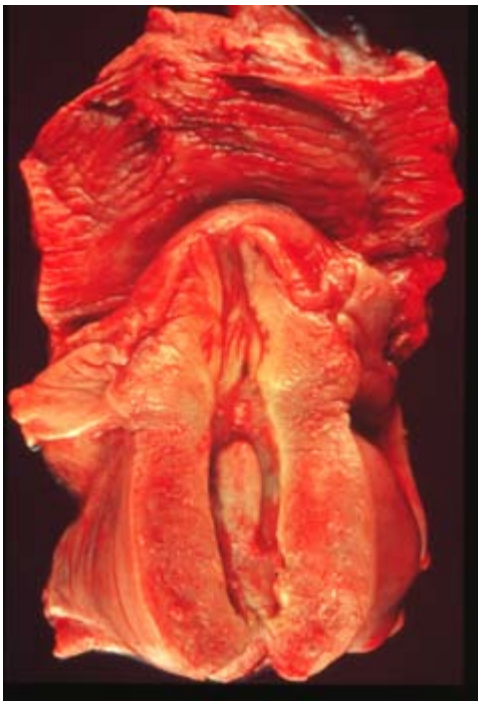

66. Endometrial polyp
The vagina is at the top and uterus on the bottom. A polyp is noted in the lumen of the uterus. Polyps are not precursors for cancer, however, they are a common cause of bleeding. **(Gyn251)**

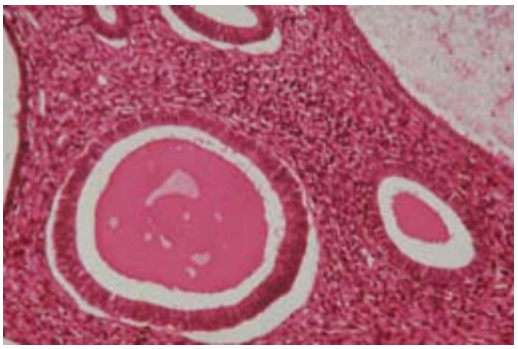

67. Simple hyperplasia of endometrial mucosa
Note the enlarged gland with secretions in the center. **(Gyn257)**

68. Complex hyperplasia of endometrial mucosa
Note the glandular crowding with outpouching of glandular lumens. It is a precursor for

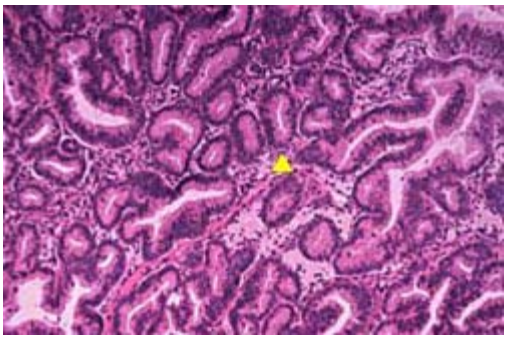

adenocarcinoma. **(Ci048A)**

69. Uterus with adenomyosis
Note the enlarged uterus with coarse trabeculation of the myometrial tissue. **(Gyn254)**

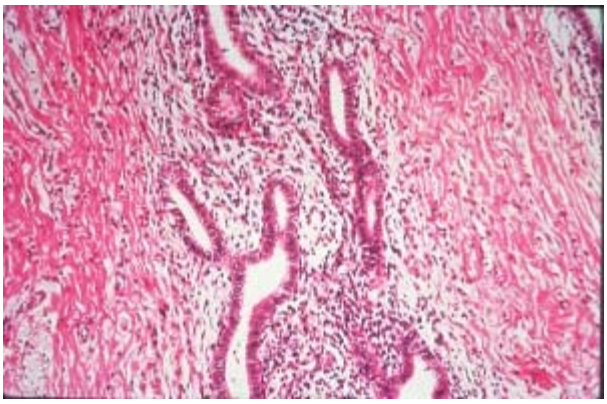

70. Adenomyosis
This slide shows the presence of endometrial glands and stroma within the wall of the uterus and not connected to the overlying endometrium. It is not endometriosis, since endometriosis is the presence of functioning glands and stroma outside the confines of the uterus. **(Gyn062)**

Previous | Next
Return to Top | Return to Image Index

Pathology II Images

Gynecology

It is against copyright laws to make *electronic or printed* copies of these slides!!

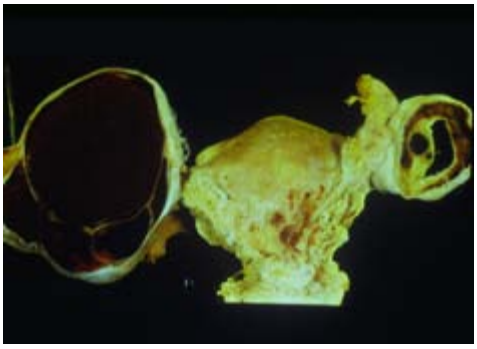

71. Bilateral hemorrhagic cysts of the ovaries associated with endometriosis. (Gyn255)

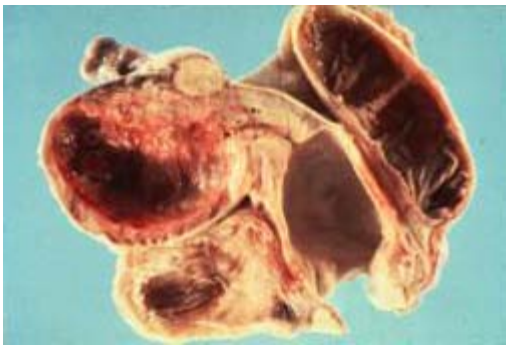

72. Endometrial adenocarcinoma
The rectal ampulla is to your right (note the pouch of Douglas between the rectum and posterior wall of the uterus). The entire vagina, cervix, and uterus is in the middle. The bladder is on your left. Note the fungating cancer in the top portion of the body of the uterus. The tumor extends through the wall and out to the serosa. **(Neo095)**

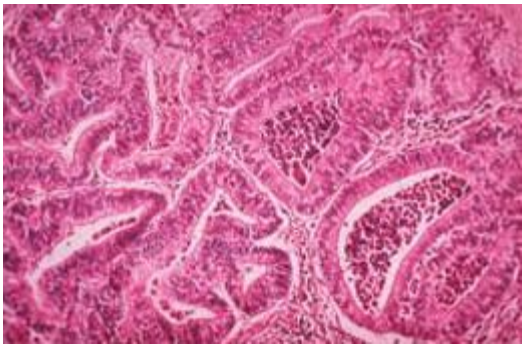

73. Endometrial adenocarcinoma
Note the crowding of the neoplastic glands and necrotic debris in the gland lumens. **(Neo096)**

74. Leiomyomas of the uterus
Note the white swirling masses in the body of the fundus. An invasive cervical squamous cancer is present in the underlying cervix (white material). **(Neo094)**

75. Leiomyomas of the uterus

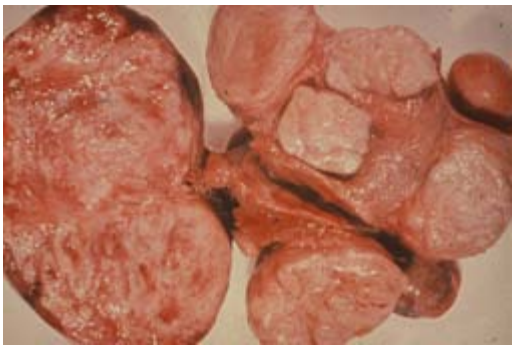

Note the large pedunculated leiomyoma originating from the serosa. They do not predispose to leiomyosarcoma. **(Gyn252)**

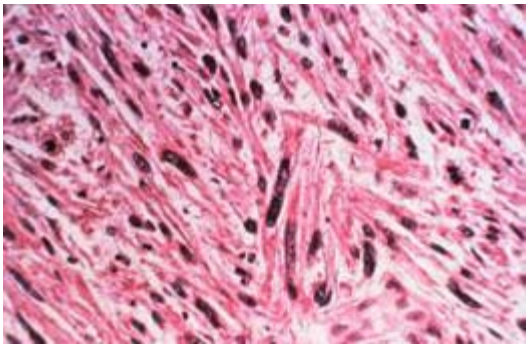

76. Leiomyosarcoma
Note the anaplastic appearing nuclei. The mitosis count is the key to diagnosing these sarcomas. **(Neo097)**

77. Ruptured ectopic pregnancy
Note the embryo within the blood clot. **(Gyn322)**

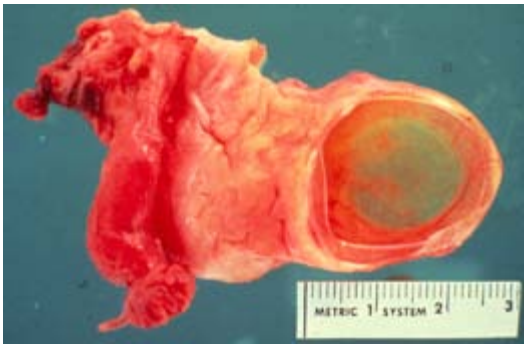

78. Follicular cyst of the ovary
These commonly rupture and produce localized sterile peritonitis. They are the **MC ovarian mass in young women. (Gyn323)**

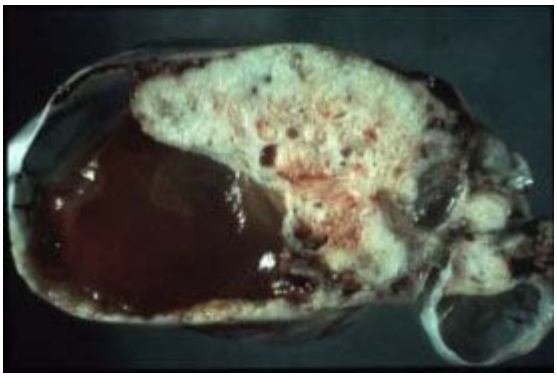

79. Serous cystadenocarcinoma
This slide shows a large cystic structure with solid areas. The presence of the solid tissue is consistent with the malignant form of serous tumor. Microscopic exam would show ciliated epithelium. This is the **most common primary malignant ovarian tumor**. Sixty-six percent of the cases are bilateral. The marker for this tumor is CA125. It is one of the tumors of the ovary that calcify. The calcified structures are called psammoma bodies. **(Gyn099)**

80. Serous cystadenocarcinoma
This is an additional section of the serous malignant tumor showing the papillary structures and psammoma bodies (apoptotic tumor cells with dystrophic

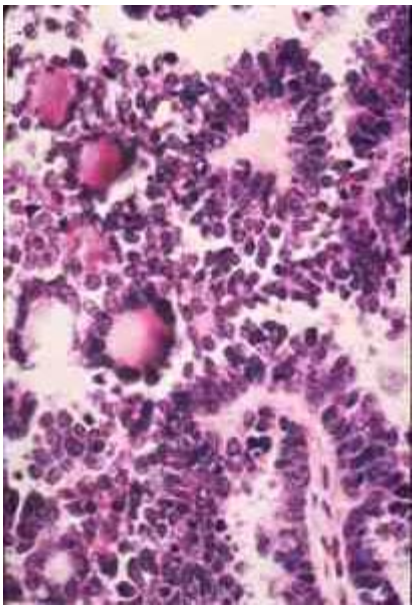

calcification). **(Gyn101)**

Previous | **Next**

Return to Top | **Return to Image Index**

Pathology II Images

Gynecology

It is against copyright laws to make *electronic or printed* copies of these slides!!

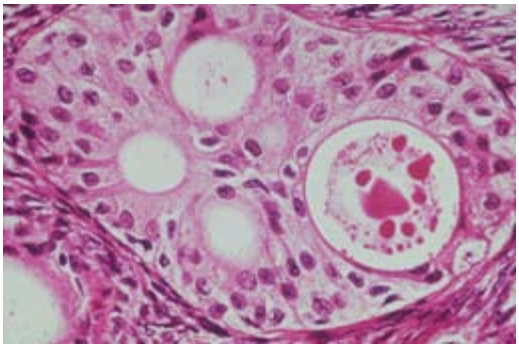

81. Brenner's tumor with a Walthard's rest
These are benign tumors derived from surface epithelium. They are commonly associated with benign mucinous cystadenomas. The epithelium of a Walthard rest has a transitional cell appearance. **(Gyn265)**

82. Mucinous cystadenocarcinoma
This slide is a gross specimen of a mucinous tumor which has been opened showing solid areas and cystic areas. Presence of solid areas is characteristic of the malignant variant of the cystadenocarcinoma. These tumors commonly seed the omentum and produce pseudomyxoma peritoneii. They are the **largest of all ovarian tumors**. **(Gyn112)**

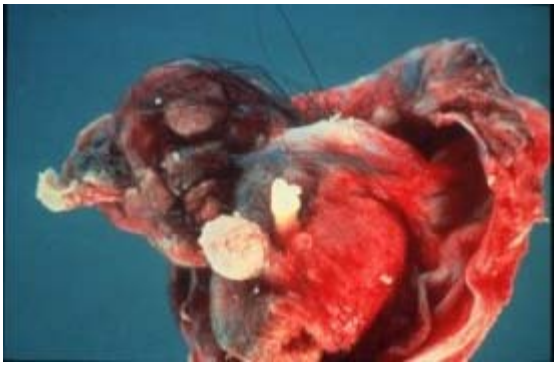

83. Cystic teratoma (mature teratoma)
This slide is a gross specimen of a tumor that demonstrates severeal characteristics of the benign teratoma. This tumor is derived from all 3 germ cell layers, but the ectodermal component is the most commonly represented or is the component that is the most dominant as far as appearance of the tumor. Notice that there is hair protruding from the tumor. There are also tooth-like structures present. This tumor is the most common germ cell tumor and the mature variant or cystic variant is benign. It is also called a dermoid cyst. This tumor originates from a single germ cell after its first meiotic division. The tumor occurs in young women in the 20-40 year age range. Occasionally it can contain a malignant component and that would be most typically a squamous cell carcinoma. **(Gyn124)**

84. Cystic teratoma, benign
This specimen shows a large ovarian mass attached to the uterus which you can appreciate on the left side of the slide. The tumor has been opened and shows a keratin-like material filling the cyst. There is quite a lot

of hair also associated with the tumor. **(Gyn125)**

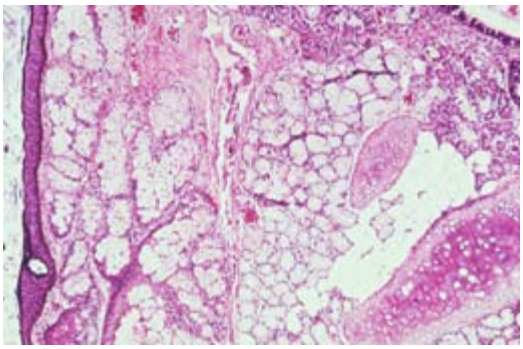

85. Histologic section of a cystic teratoma (germ cell tumor)
Note the squamous epithelium, sebaceous glands, and cartilage. **(Gyn268)**

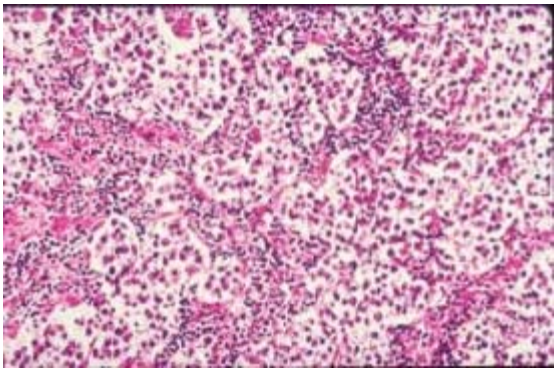

86. Dysgerminoma
This shows large cells surrounded by stroma with a lymphocytic infiltrate. These malignant germ cell tumors are the female counterpart of seminomas in males. They are associated with Turner's syndrome. **(Gyn134)**

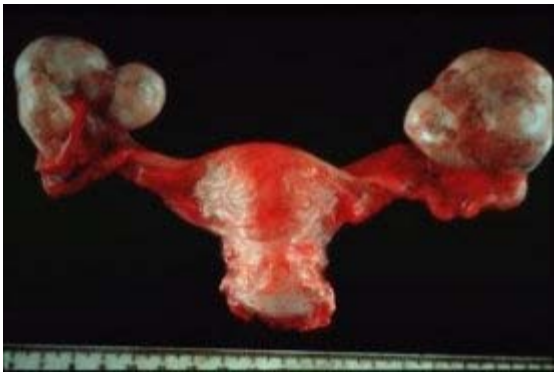

87. Ovarian fibromas
Note the bilateral nodular masses in both ovaries. These are the MC stromal tumor of the ovary and are benign. Fibromas are not typically hormone-producing unless they contain thecal cells. This patient may have had **Meigs syndrome** which refers to the presence of a right-sided pleural effusion, an ovarian fibroma, and ascites. **(Gyn146)**

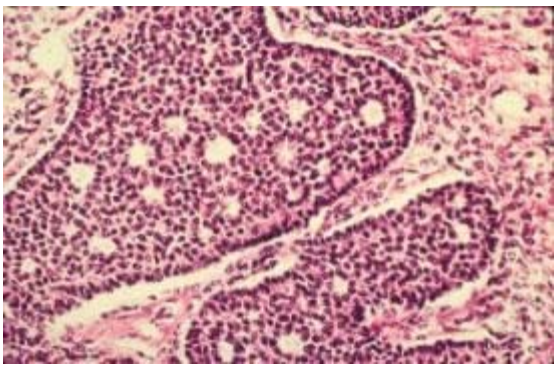

88. Granulosa theca cell tumor
This is a microscopic appearance of the granulosa/thecal cell tumor. The nests of cells resemble the follicle of the ovary. The clear spaces are called Call-Exner bodies, which are a diagnostic feature of the granulosa cell tumor. These tumors are the **MC tumor to secrete estrogen**. **(Gyn141)**

89. Hilar cell tumors (steroid cell tumors). These tumors are benign and secrete androgens. They are

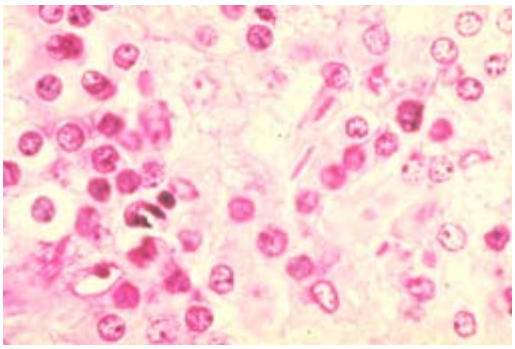

unilateral. A characteristic feature is the elongated eosinophilic rod-like crystal which is called a **Reinke crystalloid**. **(Gyn274)**

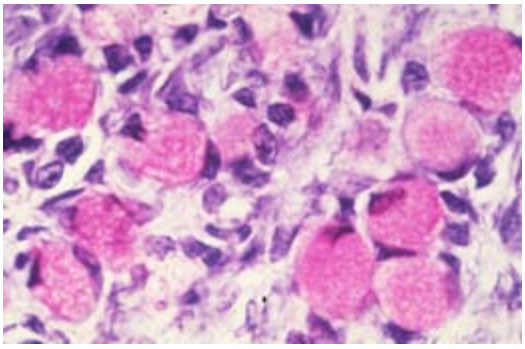

90. Metastatic adenocarcinoma to ovary
This slide shows mucin-positive signet ring cells which is called a **Krukenberg tumor**. It is most commonly a mucin producing adenocarcinoma from the stomach which metastasizes to both ovaries. **(Gyn275)**

Previous | **Next**

Return to Top | **Return to Image Index**

Pathology II Images

Gynecology

It is against copyright laws to make *electronic or printed* copies of these slides!!

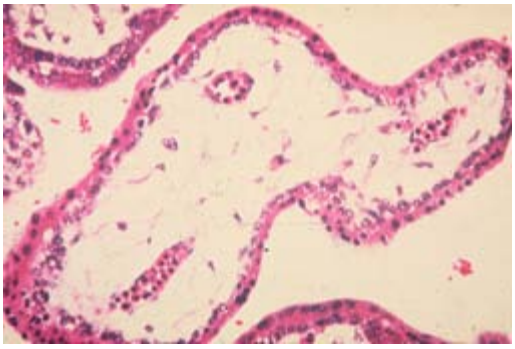

91. Normal chorionic villus
The surface is lined by trophoblastic tissue (syncytiotrophoblast on the outside and cytotrophoblast underneath). Note the myxomatous stroma and small vessels with nucleated RBCs. These vessels coalesce to form 2 umbilical veins, which carry the greatest concentration of oxygen. **(Gyn324)**

92. Abruptio placenta
This slide shows multiple sections through placenta with a retroplacental clot. Abruptio placenta will present with **painful vaginal bleeding** and it represents a premature separation of the placenta producing a retroplacental clot. It's a complication of pre-eclampsia and any cause of hypertension. It is associated with cocaine addiction. **(Gyn154)**

93. Abruptio placenta
This is an additional specimen showing a placenta with retroplacental clot. Notice the umbilical cord in the central portion of the specimen. When hematomas form involving a third or more of the maternal surface of the placenta, this can result in fetal demise. There is a 30 to 65% mortality rate of the fetus associated with abruptio placenta. Recall that this is a complication of

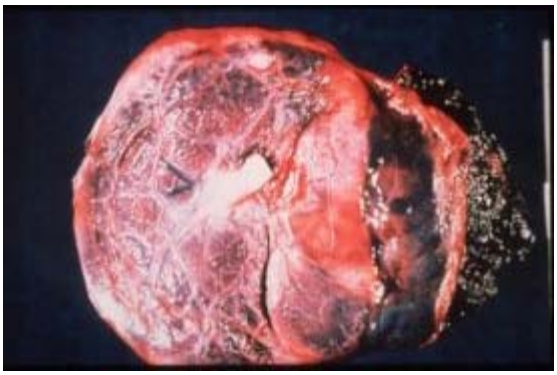

pre-eclampsia, hypertension, and cocaine addiction. **(Gyn155)**

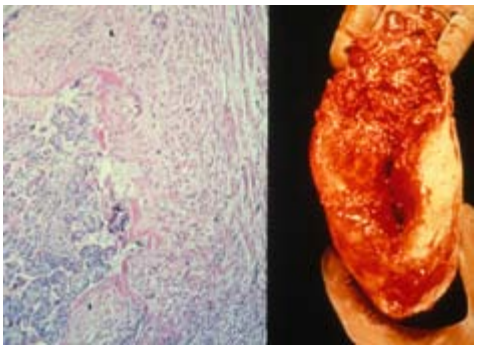

94. Placenta accreta
Note the chorionic villi on the left of the histologic section directly implanting on myometrial tissue without any intervening decidua. The uterus must be removed (gross specimen) or the patient will bleed to death. **(Gyn279)**

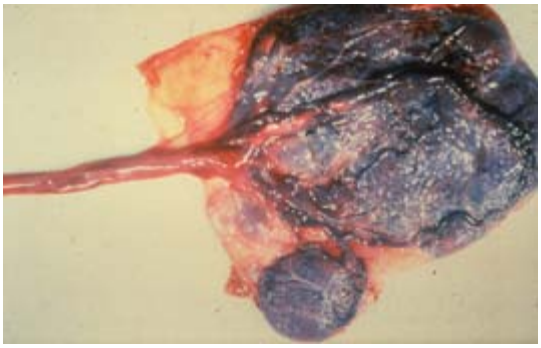

95. Accessory lobe and velamentous insertion of the umbilical cord along the margin of the placenta
Both pose a risk for hemorrhage. **(Gyn281)**

96. Hydatidiform (complete) mole
Note the grape like masses representing neoplastic chorionic villi lined by trophoblastic tissue. They present as **preeclampsia in the first trimester and a uterus too large for gestational age**. Ultrasound demonstrates a "snowstorm" effect. They may progress into a choriocarcinoma if not adequately removed. **(Neo105)**

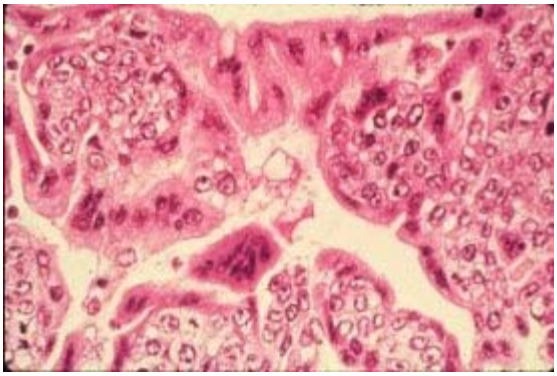

97. Choriocarcinoma
This slide illustrates the two populations of cells composing a choriocarcinoma. You notice that the central portion of the nests contain cells with clear vacuolated looking nuclei. Surrounding these little chords or nests of cells are the syncytotrophoblasts (hormone producing cells) which are groups of nuclei within a large mass of cytoplasm. The cells in the central portion are the cytotrophoblasts. **(Gyn162)**

98. Fibrocystic change
Note the large cyst surrounded by a fibrous stroma within which are smaller bluish-discolored cysts. **FCC is the**

MCC of a breast mass in women under 50 years old. **(Gyn325)**

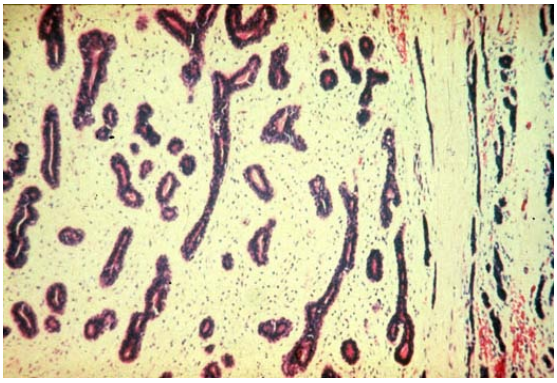

99. Fibroadenoma
This is a microscopic appearance of a fibroadenoma showing the slit-like duct spaces surrounded by stroma. It is a well circumscribed tumor. **Fibroadenoma is the most common benign breast tumor and it occurs in women younger than age 35**. It most commonly occurs in the left upper quadrant of the breast and presents as a firm rubbery painless well-circumscribed mass. It is due to an increased sensitivity to estrogen. **(Gyn178)**

100. Carcinoma of the breast
This patient has been asked to raise her arms. Note the retraction of the skin in the left lower quadrant associated with an underlying invasive ductal carcinoma. **(Gyn192)**

Previous | Next

Return to Top | Return to Image Index

Pathology II Images

Gynecology

It is against copyright laws to make *electronic or printed* copies of these slides!!

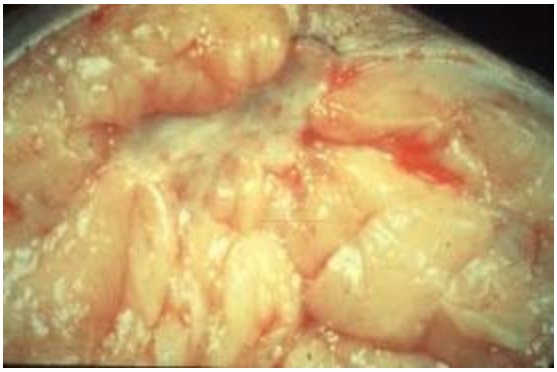

101. Infiltrating ductal carcinoma
The infiltrating ductal carcinoma is the most common type of breast cancer. Grossly, it appears as a stellate area of firm tissue which is described as being stony hard. Another name applied to this tumor is a scirrhous carcinoma. The fixed nature of the tumor is due to desmoplastic response as the individual tumor cells invade surrounding tissues. This causes fixation to overlying structures as the skin and the dimpling affect or retraction that is noted with infiltrative cancers. **(Gyn195)**

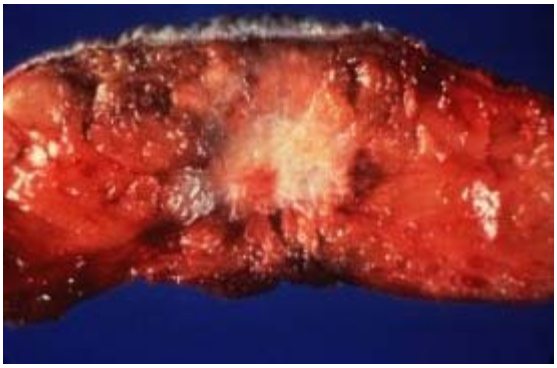

102. Infiltrating ductal carcinoma
This is another gross specimen demonstrating a stellate-appearing firm nodule. **(Gyn196)**

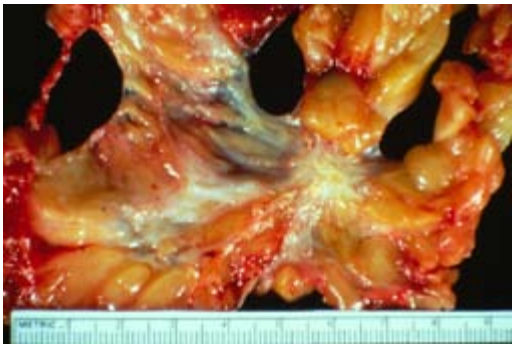

103. Gross of infiltrating ductal cancer
Note the stellate appearance of the indurated mass. **(Gyn286)**

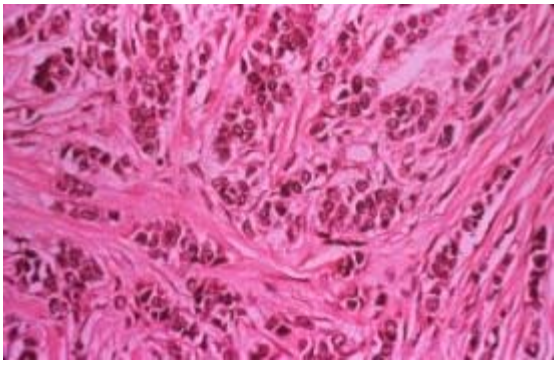

104. Infiltrating ductal carcinoma
This slide is quite classic for the typical pattern of an infiltrating ductal cancer. Notice that the tumor cells are in next and cords and they are infiltrating through the surrounding tissue. There is an intense desmoplastic response to this infiltration which gives the name scirrhous carcinoma to this type of invasive cancer of the breast. **(Gyn197)**

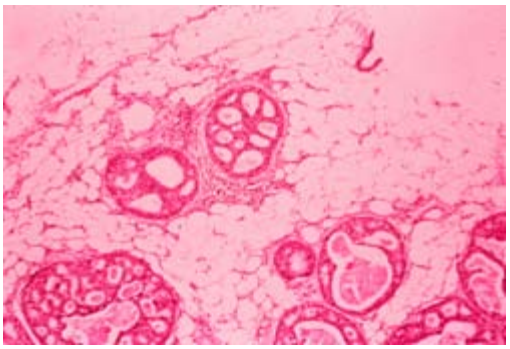

105. Cribriform (sieve-like) pattern of ductal carcinoma in-situ (DCIS) (Gyn287)

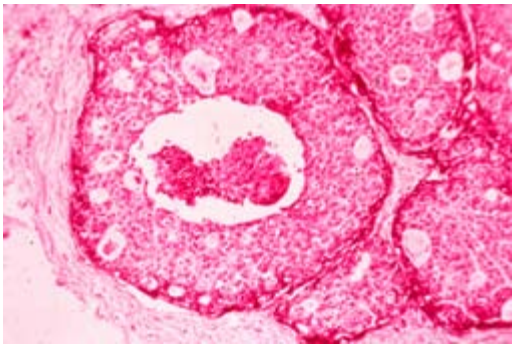

106. Comedocarcinoma variant of DCIS
Note the necrotic centers of the ducts surrounded by malignant ductal cells. **(Gyn288)**

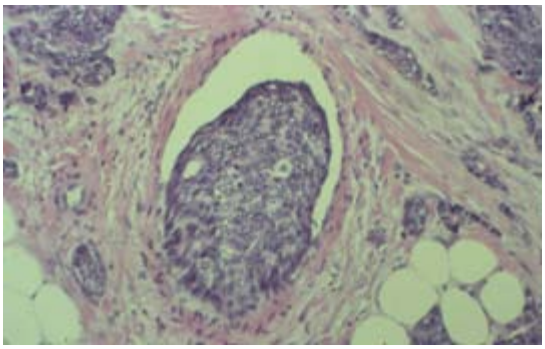

107. Infiltrating ductal carcinoma with vessel invasion
Note the vessel in the middle of the slide has a plug of tumor. Nests of malignant cells are infiltrating the stroma around the vessel. **(Gyn289)**

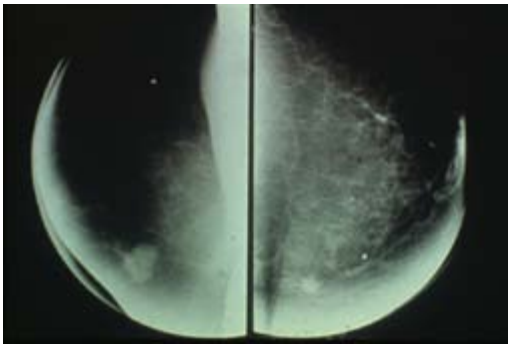

108. Mammogram showing densities in both breasts
A fine needle aspiration is necessary to determine whether these lesions are benign or malignant. **(Gyn284)**

109. Paget's disease of breast
Notice that the nipple surrounded by an eczematoid rash. This characteristic is associated with Paget's disease, which is a ductal carcinoma that is infiltrating the epithelium of the nipple and areola. Microscopic appearance would show clear cells in the epidermis, similar to those noted in extramammary Pagets of the vulva. **(Gyn1904)**

110. Paget's disease of the breast
Note the eczematous appearing rash and nipple inversion on the left. **(Gyn290)**

Previous | Next
Return to Top | Return to Image Index

Pathology II Images

Gynecology

It is against copyright laws to make *electronic or printed* copies of these slides!!

111. Paget's disease of the breast
Note retraction of the bottom portion of the nipple. The tip of the nipple has an abnormal discoloration, probably representing malignant cells infiltrating the epidermis. **(Gyn291)**

112. Carcinoma of the breast peau d' orange.
Notice the dimpling of the skin having the appearance of an orange. This is due to obstruction of subcutaneous lymphatics causing localize lymphedema. **(Gyn193)**

113. Peau d'orange appearance of inflammatory carcinoma of the breast
Note the enlarged erythematous right breast with the dimpling effect on the surface. **(Gyn295)**

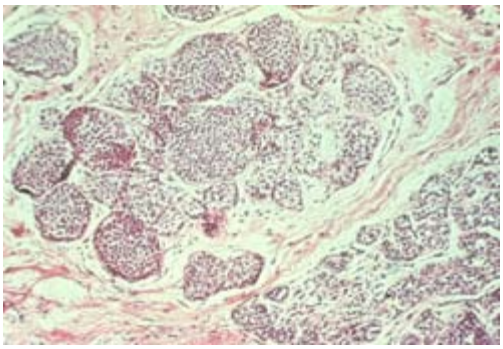

114. Lobular carcinoma in-situ
Note the terminal acini filled with monomorphic appearing cells. This neoplasm has the **greatest incidence of bilaterality**. **(Gyn297)**

115. Infiltrating lobular carcinoma

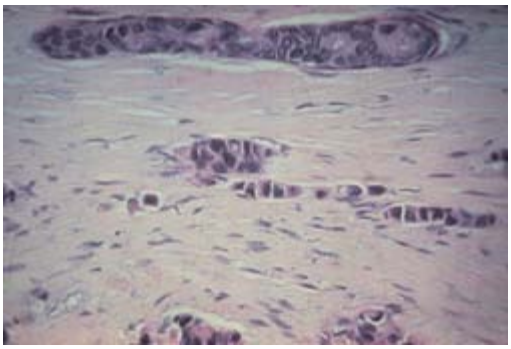

In the middle of the slide you see individual tumor cells that are lined up behind one another infiltrating through the tissue. This is called the **Indian file pattern** of infiltration of an invasive lobular carcinoma. **(Gyn298)**

116. Cystosarcoma phyllodes or phyllodes tumor
This is a gross specimen showing in a massively enlarged left breast which has been replaced by large, bulky tumor tissue. Most patients who develop this lesion are older than 40. This tumor has benign glandular tissue and a malignant stroma. It resembles the fibroadenomas but the stromal elements tend to be more hypercellular. It is best to view this tumor as having a **low grade malignant potential. (Gyn185)**

117. Lymphedema following radical mastectomy
This slide demonstrates extensive lymph stasis in the right arm in a patient who had a radical mastectomy. This treatment removes all of the pectoralis major and minor and the axillary lymph node chain which renders the dependent extremity enable to drain lymphatic fluid. The patients are susceptible to having extensive swelling of that dependent extremity, and the potential for lymphangiosarcoma. **(Gyn1909)**

Previous | Next
Return to Top | Return to Image Index

Pathology II Images

Dermatology

It is against copyright laws to make
electronic or printed copies of these slides!!

1. Acute eczema:
Note weeping appearance of the skin surface **(Drm001)**

2. Chronic eczema:
Note the dry, hyperkeratotic skin from constant scratching **(Drm002)**

3. Atopic dermatitis in child:
Family history of IgE-mediated disease is common **(Drm003)**

4. Contact dermatitis to nickel:
Note the eczematous rash; this is type IV hypersensitivity **(Drm004)**

5. Seborrheic dermatitis (dandruff):
This is due to M. furfur **(Drm005)**

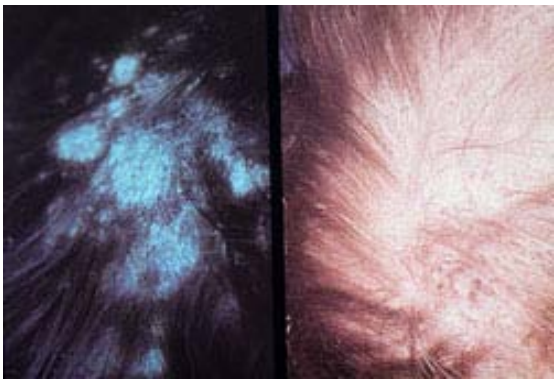

6. Tinea capitis with a positive Wood's lamp:
Microsporum canis infects the outer part of the hair shaft, hence the fluorescence. T. tonsurans is the most common cause of tinea capitis and does not fluoresce **(Drm006)**

7. Tinea corporis ("ringworm"):
Note the outer red border and clear center. T. rubrum is the most common cause. **(Drm007)**

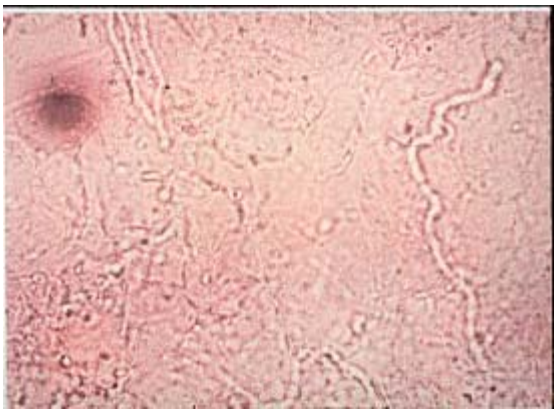

8. KOH preparation of above lesion:
Note the hyphae and yeast forms **(Drm008)**

9. Tinea versicolor:
Note the areas of pigmentation and depigmentation. It is due to M. furfur. **(Drm009)**

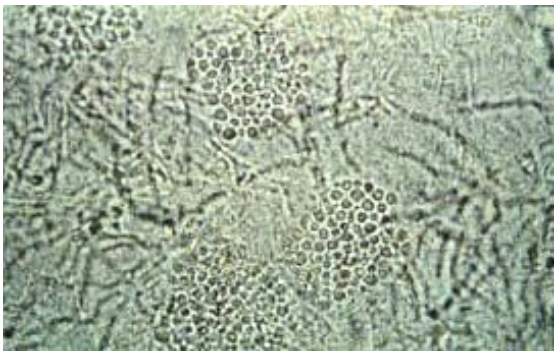

10. KOH of tinea versicolor:
Note the "sphagetti and meatball" appearance of the hyphae and yeasts of M. furfur. **(Drm010)**

Previous | Next

Return to Top | Return to Image Index

Pathology II Images

Dermatology

It is against copyright laws to make *electronic or printed* copies of these slides!!

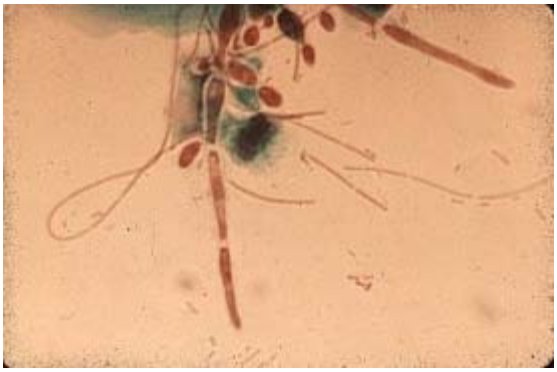

11. Pap smear of Candida albicans:
Note the pseudohyphae and yeasts. The thread-like bacteria are called Leptothrix **(Drm011)**

12. Condyloma acuminata:
Note the fern-like appearance. It is due to HPV types 6 or 11 **(Drm012)**

13. Molluscum contagiosum:
Note the crateriform lesion with a central area of umbilication **(Drm013)**

14. Child with rubeola (regular measles):
Note the diffuse maculopapular rash and runny nose **(Drm014)**

15. Coated tongue of a child with scarlet fever:
The white material will slough off and produce the classic strawberry tongue. This is a group A streptococcal infection. **(Drm015)**

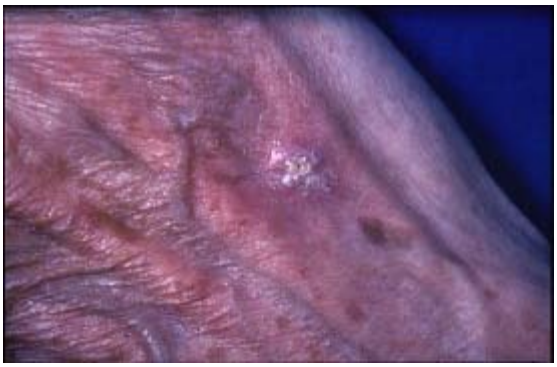

16. Actinic (solar) keratosis:
Note the pearly gray, hyperkeratotic lesion. It is a precursor for squamous cell carcinoma **(Drm016)**

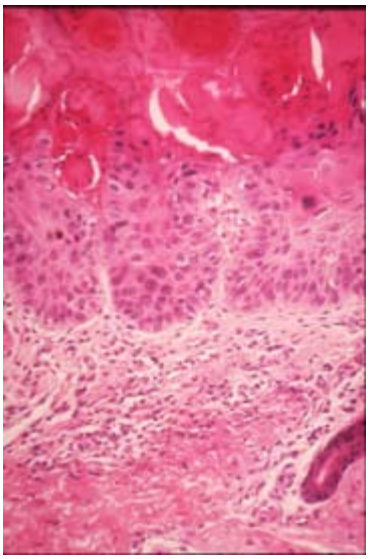

17. Actinic (solar) keratosis:
Note the hyperkeratosis corresponding with the pearly gray appearance of the above lesion. Also note the dysplastic squamous epithelium and purplish discoloration of the elastic tissue in the dermis. This is called solar elastosis. **(Drm017)**

18. Wickham's stria in a patient with lichen planus:

Note the lacy-white lesion on the buccal mucosa. **(Drm018)**

19. Psoriasis:
Note the raised red plaque with silvery scales on the surface. Pinpoint bleeding will occur if the scale is picked off (Auspitz sign). **(Drm019)**

20. Nail pitting in a patient with psoriasis (Drm020)

Previous | Next
Return to Top | Return to Image Index

Pathology II Images

Dermatology

It is against copyright laws to make *electronic or printed* copies of these slides!!

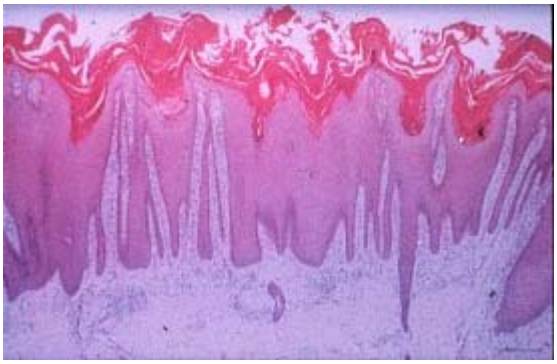

21. Histologic section of psoriasis:
Note the hyperkeratotic surface, which corresponds to the silvery scales on the skin in the lesion above. There is acanthosis and accentuation of rete ridges into the dermis. Note how close the superficial dermis comes to the surface of the scale. Can you picture scraping the scale off and pinpoint bleeding from blood vessels in the superficial dermis? **(Drm021)**

22. Oval herald patch in pityriasis rosea:
the lesion looks like tinea corporis but is not infectious **(Drm022)**

23. "Christmas tree" distribution of the rash of pityriasis rosea (Drm023)

24. Child with Herpes simplex lesions (Drm024)

25. Varicella (chickenpox):
Note the vesicular and macular lesions at different stages of development **(Drm025)**

26. Herpes zoster (shingles):
Note the dermatome distribution of the vesicular rash that has crusted over **(Drm026)**

27. Impetigo:
Note the honey-crusted lesions on the face. Group A streptococcus is most often responsible for the infection. **(Drm027)**

28. Bullous pemphigoid:
Note the bullous lesion on the skin surface. It is an autoimmune skin disease. **(Drm028)**

29. Erythema multiforme:
Note the "target cells of the skin". **(Drm029)**

30. Breast abscess due to Staphylococcus aureus (Drm030)

Previous | Next
Return to Top | Return to Image Index

Pathology II Images

Dermatology

It is against copyright laws to make
electronic or printed copies of these slides!!

31. Acne vulgaris (Drm031)

32. Acne rosacea:
Note the pustular appearance of the lesion **(Drm032)**

33. Urticaria with dermatographism:
Note the wheals (hives) in the upper slide and the ability to write on the skin surface due to the release of histamine from underlying mast cells in the skin.
(Drm033)

34. Hereditary angioedema (C1 esterase inhibitor deficiency):
Note the swelling of the face due to the release of anaphylatoxins into the skin with subsequent angioedema **(Drm034)**

35. Cellulitis with lymphangitis extending up the arm post-brown recluse spider bite (Drm035)

36. Erysipelas secondary to group A streptococcus (Drm036)

37. Butterfly rash of SLE (Drm037)

38. Lymphocutaneous nodules of sporotrichosis:
Note the puncture wound at the base of the second finger **(Drm038)**

39. Patient with lepromatous leprosy (Drm039)

40. Keratoacanthoma over the eye:
Note the cutaneous horn extending from the crater. This lesion is very often confused with squamous carcinoma. **(Drm040)**

Previous | Next

Return to Top | Return to Image Index

Pathology II Images

Dermatology

It is against copyright laws to make *electronic or printed* copies of these slides!!

41. Erythema nodosum:
Note the red nodular lesions on the anterior surface of the lower legs. These commonly occur with coccidioidomycosis and histoplasmosis. **(Drm041)**

42. Basal cell carcinoma:
Note the crateriform shape of the tumor and the ulcerated surface. The walls of the crater are erythematous from dilated blood vessels. **(Drm042)**

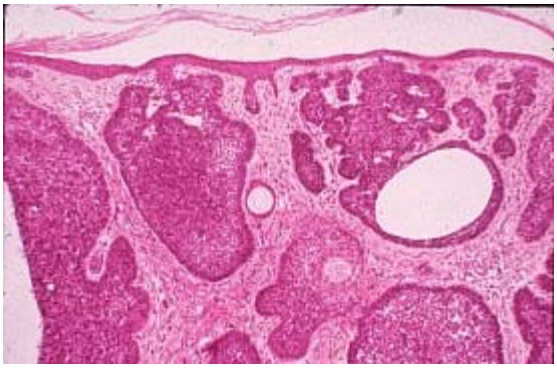

43. Basal cell carcinoma:
Note the multifocal areas of basophilic staining cells extending from the basal cell layer invading into the dermis. **(Drm043)**

44. Vitiligo:
Note the depigmented area where there has been autoimmune destruction of melanocytes **(Drm044)**

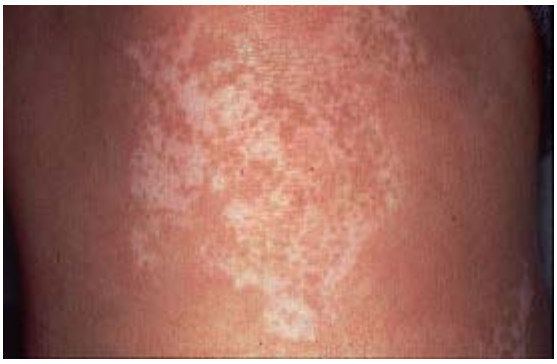

45. Seborrheic keratosis:
Note the "stuck on" appearance of this verrucoid appearing, pigmented lesion. The Leser-Trelat sign refers to a sudden outcropping of these lesions in patients with stomach adenocarcinoma. **(Drm045)**

46. Acanthosis nigricans:
Note the pigmented lesion in the axilla. It is a phenotypic marker for stomach cancer **(Drm046)**

47. Junctional nevus in a child (Drm047)

48. Superficial malignant melanoma and nodular melanoma (Drm048)

49. Lentigo malignant melanoma (Drm049)

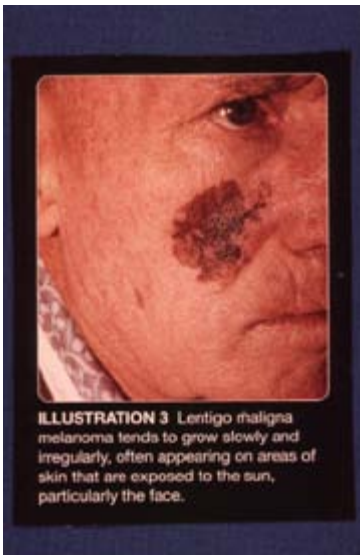

ILLUSTRATION 3 Lentigo maligna melanoma tends to grow slowly and irregularly, often appearing on areas of skin that are exposed to the sun, particularly the face.

50. Acral lentiginous malignant melanoma under the nail (Drm050)

Previous | Next

Return to Top | Return to Image Index

Pathology II Images

Endocrine

It is against copyright laws to make *electronic or printed* copies of these slides!!

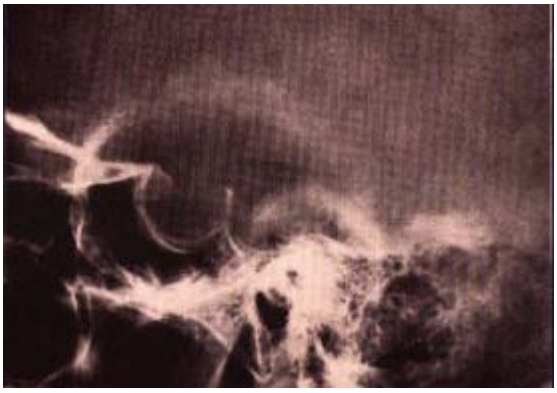

1. Skull x-ray with enlarged sella turcica due to a nonfunctioning pituitary adenoma:
The anterior and posterior clinoid processes are worn away by the expanding tumor. This is the MCC of hypopituitarism in adults. **(End001)**

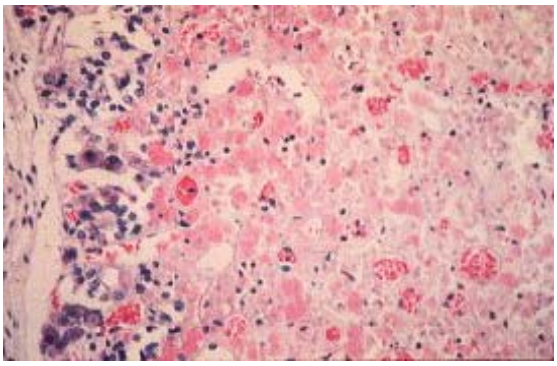

2. Coagulation necrosis of anterior pituitary gland in a woman with Sheehan's postpartum necrosis:
Note the vague outline of what used to be living tissue. Cessation of lactation is the first symptom, owing to the hyperplasia of prolactin secreting cells that occurs during pregnancy. Other signs of hypopituarism usually follow over the ensuring months. **(End002)**

3. Gross of craniopharyngioma in a child:
Note cyst spaces and hemorrhage. Calcifications are commonly noted on x-rays. This is the MCC of hypopituitarism in children. They derive from Rathke's pouch remnants. **(End003)**

4. 10 years before and after in a patient with acromegaly:
Note the thick lips and coarse features. **(End004)**

5. Normal hand on your left and large hands of acromegalic:
Lateral bone growth occurs and an increase in soft tissue related to IGF-1. **(End202)**

6. Patient with a lingual thyroid gland at the base of the tongue:
The thyroid tissue did not migrate into the neck but stayed at the foramen cecum. **(End006)**

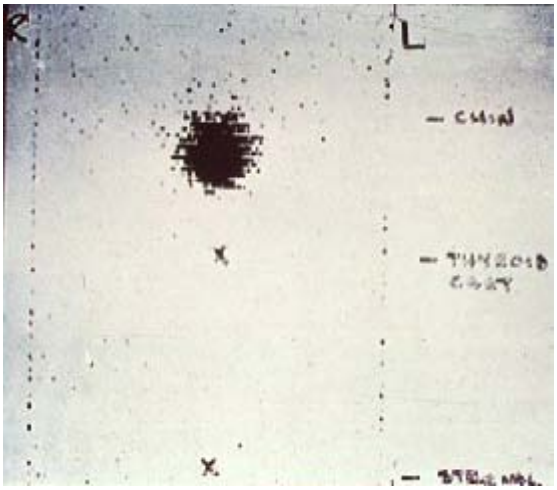

7. Thyroid scan on same patient showing uptake of the dye only at the base of the tongue:
In most cases, all the thyroid tissue is located in the lingual thyroid, hence ablation of the tissue leads to hypothyroidism. **(End007)**

8. Midline thyroglossal duct cyst:
They frequently descend through the hyoid bone, which must also be removed at surgery to remove all remnants of the cyst and foci of thyroid tissue. **(End008)**

9. Anterolateral branchial cleft cyst (End009)

10. Man with primary hypothyroidism:
Note periorbital puffiness related to GAG deposition in the periorbital tissue. **(End010)**

Previous | Next

Return to Top | Return to Image Index

Pathology II Images

Endocrine

It is against copyright laws to make *electronic or printed* copies of these slides!!

11. Woman with far advanced primary hypothyroidism (End011)

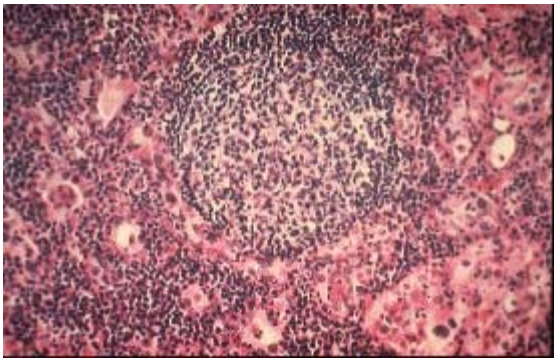

12. Microscopic of Hashimoto's thyroiditis:
Note the germinal follicle and total destruction of thyroid parenchyma. Anti-microsomal antibodies attack the cells and destroy them. An inhibitory IgG- thyroid stimulating immunoglobulin along with gland destruction produces hypothyroidism. **(End012)**

13. Woman with Graves' disease:
Note exophthalmos, thyromegaly, pretibial myxedema **(End013)**

14. Woman with Graves' disease:
Note exophthalmos **(End014)**

15. Woman with Graves' disease:
Note the diffuse thyromegaly. There may be some evidence of lid stare, since the white's of her eye appear apparent. **(End015)**

16. Man with severe ("malignant") exophthalmos:
Note the conjunctival redness and upward gaze of the eye related to ophthalmoplegia and the deposition of GAGS into the eye muscles and periorbital fat. **(End016)**

17. Elderly woman with Grave's disease manifesting as apathetic hyperthyroidism:
Patient had atrial fibrillation. Heart disease and arrhythmias are the MC findings in apathetic hyperthyroidism. **(End017)**

18. Pretibial myxedema in a patient with Graves' disease:
Due to GAG deposition in subcutaneous tissue. It is non-pitting. **(End018)**

19. Separation of distal nail in patient with Graves' disease:
Called thyroid acropachy. Like exophthalmos and pretibial myxedema, acropachy is unique to Grave's disease. **(End019)**

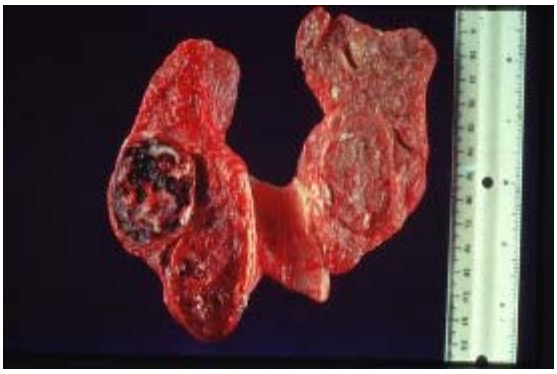

20. Gross of a multinodular goiter with hemorrhage into cysts:
Hemorrhage into a cyst causes sudden, painful enlargement of the gland. **(Hem020)**

Previous | Next

Return to Top | Return to Image Index

Pathology II Images

Endocrine

It is against copyright laws to make
electronic or printed copies of these slides!!

21. Patient with a large endemic goiter due to iodide deficiency. (End021)

22. Gross of a benign follicular adenoma:
It usually presents as a non-functional, "cold nodule". **(End022)**

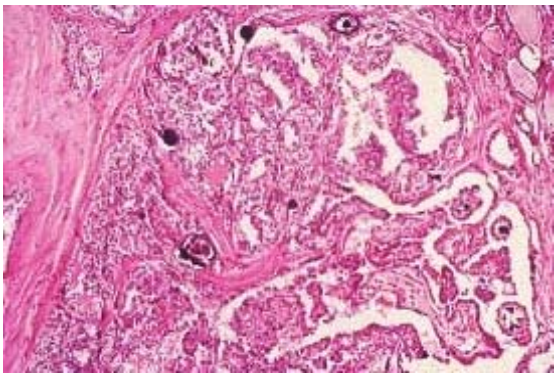

23. Microscopic of papillary carcinoma of thyroid:
Note the psammoma bodies, with represent dystrophic calcification of neoplastic cells that have undergone apoptosis. **(End023)**

24. Papillary carcinoma metastatic to a cervical lymph node. (End024)

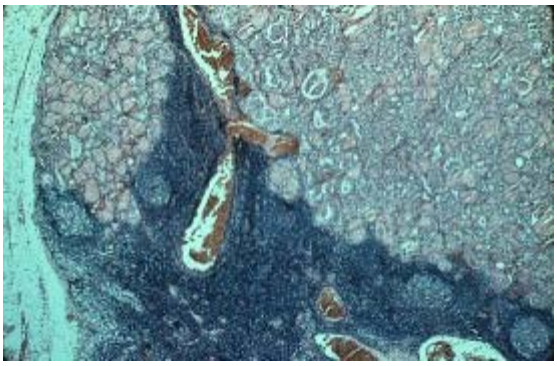

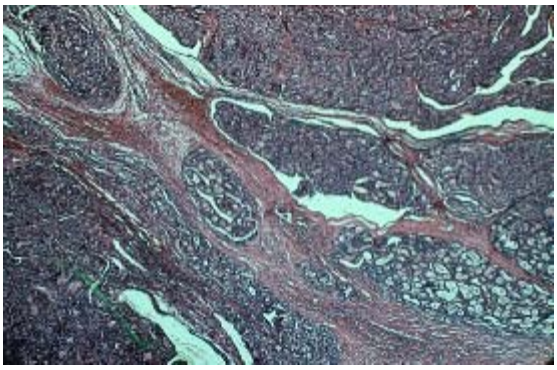

25. Follicular carcinoma invading a blood vessel:
Follicular cancers avoid the lymphatics, unlike papillary cancer. **(End025)**

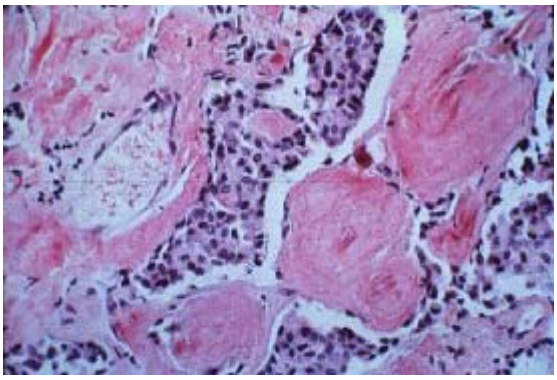

26. Medullary carcinoma of thyroid:
Pink material is amyloid derived from calcitonin. Calcitonin is the tumor marker for medullary carcinoma. Most cases are sporadic rather than familial. If this was familial, then it had to be either a MEN IIa or IIb syndrome. **(End026)**

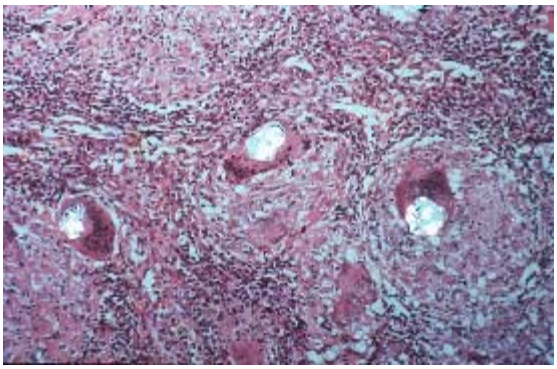

27. Polarization of amyloid in the above cancer after a Congo stain:
Note apple green birefringence, similar to a Granny Smith apple. **(End027)**

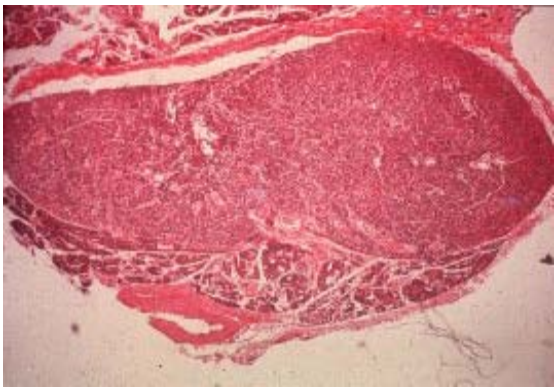

28. Microscopic of a parathyroid adenoma composed of chief cells:
Note the atrophic parathyroid tissue outside the adenoma. It is atrophic because the suppression of TSH by hypercalcemia causes normal thyroid tissue to undergo atrophy. **(End028)**

29. Microscopic appearance of a second parathyroid

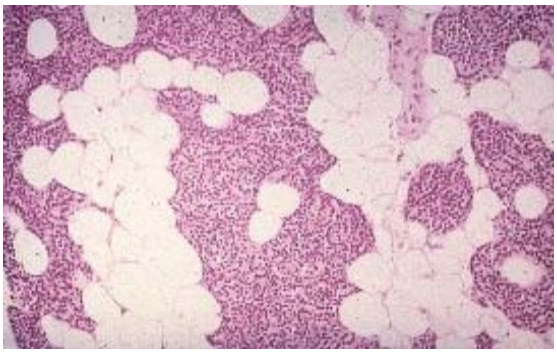

gland in the above patient: Note the increase in fatty tissue, indicating that the gland has been suppressed (hypercalcemia suppresses normal glands PTH production) and is atrophic **(End029)**

30. Patient with primary hyperparathyroidism: Note metastatic calcification in the outside rim of the cornea **(End030)**

Previous | **Next**

Return to Top | **Return to Image Index**

Pathology II Images

Endocrine

It is against copyright laws to make *electronic or printed* copies of these slides!!

31. Bone x-rays in a patient with primary hyperparathyroidism:
Note resorption of bone of the distal phalanges. Also note the cystic mass in the proximal humerus representing osteitis fibrosa cystica, a late bone finding in primary HPTH. These cysts are more commonly located in the jaw. **(End031)**

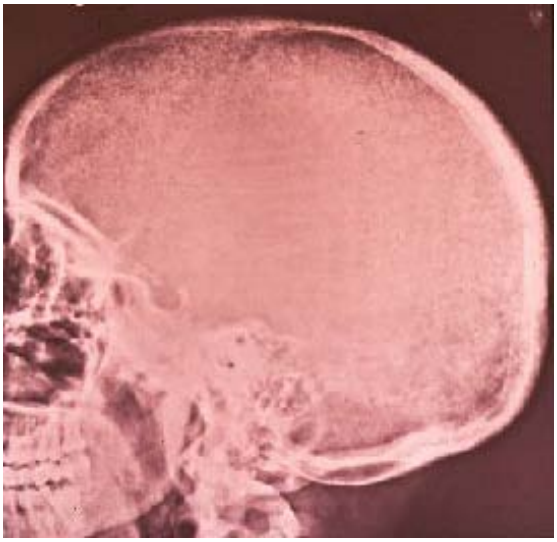

32. Skull x-ray in a patient with primary hyperparathyroidism:
Note the "salt and pepper" appearance of the bone is related to bone resorption. **(End032)**

33. Patient with carpopedal spasm due to tetany:
This is called Trousseau's sign. If the total calcium was normal, then alkalosis probably was responsible. If the total calcium was decreased, then hypoparathyroidism had to be responsible. **(End033)**

34. Gross of a functioning adrenal cortical adenoma (adrenal Cushing's):
Note the atrophy of the residual adrenal gland. This is another example of suppression of normal gland tissue in hyperfunctioning adenoma. In this case, cortisol suppressed pituitary ACTH, which caused normal adrenal cortex fasciculata and reticularis to undergo atrophy. **(End034)**

35. Man with pituitary Cushing's before (your left) and after surgery (your right) (End035)

36. Woman with pituitary Cushing's before (your left) and after surgery (your right) (End036)

37. Woman with Cushing's and purple stria:
Also note the large ecchymoses on the upper arm. This is due to vessel instability from excess cortisol weakening collagen. This woman does not demonstrate the thin extremities often seen in Cushing's. **(End037)**

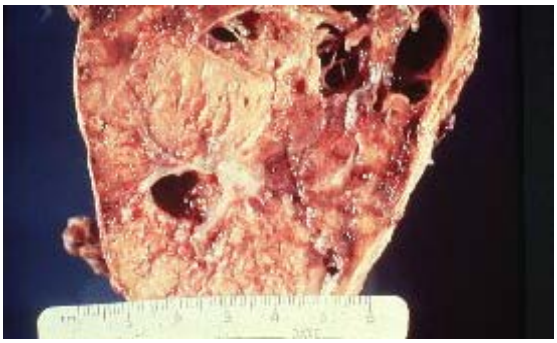

38. Gross of a pheochromocytoma:
Note the brown discoloration (called a chromaffin tumor) and cystic spaces, most likely related to hemorrhagic necrosis. The majority are benign and unilateral. **(End038)**

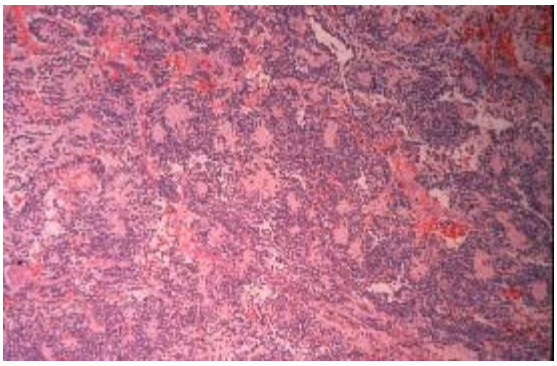

39. Microscopic of a neuroblastoma:
Note small, hyperchromatic cells (they stain positive for S100 antigen, indicating neural crest origin). Also note the Homer-Wright rosettes (pink material surrounded by small blue cells). **(End039)**

40. Hyperpigmentation of the buccal mucosa in a patient with Addison's disease (End040)

Previous | Next
Return to Top | Return to Image Index

Pathology II Images

Endocrine

It is against copyright laws to make
electronic or printed copies of these slides!!

41. Hyperpigmentation of the gums in a patient with Addison's disease (End041)

42. Hyperpigmentation of the flexor creases in the hands in a patient with Addison's disease (End042)

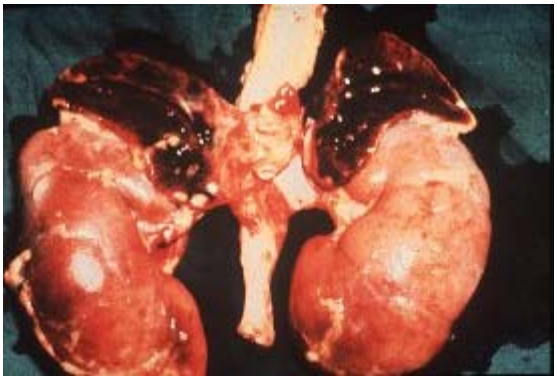

43. Hemorrhage into the adrenal glands in a patient with Waterhouse-Friderichsen's syndrome due to Neisseria meningitidis:
The hemorrhagic infarction of the glands is due to DIC. **(End043)**

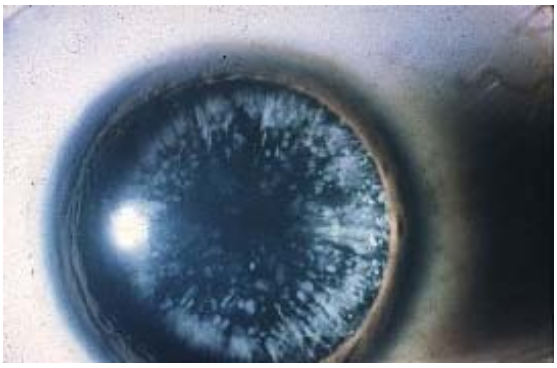

44. Snow flake cataract in a patient with diabetes mellitus:
Due to osmotic damage **(End044)**

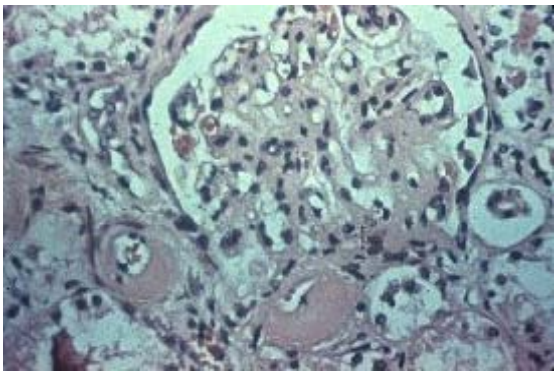

45. Microscopic of a glomerulus in a patient with diabetes mellitus (nodular glomerulosclerosis):
Note the hyaline arteriolosclerosis of the afferent/efferent arterioles (due to non-enzymatic glycosylation)
(End045)

46. Retina in a diabetic showing microaneurysms (red dots):
Due to osmotic damage of pericytes **(End274)**

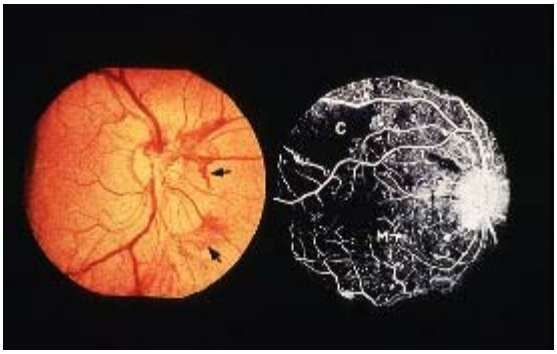

47. Retina in a diabetic showing neovascularization (arrows, proliferative retinopathy).
Ophthalmologists use various dyes to demonstrate microaneurysms better so they can be lasered.
(End047)

Previous | **Next**

Return to Top | **Return to Image Index**

Pathology I Images

Syllabus | Lecture Schedule | Images - Pathology I | Images - Pathology II

Musculoskeletal

1 | 2 | 3 | 4 | 5

It is against copyright laws to make
electronic or printed copies of these slides!!



1. Synovial fluid tubes:
From left to right, #1 normal, #2 noninflammatory (e.g., osteoarthritis), #3 inflammatory (e.g., rheumatoid arthritis), #4 septic (e.g., gonococcal septic arthritis), #5 hemorrhage (e.g., trauma, hemophilia A) **(MS001)**

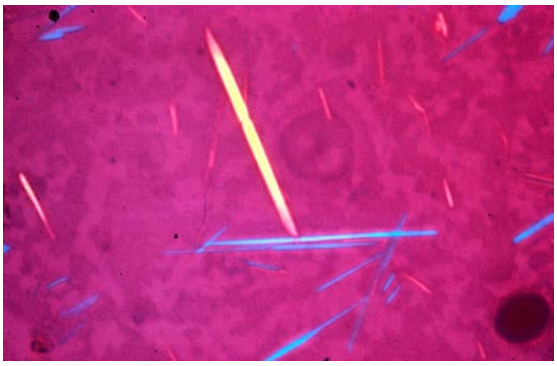

2. Synovial fluid crystals with red filter in place
(1) Crystals are monoclinic (needle shaped) and could be either monosodium urate or calcium pyrophosphate, (2) if crystal is yellow when parallel to the slow ray of the compensator, it is monosodium urate and defines negative birefringence, (3) if crystal is blue when parallel to the slow ray of the compensator, it calcium pyrophosphate and defines positive birefringence **(MS002)**

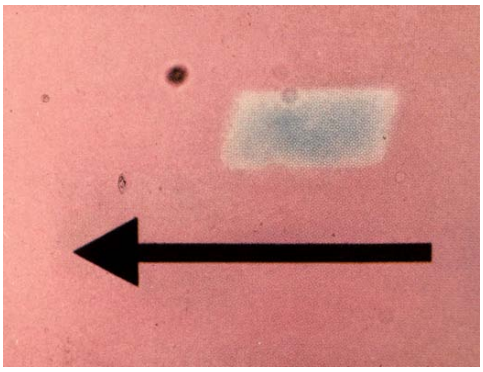

3. Synovial fluid crystal
Triclinic (rhomboid shaped) crystal is always calcium pyrophosphate, note that it is blue when parallel to the slow ray of the compensator (black arrow) **(MS003)**

4. Osteoarthritis
Blue stains cartilage and red bone, note how the articular cartilage is worn down and fibrillated in areas (perpendicular cracks), note the osteophyte at the margin of the joint **(MS004)**

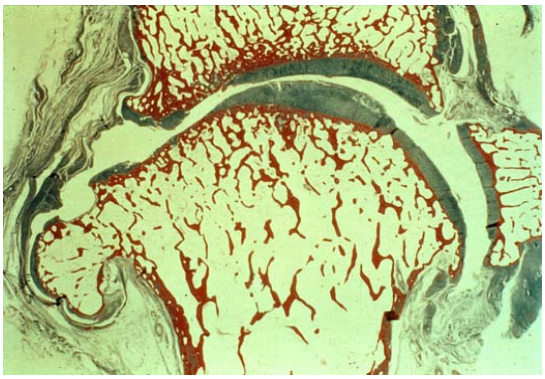

5. Osteoarthritis
X-ray of head of femur removed at surgery, note the subchondral bone cysts beneath the surface **(MS005)**

6. Osteoarthritis
Note the enlargement of the DIP (Heberden's nodes) and PIP joints (Bouchard's nodes), enlargements represent osteophytes **(MS006**)

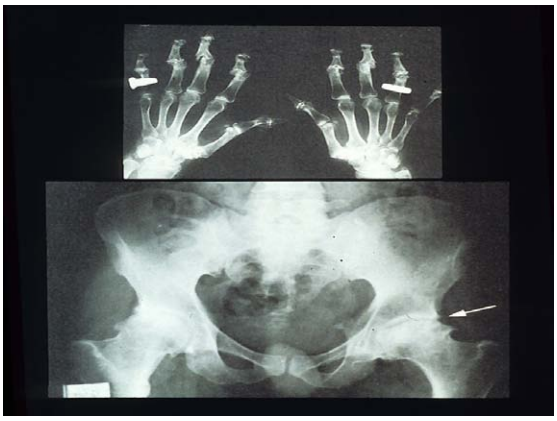

7. Osteoarthritis
Note x-ray of hands and OA in the DIP and PIP joints, note the narrow joint space in the femoral joint and sclerotic changes **(MS007**)

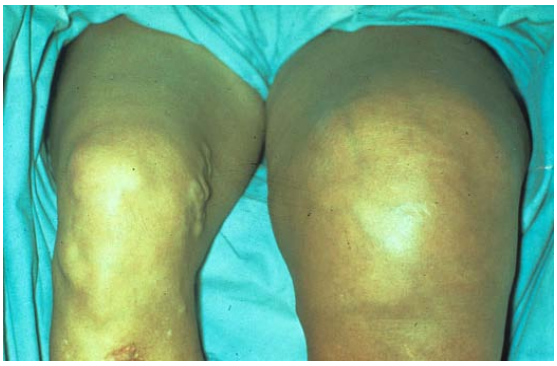

8. Charcot (neuropathic) joint
Note enlarged knee on your right (patient left knee) **(MS008)**

9. Rheumatoid arthritis (RA)
note the enlarged MCP joints **(MS009)**

10. RA
Note symmetrical involvement in both hands with enlarged MCP joints and ulnar deviation **(MS010)**

Previous | Next

Return to Top | Return to Image Index

Pathology I Images

Musculoskeletal

It is against copyright laws to make
electronic or printed copies of these slides!!

11. RA
Boutonniere deformity of digit - note extension of DIP joint and flexion of PIP joint **(MS011)**

12. RA
Swan-neck deformity of digit - note flexion of DIP joint and extension of PIP joint **(MS012)**

13. RA
Rheumatoid nodules on extensor surface of forearm, example of fibrinoid necrosis (same lesions seen in acute rheumatic fever) **(MS013)**

14. Gout
Note inflamed first metatarsophalangeal joint (big toe) **(MS014)**

15. Gout
Note large tophus on malleolus and along margin of the foot, sign of chronic gout, composed of crystalline

material (H and E shows multinucleated giant cell reaction to the MSU crystals) **(MS015)**

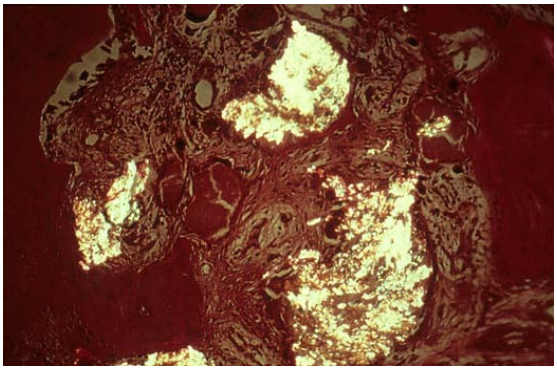

16. Gout
Polarization of tophus showing MSU crystals **(MS016)**

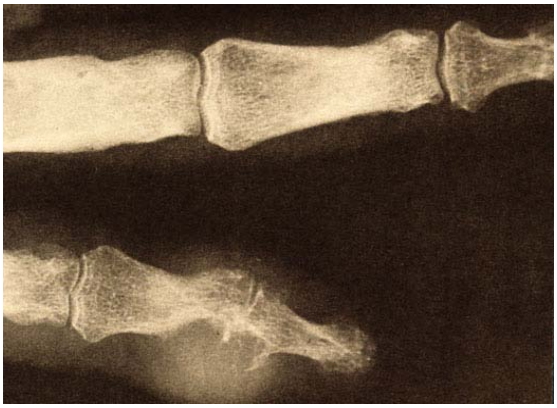

17. Gout
X-ray of digit showing erosive joint disease in bottom digit **(MS017)**

18. Chondrocalcinosis
Note the linear density in the articular cartilage representing pseudogout crystal deposition **(MS018)**

19. Synovial fluid
neutrophil with phagocytosed triclinic crystal representing calcium pyrophosphate **(MS019)**

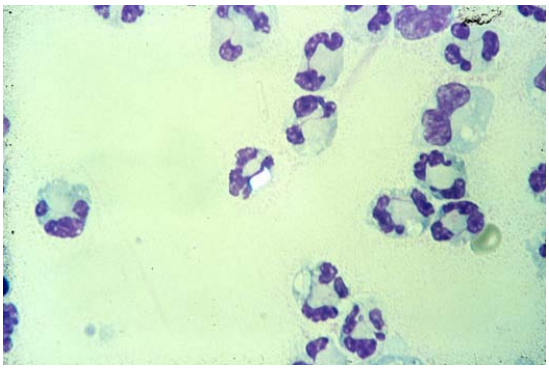

20. Ankylosing spondylitis (AS)
Note anterior flexion which often results in restrictive lung disease **(MS020)**

Previous | **Next**

Return to Top | **Return to Image Index**

Pathology I Images

Musculoskeletal

It is against copyright laws to make *electronic or printed* copies of these slides!!

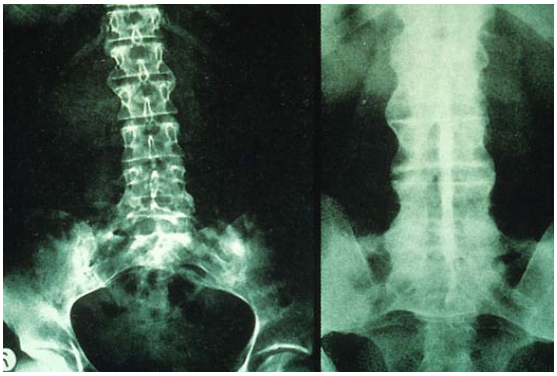

21. AS
Note sclerotic change in both sacroiliac joints in left screen and fused vertebral column (bamboo spine) in right screen **(MS021)**

22. Reiter's syndrome
Patient with non-infectious conjunctivitis, previously had Chlamydia trachomatis infection and then developed conjunctivitis and arthritis (HLA B27 positive) **(MS022)**

23. Psoriatic arthritis
Note disabling arthritis of the hands, nail pitting is commonly present (not present in photo) **(MS023)**

24. Psoriatic arthritis
X-ray with "pencil in cup" deformity from erosive arthritis of digits **(MS024)**

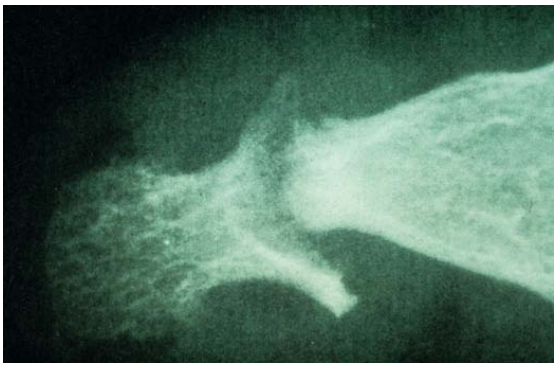

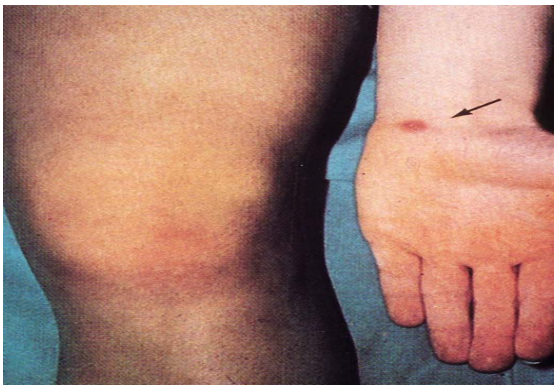

25. Septic arthritis due to disseminated gonococcemia
Note the hot knee and the pustule on the wrist **(MS025)**

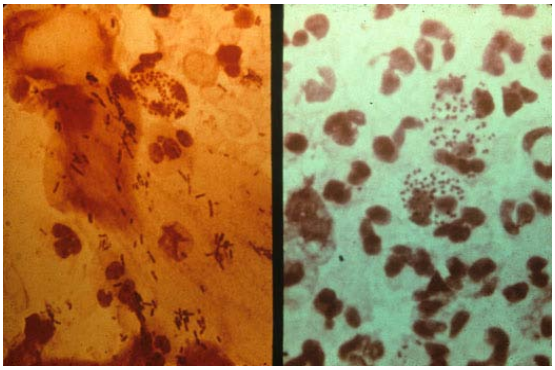

26. Septic arthritis
Note the gram negative diplococci in the neutrophil (screen on your right) **(MS026)**

27. Lyme's disease
Note the Ixodes tick (vector of Borrelia burgdorferi and Babesia microti), note the erythematous rash in the bottom screen - the tick bite is in the center of the rash and the rash extends out in concentric circles from that point, the rash is called erythema chronicum migrans **(MS027)**

28. Ganglion
Note the cystic mass on the wrist, ganglions are cysts arising from the synovium or the tendon sheath, they recurs unless removed surgically **(MS028)**

29. Pericardial fluid

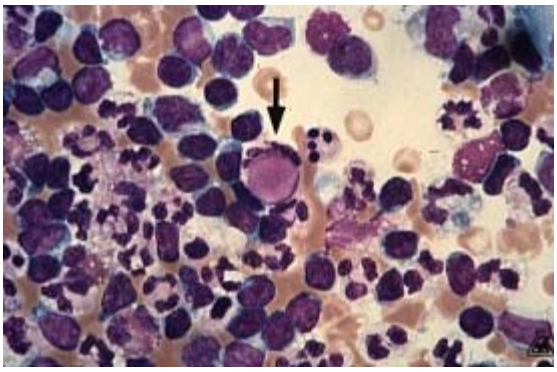

Note the LE cell in the center of the slide, LE cells are altered DNA phagocytosed by a neutrophil, pericarditis/effusion is the most common cardiac manifestation of SLE **(MS029)**

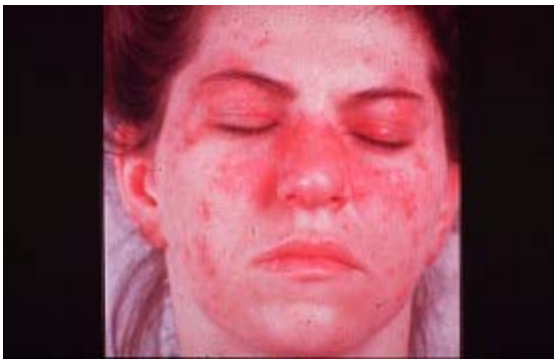

30. SLE: malar rash **(MS030)**

Previous | **Next**

Return to Top | **Return to Image Index**

Pathology I Images

Musculoskeletal

It is against copyright laws to make
electronic or printed copies of these slides!!

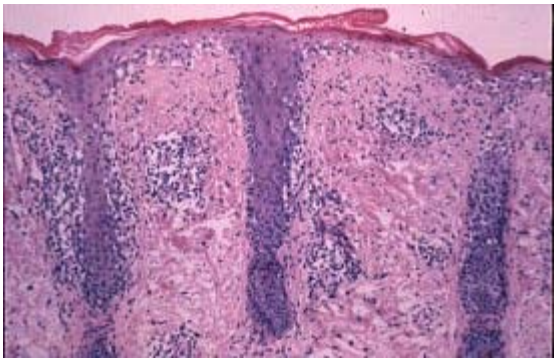

31. SLE
Histologic section of skin showing the lymphocytic infiltrate hugging the basal layer and the outer portion of the hair follicles (causes alopecia) **(MS031)**

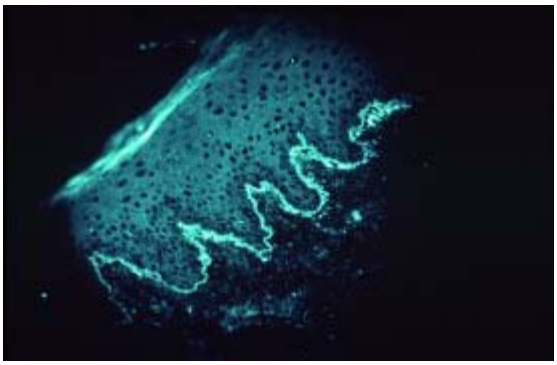

32. SLE
Fluorescent staining for DNA in this skin biopsy shows a linear deposit of DNA along the basement membrane corresponding the site where lymphocytes are attacking the membrane, this is called the band test **(MS032)**

33. PSS
Sclerodactyly and digital infarcts in progressive systemic sclerosis **(MS033)**

34. PSS
Tight facial features of PSS, note the telangiectasias on the skin **(MS034)**

35. PSS
Raynaud's phenomenon in PSS, note color variations **(MS035)**

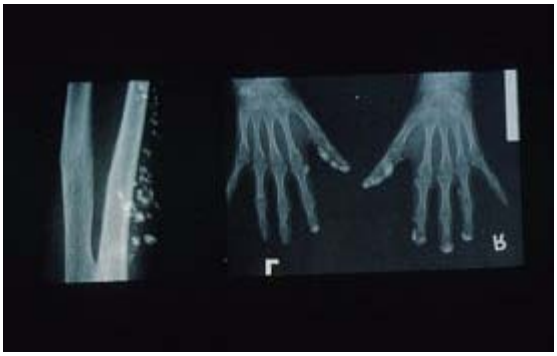

36. PSS
X-ray of hand and forearm showing extensive dystrophic calcification (calcinosis) **(MS036)**

038.jpg (12265 bytes)

37. Dermatomyositis (DM)
Note the history in this 10 yr old girl, Gottron's patches are noted over the PIP joints and the purplish discoloration around the eyes are characteristic features, muscle biopsy shows a lymphocytic infiltrate, CK levels are always increased **(MS037)**

38. Sjogren's syndrome
Note dry tongue from immune destruction of minor salivary glands **(MS038)**

39. Osteogenesis imperfecta
AD disorder with defect in synthesis of type I collagen, note the blue sclera- loss of collagen in sclera allows bluish color of choroidal vessels to shine through **(MS039)**

40. Osteoporosis
Note the collapse of the vertebra due to loss of bone mass, postmenopausal osteoporosis is due to the loss of the inhibitory effect of estrogen on the release of interleukin 1 from osteoblasts; hence patients lose more bone than is replaced **(MS040)**

Previous | Next

Return to Top | Return to Image Index

Pathology I Images

Musculoskeletal

It is against copyright laws to make *electronic or printed* copies of these slides!!

41. Osteoporosis
Dowager's hump
(MS239)

42. Aseptic necrosis of femoral head
Note the reactive bone formation; causes include femoral neck fracture, corticosteroids, sickle cell disease, Legg-Perthes disease
(MS042)

43. Clubbing of the fingers
Hypertrophic osteoarthropathy in the underlying digit is causing this reaction, noted in chronic lung diseases and cancer
(MS043)

44. Exostoses (osteochondroma)
Note the cartilaginous cap on the surface of the bone. This causes a protuberance of the bone. This is the most common benign bone tumor. **(MS044)**

45. Chondrosarcoma of the hip (MS045)

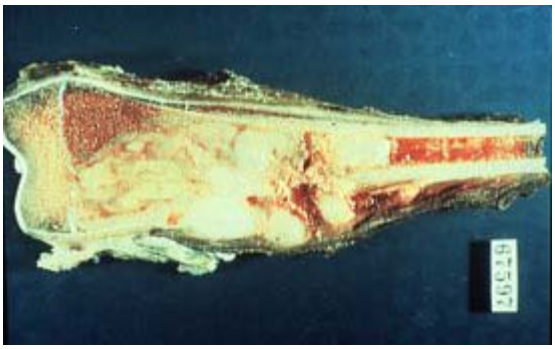

46. Osteogenic sarcoma
Note metaphyseal origin of the cancer and extension into the muscle, note the splinter of periosteum that is elevated which would correspond to Codman's triangle **(MS046)**

47. Osteogenic sarcoma
X-ray of proximal humerus showing the "sunburst" appearance of osteogenic sarcoma that is extending into the muscle, osteogenic implies that the cancer is making bone **(MS047)**

48. Neurogenic atrophy

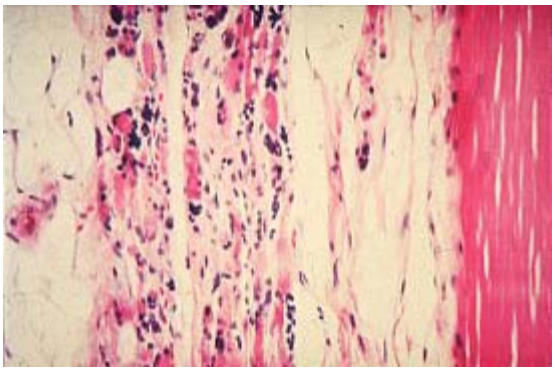

Note atrophy of the muscle bundles secondary to denervation **(MS048)**

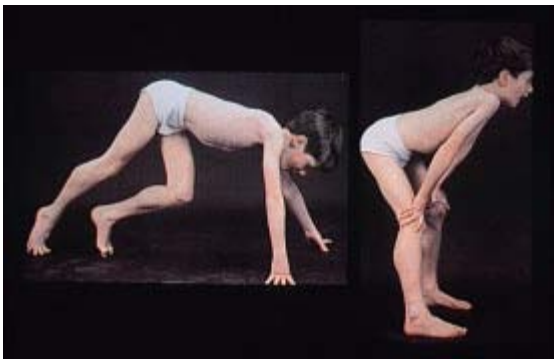

49. Duchenne's muscular dystrophy
Note the pseudohypertrophy of the calf muscles, the child is pushing himself up from the down position (Gower's maneuver), SXR disease with deficiency of dystrophin **(MS049)**

50. Myotonic dystrophy
AD disorder that is a triplet repeat (problem with anticipation - disease gets worse in future generations), note balding head and sagging face, patient's cannot relax their grip on something, cardiac disease/cataracts/ testicular atrophy are also present **(MS291)**

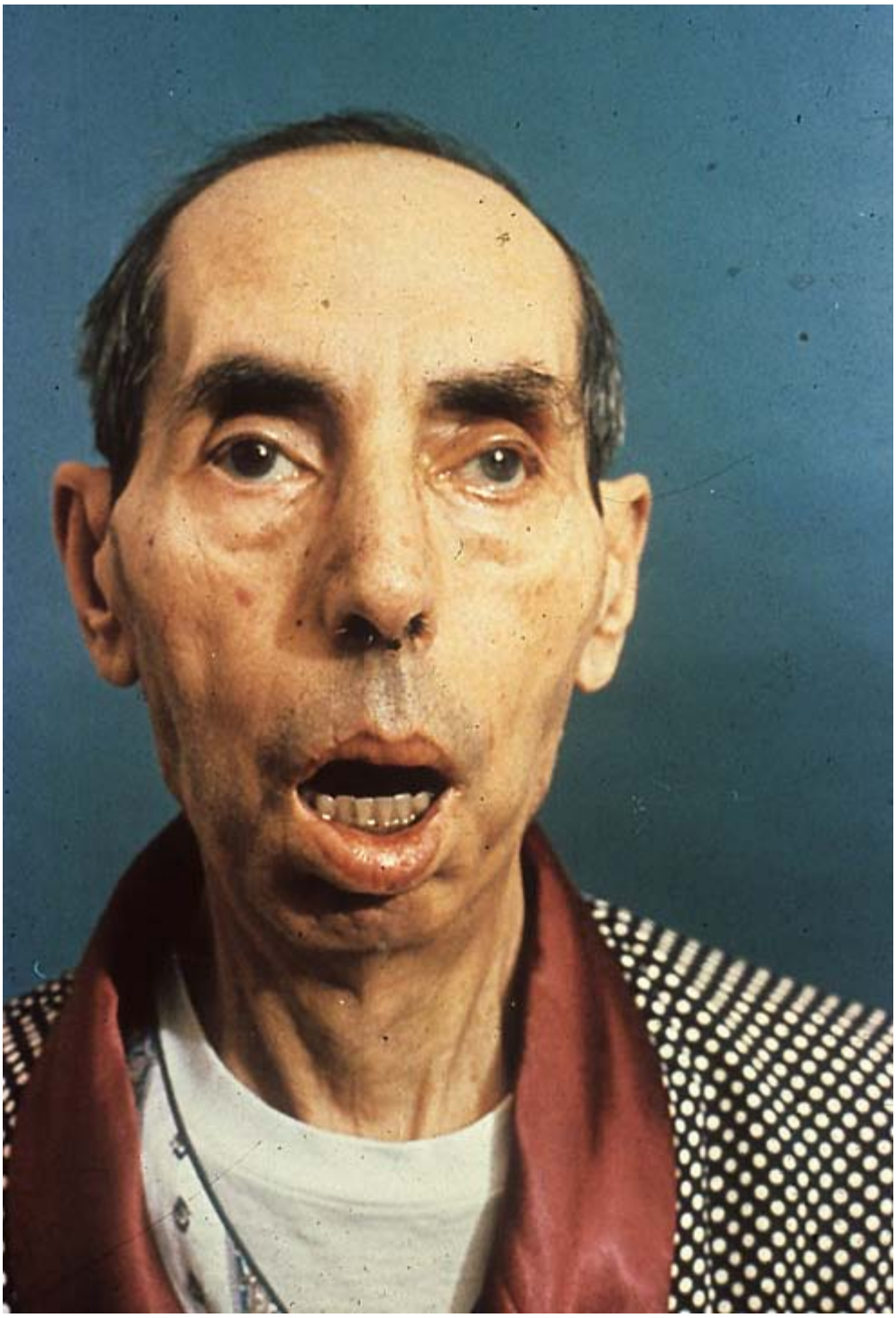

051.jpg (17887 bytes)

51. Myasthenia gravis
Autoantibody against Ach receptors, note lid lag on your left and open eyes after administration of Tensilon (acetylcholinesterase inhibitor) - blocking acetylcholine esterase allows a buildup of Ach, which stimulates existing receptors **(MS051)**

Previous | **Next**

Return to Top | **Return to Image Index**

Pathology II Images

Central Nervous System

It is against copyright laws to make *electronic or printed* copies of these slides!!

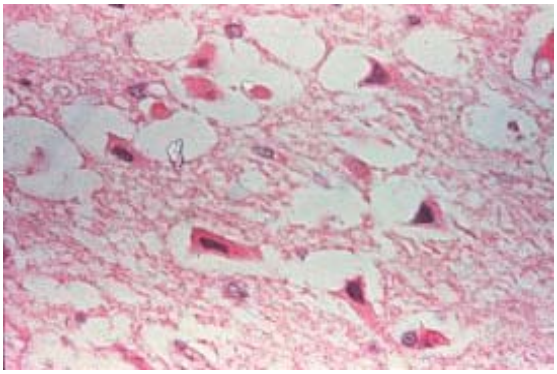

1. Dead neurons in the cerebral cortex illustrating apoptosis (individual cell necrosis)
Note the absence of inflammation, eosinophilic cytoplasm, and pyknotic nucleus. This patient had cerebral atrophy from ischemia. **(CNSOO1)**

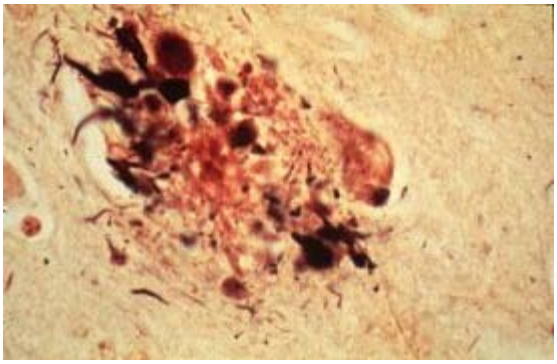

2. Silver stain of a senile plaque in a patient with Alzheimer's disease
The outside part of the plaques is degenerated parts of neurons and the center, if stained for amyloid, would be positive indicating the presence of b-amyloid protein coded by chromosome 21. **(CNSOO2)**

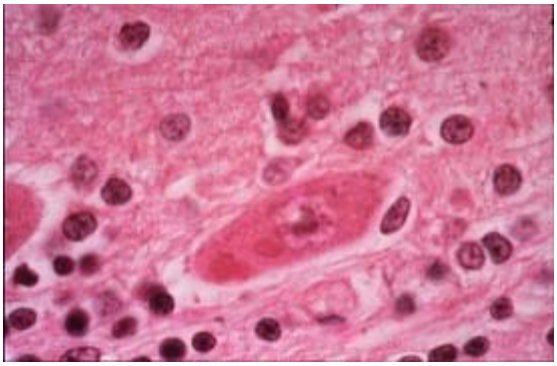

3. Cerebellar Purkinje cell with an eosinophilic viral inclusion (Negri body) in a patient who died of rabies. (CNSOO3)

4. Newborn with a noncommunicating hydrocephalus from stenosis of the aqueduct of Sylvius. (CNSOO4)

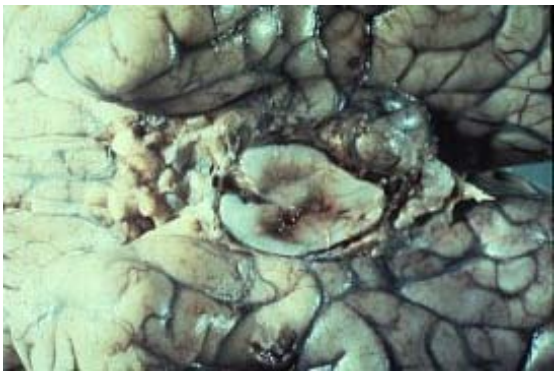

5. Cross-section through midbrain illustrating Duret's hemorrhages secondary to uncal herniation of the temporal lobe through the tentorium cerebelli
CN III palsy (eye down and out, mydriasis of pupil, ptosis of the eyelid) and compression of the posterior cerebral artery (hemorrhagic infarction of the occipital lobe) may also occur. **(CNSOO5)**

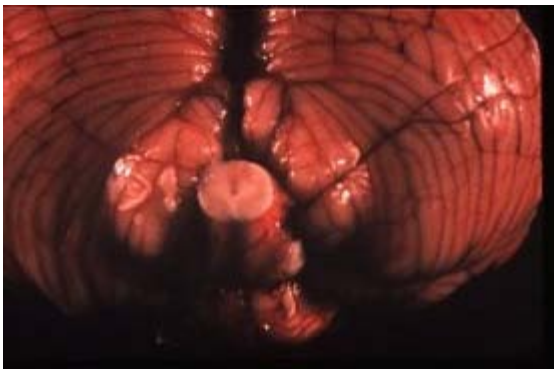

6. Herniation of the cerebellar tonsils through the foramen magnum. (CNS006)

7. Anencephaly, the worst of the open neural tube defects
Note the absence of the brain. The fetal adrenal cortex is also absent. **(CNS007)**

8. CafÃ©-au-lait spot and axillary freckling consistent with neurofibromatosis (AD disease).
CNS lesions include meningiomas, acoustic neuromas, and optic gliomas. **(CNSOO8)**

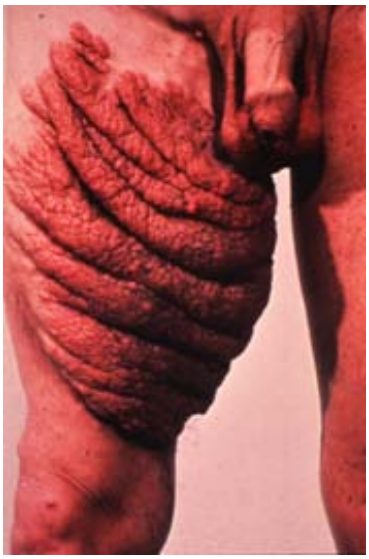

9. Plexiform neurofibroma in a patient with neurofibromatosis. (CNS009)

10. Sturge Weber syndrome (AD disease) with port wine stain in the distribution of the ophthalmic and maxillary division of CN V.
Patients have an ipsilateral AV malformation with tram tracking (vessel calcification). They frequently suffer epileptic seizures and are mildly mentally retarded. **(CNS010)**

Previous | Next

Return to Top | Return to Image Index

Pathology II Images

Central Nervous System

It is against copyright laws to make *electronic or printed* copies of these slides!!

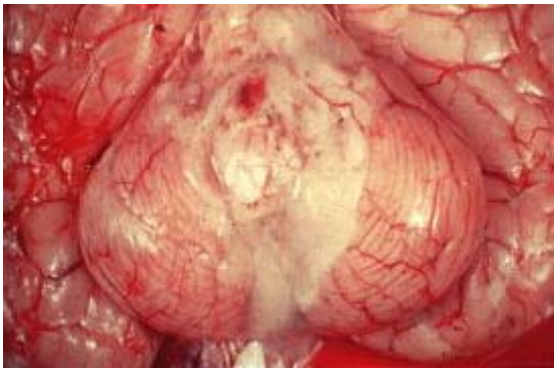

11. Creamy exudate at the base of the brain in a patient with bacterial meningitis. (CNS011)

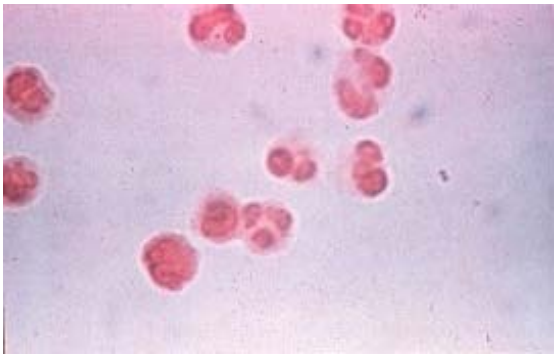

12. CSF gram stain showing neutrophils and a single Gram negative diplococcus, representing Neisseria meningitidis, the most common cause of meningitis from 1 month to 18 years of age. (CNS012)

13. Sections through the brain of a child who died of congenital CMV showing periventricular calcification (dystrophic calcification)
CNS calcification may also occur with congenital toxoplasmosis and congenital Herpes. **(CNS013)**

14. Cerebral abscess
Note the shaggy wall of the abscess. This, like CNS infarction, is an example of liquefactive necrosis. **(CNS014)**

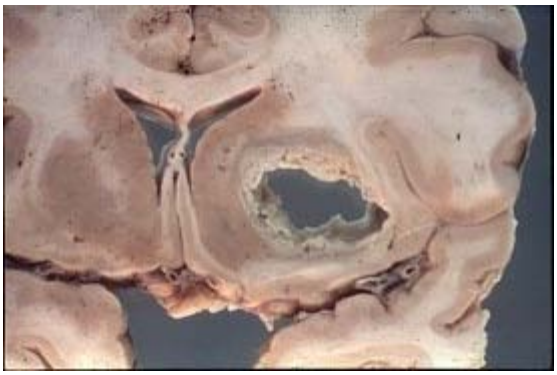

15. Woman with Herpes zoster involving the ophthalmic division of CN V. **(CNS015)**

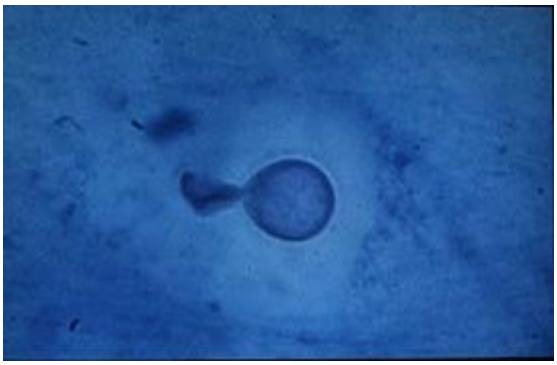

16. India ink preparation of CSF showing Cryptococcus neoformans (most common cause of CNS fungal disease in immunocompromised patients)
Note the narrow-based bud and clear area around the yeast representing the thick capsule.CNS 016: India ink preparation of CSF showing Cryptococcus neoformans (most common cause of CNS fungal disease in immunocompromised patients). Note the narrow-based bud and clear area around the yeast representing the thick capsule. **(CNS016)**

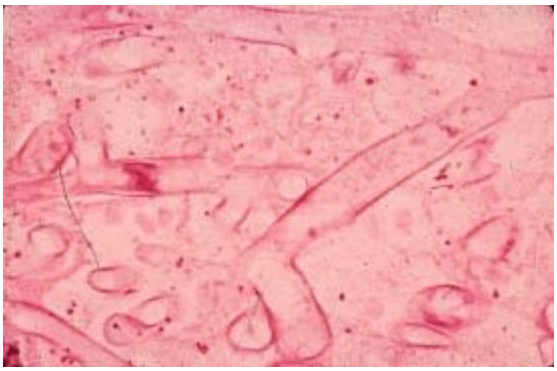

17. Wide-angled, non-septate hyphae of Mucor in a patient with diabetic ketoacidosis. (CNS017)

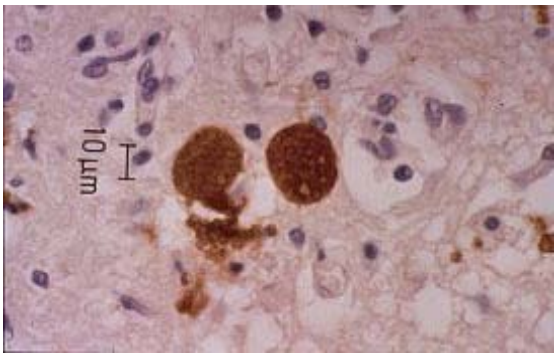

18. Monoclonal stain of the brain illustrating cysts of Toxoplasma gondii, the most common cause of a space-occupying lesion in the brain in a patient with AIDS. (CNS018)

19. Multiple spaces in the CNS representing cysts in a patient with cysticercosis due to Taenia solium.

Recall that in cysticercosis, the egg of the tapeworm is ingested by the patient and the egg develops into larvae (cysticerci), which gain access to the blood stream and disseminate to the CNS and other sites. These patients commonly have epileptic seizures. **(CNS019)**

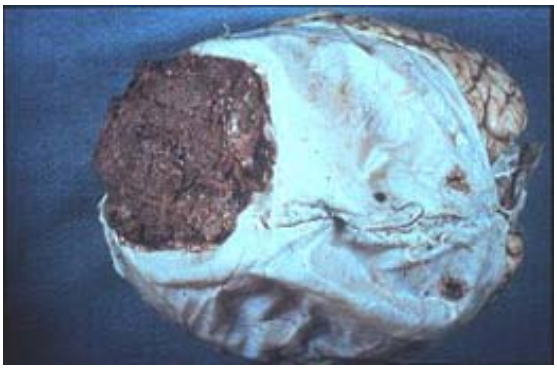

20. Epidural hematoma
Note the arterial blood clot on top of the dura. It is due to a fracture of the temporoparietal bone with rupture of the middle meningeal artery, which under arterial pressure creates an epidural space. **(CNS020)**

Previous | **Next**

Return to Top | **Return to Image Index**

Pathology II Images

Central Nervous System

It is against copyright laws to make
electronic or printed copies of these slides!!

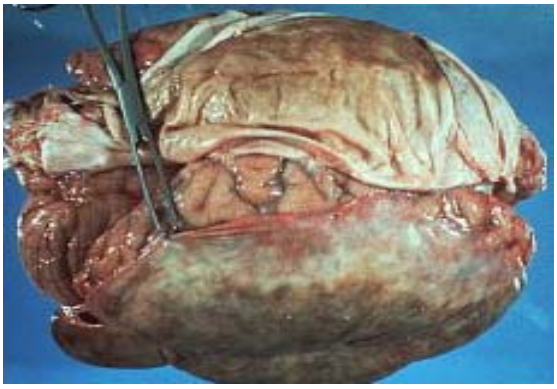

21. Subdural hematoma
Note that the dura is reflected back from the clot, which is held on the leading edge by forceps. Subdural hematomas are most often seen in patients with cerebral atrophy who hit their head causing rupture of one or more of the bridging veins between the dura and arachnoid membranes. **(CNS021)**

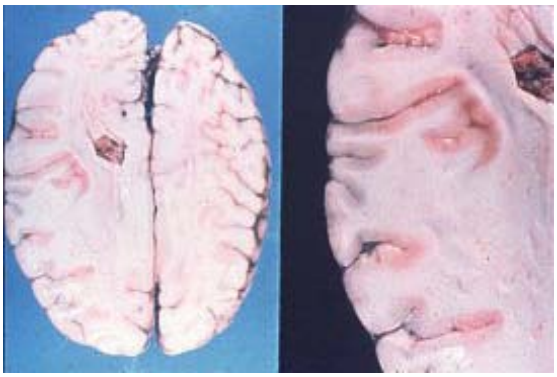

22. Pale CNS infarction due to a platelet clot overlying an atherosclerotic plaque at the bifurcation of the internal carotid artery
Note the asymmetry of the left side of the brain from edema. The close-up shows early loss of the normally well defined demarcation between gray and white mater and some early liquefactive necrosis in the white mater. **(CNS022)**

23. Old CNS atherosclerotic infarct demonstrating cystic cavities devoid of brain tissue. (CNS023)

24. Embolic stroke
Embolic strokes are most often secondary to an embolus (clot, vegetation) from the left side of the heart to the middle cerebral artery causing a hemorrhagic infarction. Note how the blood extends to the surface of the brain. The infarct is hemorrhagic owing to reperfusion of the vessel once the clot is dissolved in the middle cerebral artery. Most atherosclerotic infarcts are pale because they do not reperfuse. **(CNS024)**

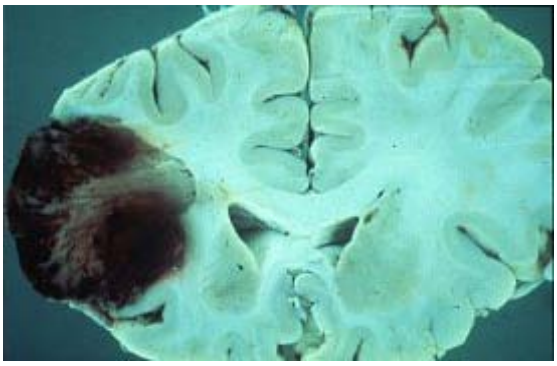

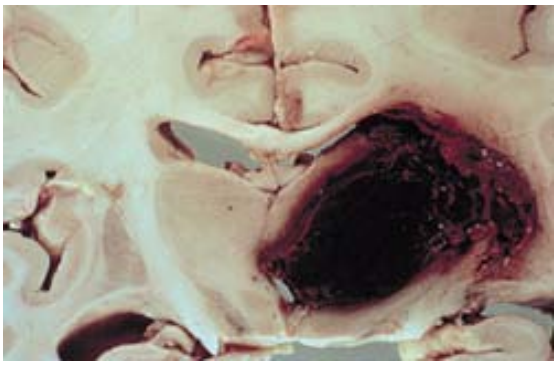

25. Hypertensive (intracerebral) bleed
Note the location of the clot (not infarct) in the putamen/globus pallidus/internal capsule area of the brain. Recall than in hypertension the lenticulostriate vessels (derivatives of the middle cerebral artery) develop Charcot-Bouchard aneurysms and these aneurysms rupture producing the intracerebral clot. **(CNS025)**

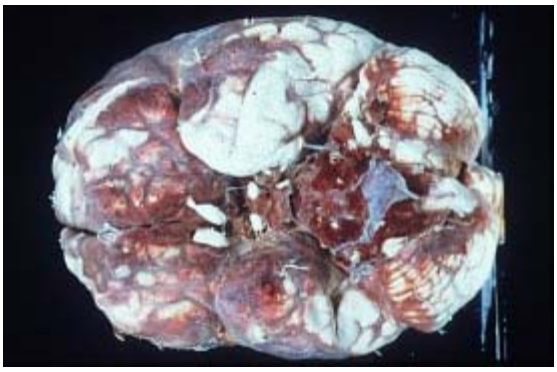

26. Subarachnoid hemorrhage in a patient with a rupture of a congential berry aneurysm located at the junction of the anterior communicating branch with the anterior cerebral artery.
Blood covers the surface of the brain. Recall the relationship of these aneurysms with coarctation of the aorta and adult polycystic kidney disease. **(CNS026)**

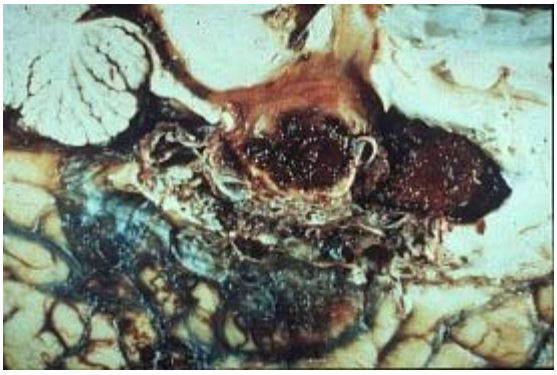

27. AV malformation of the middle cerebral artery
These lesions commonly rupture and produce subarachnoid hemorrhages. This patient may have had Sturge Weber syndrome. **(CNS027)**

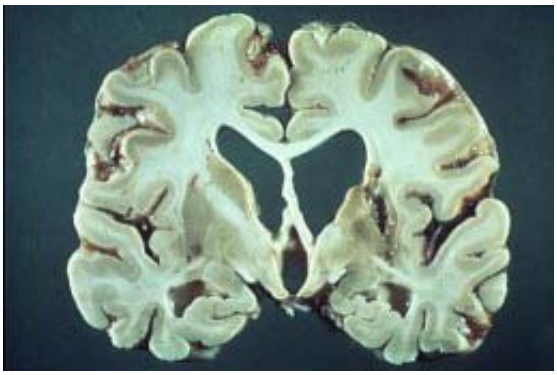

28. Lacunar infarcts in the area of the internal capsule
These are small infarcts associated with hyaline arteriolosclerosis of vessels in the setting of diabetes mellitus and essential hypertension. The unique characteristic of these types of strokes is that they tend to be pure motor or pure sensory strokes. **(CNS028)**

29. Demyelinating plaques at the angles of the

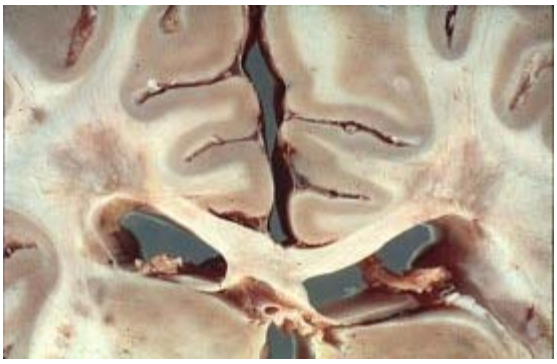

ventricles in a patient with multiple sclerosis. (CNS029)

30. Severe atrophy of the brain in a patient with Alzheimer's disease
Note that large ventricles (hydrocephalus ex vacuo) that are due to loss of brain substance rather than increased pressure. **(CNS030)**

Previous | **Next**

Return to Top | **Return to Image Index**

Pathology II Images

Central Nervous System

It is against copyright laws to make *electronic or printed* copies of these slides!!

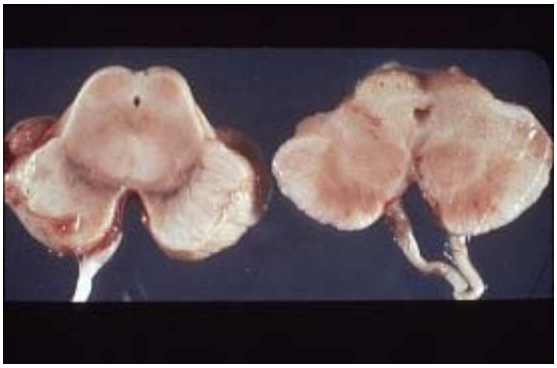

31. Substantia nigra in a patient with Parkinson's disease
Note the depigmentation of the substantial nigra. **(CNS031)**

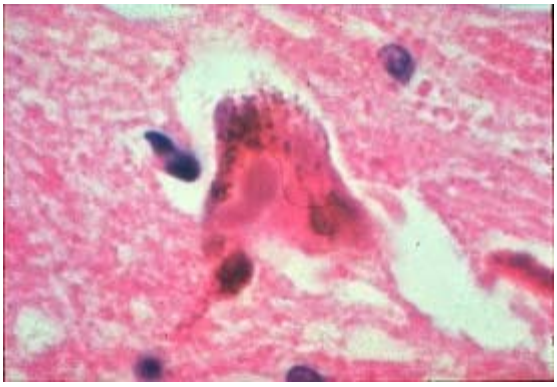

32. Depigmented neuron (normally synthesize dopamine) in the substantia nigra in a patient with Parkinson's disease showing eosinophilic inclusions representing Lewy bodies. (CNS032)

33. Static photograph of a patient with Parkinson's disease showing the blank face, stooped posture and what would be a resting tremor of the thumb and forefinger (pill rolling). Remember that the problem is one of muscle rigidity and not spasticity (UMN sign). **(CNS033)**

34. Mamillary bodies illustrating hemorrhages with hemosiderin deposition in a patient with Wernicke's encephalopathy (alcoholic with thiamine deficiency). (CNS034)

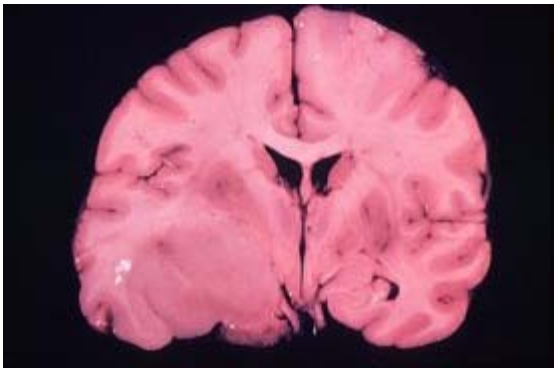

35. Brain showing asymmetry in the left hemisphere secondary to a low-grade astrocytoma. (CNS035)

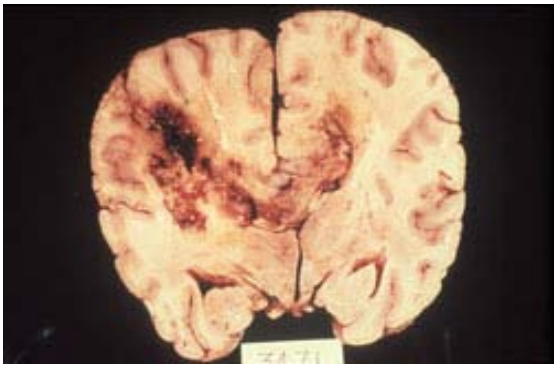

36. Brain illustrating a glioblastoma multiforme in the frontal lobe
Note that GBMs exhibit hemorrhagic necrosis and that they have a propensity for crossing the corpus callosum into the other hemisphere. A GBM is the most common primary brain tumor in adults. **(CNS036)**

37. Meningioma (second most common primary tumor of the CNS in adults, most common benign tumor in adults) attached to the undersurface of the dura, which has been reflected back from the surface of the brain. Note that the brain underlying the meningioma appears irritated and most likely resulted in seizure activity in the patient. **(CNS037)**

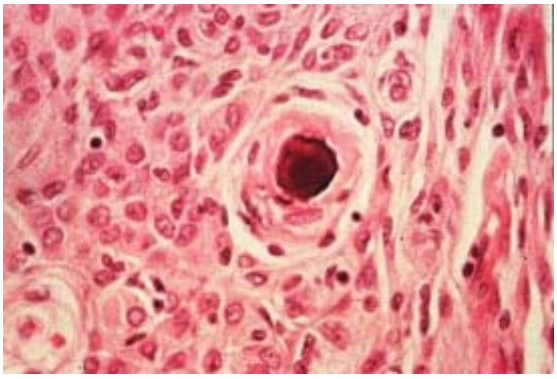

38. Section of a meningioma showing the last of the psammoma bodies. (CNS038)

39. Section through a benign acoustic neuroma (schwannoma, neurilemoma) showing the classic

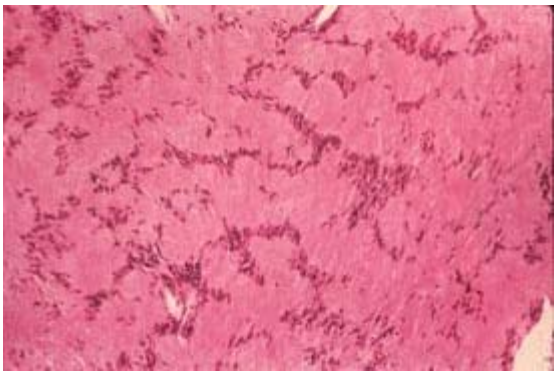

"zebra" pattern.
The dark areas represent Antoni A areas and the lighter areas in between are Antoni B areas. Patients present with nerve deafness and sensory changes on the face from compression of CN V in the cerebellopontine angle. Recall the relationship of these tumors with neurofibromas. Acoustic neuromas are the third most common tumor in the CNS and derive from Schwann cells. **(CNS039)**

40. Multiple metastatic foci in the brain in a patient who had a primary lung cancer. (CNS040)

Previous | **Next**

Return to Top | **Return to Image Index**

Pathology II Images

Central Nervous System

It is against copyright laws to make *electronic or printed* copies of these slides!!

41. Xanthelasma of the eyelid
It is secondary to cholesterol deposition in macrophages in the underlying subcutaneous tissue and may represent a type II hyperlipidemia. **(CNS041)**

42. Stye on the eyelid due to Staphylococcus aureus. (CNS042)

43. Bacterial conjunctivitis
Note the conjunctival irritation and pus. Streptococcus pneumoniae, Streptococcus pyogenes, H. influenzae, S. aureus are common offenders. Blurry vision is not a feature of conjunctivitis. **(CNS043)**

44. Special stain of the conjunctiva showing a dendritic ulcer consistent with Herpes simplex keratoconjunctivitis. (CNS044)

45. Patient with subconjunctival hemorrhages secondary to coughing
This should not be confused with a hyphema, which is blood in the anterior chamber of the eye. **(CNS045)**

46. Patient with bilateral arcus senilis
This is a degenerative change that is common in the elderly. If noted in a young person, a lipid profile should be ordered. **(CNS046)**

47. Papilledema in a patient with increased intracranial pressure
Note the loss of demarcation of the optic disk, the flame hemorrhages, and cotton wool exudates representing areas of retinal infarction. **(CNS047)**

48. Optic atrophy
Note the loss of physiologic cupping and the paleness of the optic disk. **(CNS048)**

49. Retinoblastoma
This is the most common primary eye cancer in children. In some cases, it has an AD inheritance pattern. The Rb suppressor gene is located on chromosome 13. **(CNS049)**

50. Inflamed eardrum in a patient with otitis media

Note the loss of the light reflex and red tympanic membrane. S. pneumoniae, H. influenzae, and B. catarrhalis are the most common causes in descending frequency. **(CNS050)**

Previous | **Next**

Return to Top | Return to Image Index

Pathology II Images

Infectious Disease
Bacteria

It is against copyright laws to make *electronic or printed* copies of these slides!!

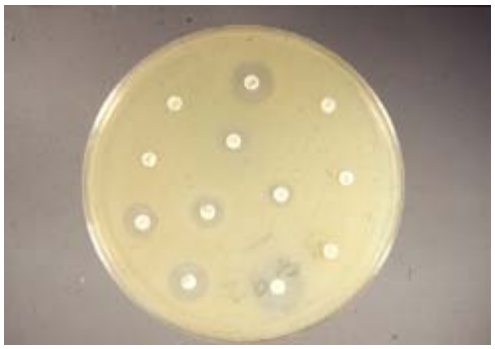

1. Mueller-Hinton plate for antibiotic susceptibility:
Discs with lucency around them indicate susceptibility of the organism for the antibiotic **(Id244)**

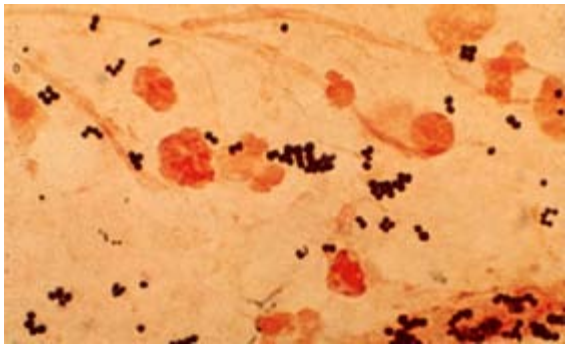

2. Gram positive cocci in clusters (*Staphylococcus aureus*) in a patient with an abscess on the skin:
Note the relation of the bacteria with neutrophils. Coagulase keeps the organisms clumped together. **(Id239)**

3. Abscess of the wrist- *Staphylococcus aureus*:
Note the erythema surrounding the abscess. It drains via a sinus tract. **(Id396)**

4. Monocytes with phagocytosed cocci of *Staphylococcus aureus*:
The patient had septicemia due to the organism. An indwelling venous catheter is the MCC. **(Id404)**

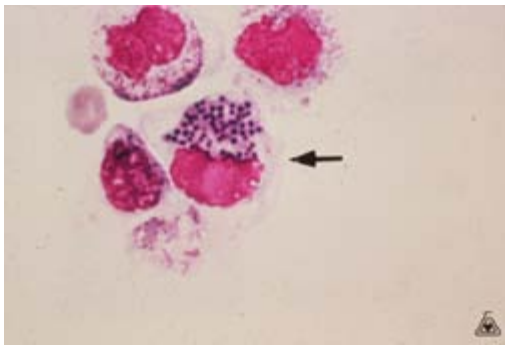

5. Group A Streptococcus pharyngitis (*Streptococcus pyogenes*):
Note the pus on the tonsils. Most exudative tonsillitis is due to a viral infection. Rheumatic fever may be a complication (immunologic disease). **(Id237)**

6. Patient with desquamating rash of scarlet fever due to group A Streptococcus:
Due to an erythrogenic strain of group A streptococcus. Post-streptococcal glomerulonephritis may be a complication (immunologic). **(Id319)**

7. White coated tongue in a patient with scarlet fever due to *Streptococcus pyogenes*:
Initial appearance of the tongue before desquamation **(Id400)**

8. Strawberry tongue in a patient with scarlet fever due to *Streptococcus pyogenes*:
Appearance of the tongue after

desquamation **(Id399)**

9. Patient with impetigo due to *Streptococcus pyogenes*:
Note the honey colored crusty lesions. Bullous lesions imply a superinfection with Staphylococcus aureus. **(Id325)**

10. Child with impetigo due to *Streptococcus pyogenes*:
Note the honey colored crusty lesions. **(Id335)**

Previous | Next

Return to Top | Return to Image Index

Pathology II Images

Infectious Disease
Bacteria

It is against copyright laws to make *electronic or printed* copies of these slides!!

11. Patient with erysipelas due to *Streptococcus pyogenes*: Cellulitis related to hyaluronidase **(Id333)**

12. Patient with erysipelas due to *Streptococcus pyogenes* cellulitis: Cellulitis related to hyaluronidase **(Id401)**

13. Ludwig's angina due to *Streptococcus pyogenes*: Cellulitis extending into the fascial planes **(Id413)**

14. Schematic of gram positive diplococci (*Streptococcus pneumoniae*): Note that the diplococci are lancet shaped **(Id235)**

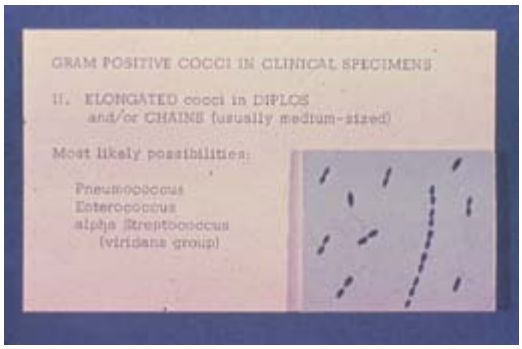

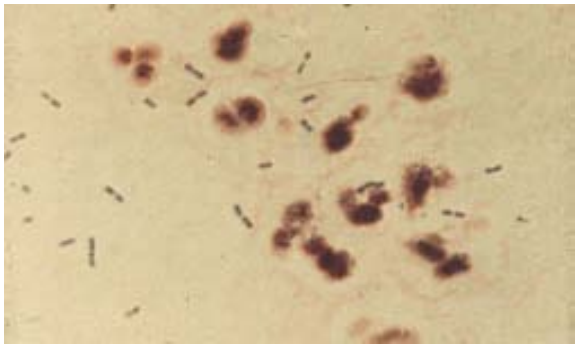

15. Gram stain of sputum with gram positive diplococci-*Streptococcus pneumoniae*:
Note relationship with neutrophils. MCC of typical, community acquired pneumonia. **(Id245)**

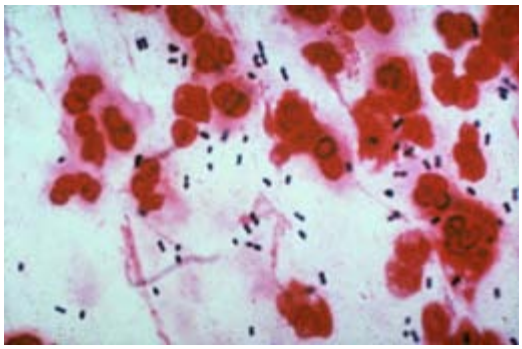

16. Gram stain of sputum with gram positive diplococci-*Streptococcus pneumoniae* (Pneumococcus):
Note relationship with neutrophils. MCC of typical, community acquired pneumonia. **(Id336)**

17. Dental caries due to *Streptococcus mutans*:
Acts on sucrose to produce dextran, which enhances plaque formation **(Id412)**

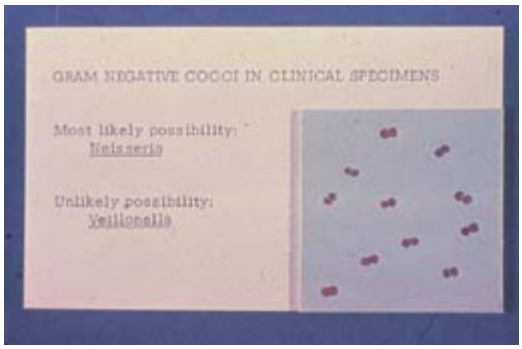

18. Schematic of gram negative diplococcus (e.g., *Neisseria* species):
Note that the diplococci are coffee bean-shaped **(Id242)**

19. Child with *Neisseria meningitidis* sepsis:
Note the petechial lesions, which are characteristic. Septicemia and

meningitis are MC in the 1 mth to 18 yr old bracket. Waterhouse Friderichsen's syndrome is a potential complication. **(Id001)**

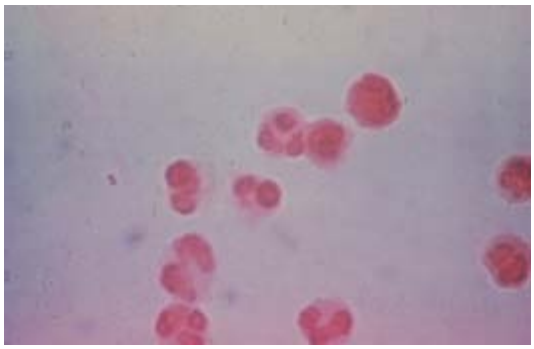

20. Gram negative diplococcus in spinal fluid- *Neisseria meningitidis*:
Note the single neutrophil with a phagocytosed meningococcus **(Id248)**

Previous | Next

Return to Top | Return to Image Index

Pathology II Images

Infectious Disease
Bacteria

It is against copyright laws to make *electronic or printed* copies of these slides!!

21. Purpuric lesions in disseminated meningococcemia due to *Neisseria meningitidis*:
Petechia and purpuric lesions are common findings in sepsis **(Id402)**

22. Creamy penile and cervical discharge of *Neisseria gonorrhoeae*:
Symptoms appear within the first week of sexual exposure **(Id376)**

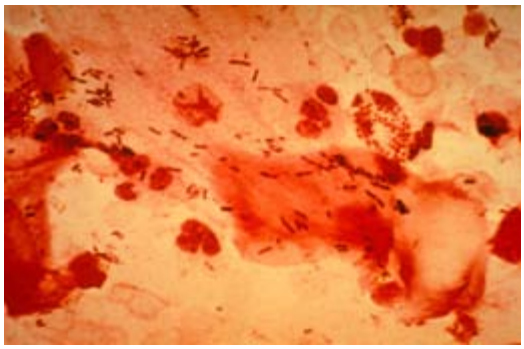

23. Neutrophil (1o'clock) with gram negative diplococci- *Neisseria gonorrhoeae*:
Note the neutrophil with phagocytosed organisms **(Id360)**

24. Bilateral tuboovarian abscesses due to *Neisseria gonorrhoeae*:
Note the exudate in the lumen of the tubes and extension to both ovaries. Ectopic pregnancies are a common sequelae. **(Id359)**

25. Fibrous bands connecting parietal peritoneum with surface of the liver (Fitz-Hughes-Curtis syndrome)- perihepatitis *Neisseria gonorrhoeae*:
In PID, pus gets under the parietal peritoneum and along the surface of the liver. Healing occurs with scar tissue formation. PID due to *Chlamydia trachomatis* does the same thing. **(Id375)**

26. Pustules on the wrist, palm, and foot in disseminated gonococcemia due to *Neisseria gonorrhoeae*:
Dissemination mainly occurs in women who are asymptomatic carriers. Complement deficiencies involving C5-C9 predispose to dissemination. Septic arthritis involving the knee, tenosynovitis involving the hands and feet, and pustules in the hands and feet are common findings. **(Id374)**

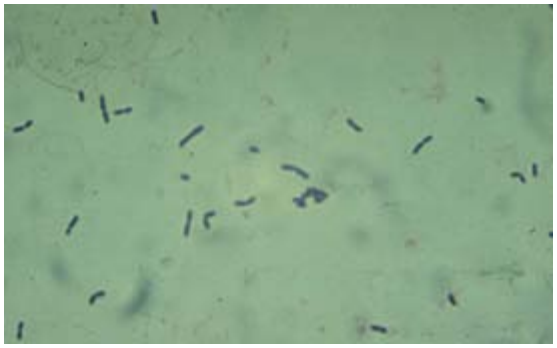

27. Gram positive rods- *Listeria monocytogenes*:
This organism is the third MCC of neonatal sepsis/meningitis and commonly produces meningitis in immuno-compromised patients. Pregnant women should avoid eating soft cheeses. The organism exhibits tumbling motility. **(Id252)**

28. Fish handler with erysipeloid due to *Erysipelothrix rhusiopathiae* (gram positive rod):
Note the purplish colored rash. Veterinarians, butchers, and fish handler's are most likely to develop this disease. **(Id234)**

29. Gray pseudomembrane in posterior pharynx due to

***Corynebacterium diphtheriae*:**
People who are not immunized are at risk for developing infection. Note the shaggy pseudomembrane that is probably interfering with swallowing. **(Id233)**

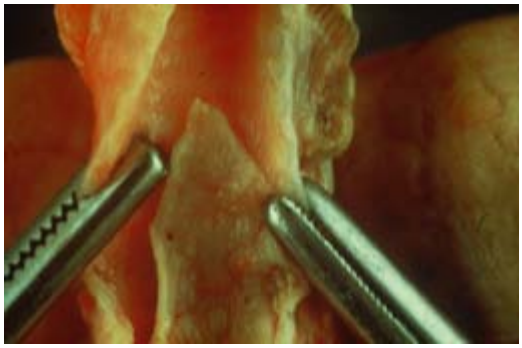

30. Pseudomembrane in trachea due to *Corynebacterium diphtheriae*:
The toxin damages the mucosa and submucosa. The organism is not invasive. **(Id394)**

Previous | **Next**

Return to Top | **Return to Image Index**

Pathology II Images

Infectious Disease
Bacteria

It is against copyright laws to make *electronic or printed* copies of these slides!!

31. Bull's neck lymphadenopathy associated with *Corynebacterium diphtheriae*:
Lymphadenopathy from drainage of the infected area is profound **(Id232)**

32. Patient with acne vulgaris-*Propionibacterium acnes*:
This gram positive anaerobe produces lipases that convert sebum into fatty acids, which irritate the hair follicle leading to acne **(Id334)**

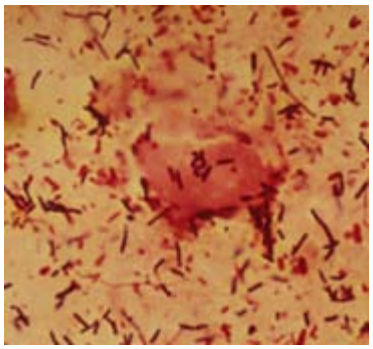

33. Gram positive rods in stool-*Clostridium difficile*:
This organism is part of the normal flora of stool. However, when antibiotics are administered (e.g., ampicillin, clindamycin) bacteria that normally keep *C. difficile* in check are destroyed allowing for rapid proliferation and the potential for pseudomembranous colitis. **(Id254)**

34. Pseudomembranous colitis due to *Clostridium difficile*:
Similar to the *C. diphtheriae*, pseudomembranous colitis is a non-invasive, toxin-induced disease with formation of a pseudomembrane. A toxin assay of stool is the gold standard for Dx. Metronidazole is the Rx of choice. **(Id381)**

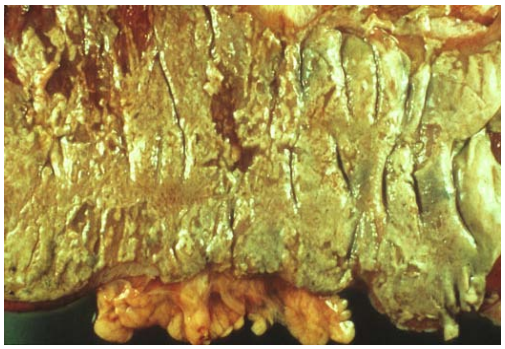

35. Myonecrosis and subcutaneous gas due to *Clostridium perfringens* (gas gangrene):
Note the gas in the subcutaneous tissue. This organism is also associated with septic endometritis from illegal abortions and food poisoning. **(Id228)**

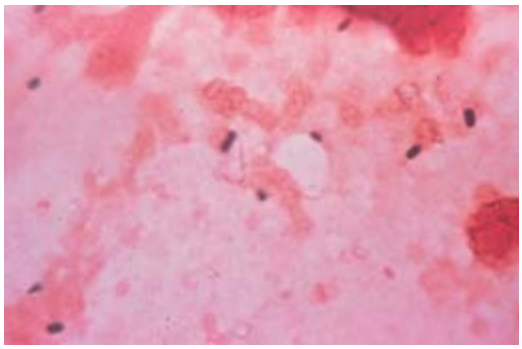

36. Gram positive rods from a wound- *Clostridium perfringens*:
Note the scant number of organisms in the wound **(Id249)**

37. Mydriasis in *Clostridium botulinum* infection:
Note the dilated pupil. The toxin irreversibly blocks the release of acetylcholine from cholinergic receptors leading to flaccid paralysis of muscle. Diplopia from eye muscle paralysis is the first sign. The toxin is used clinically to Rx muscle spasm disorders. **(Id229)**

38. Newborn with *Clostridium tetani*:
Note the arching of the back due to spasm of the erector spinae muscles. Tetanospasmin binds to ganglioside receptors of spinal afferent fibers and blocks release of the inhibitory neurotransmitter glycine in the spinal cord leading to sustained muscle contractions. The jaw is the first site of involvement followed by the facial muscles. Infections of the umbilicus in newborns and improper debridement of dirty wounds predispose to the infection. **(Id002)**

39. Gram positive rods with terminal spore- *Clostridium tetani*:

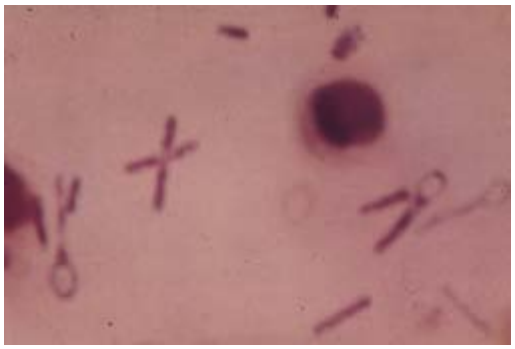

Note the terminal spore. The space is clear, since the spore is located inside the cell wall of the organism. **(Id253)**

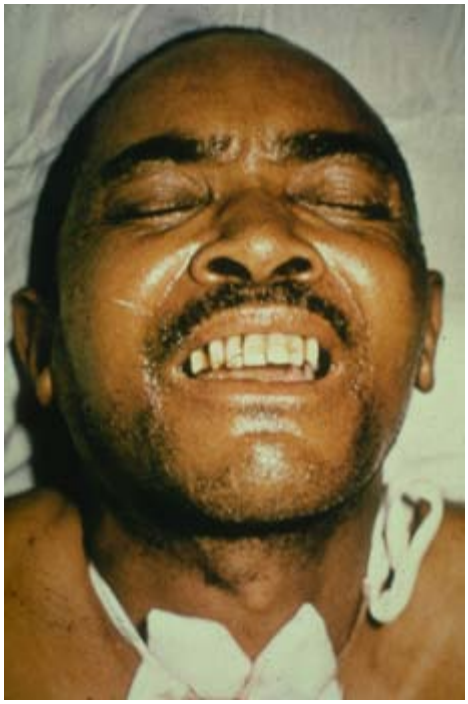

40. Patient with risus sardonicus due to *Clostridium tetani*:
Classic appearance of facial muscle contraction **(Id411)**

Previous | Next

Return to Top | Return to Image Index

Pathology II Images

Syllabus | Lecture Schedule | Images - Pathology I | Images - Pathology II

Infectious Disease
Bacteria

1 | 2 | 3 | 4 | 5 | 6 | 7 | 8 | 9

It is against copyright laws to make *electronic or printed* copies of these slides!!

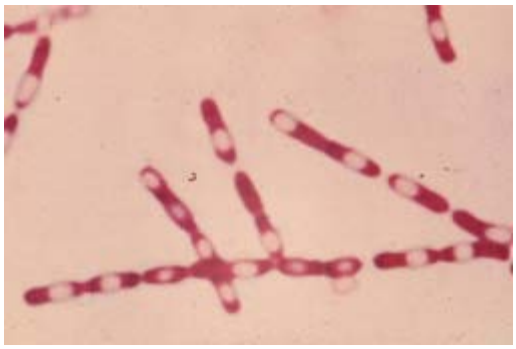

41. Spores of *Bacillus anthracis*:
This special stain demonstrates the spore within the bacillus **(Id236)**

42. Malignant pustule of *Bacillus anthracis*:
This is the characteristic appearance of cutaneous anthrax. The black scab is called an eschar. Inhalation anthrax is invariably fatal. **(Id238)**

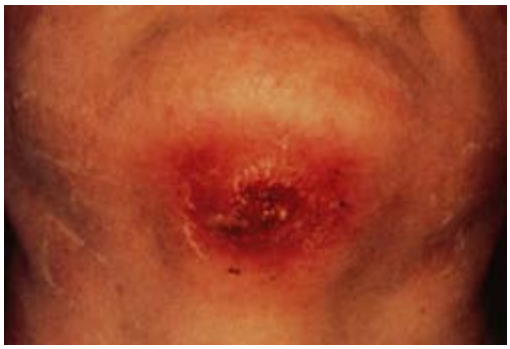

43. Patient with draining sinus under the chin due to *Actinomyces israeli*:
Note the yellow sulfur granule in the draining sinus. The patient had an abscessed tooth removed a few weeks before the sinus developed secondary to osteomyelitis in the mandible. In addition to producing sinus tracts in the jaw, thorax, and abdomen, it also is associated with endometritis related to intrauterine devices. *Actinomyces* is an anaerobic, gram positive filamentous bacteria. **(Id417)**

44. H and E stain of sulfur granule of *Actinomyces israeli*:
The sulfur granule contains the organisms. **(Id004)**

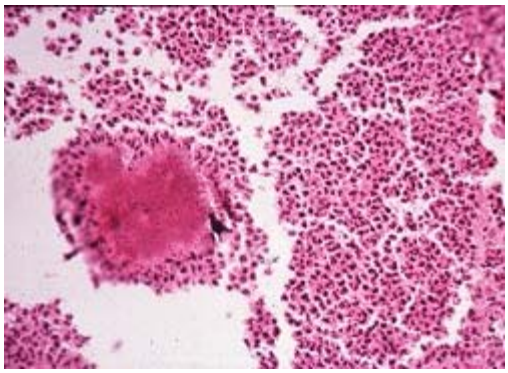

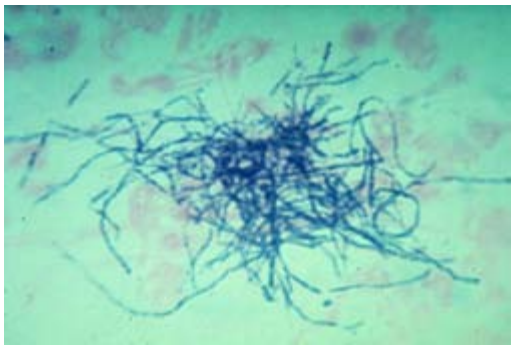

45. Gram positive filamentous bacteria in sulfur granule- *Actinomyces israeli*:
Note the branching filaments **(Id414)**

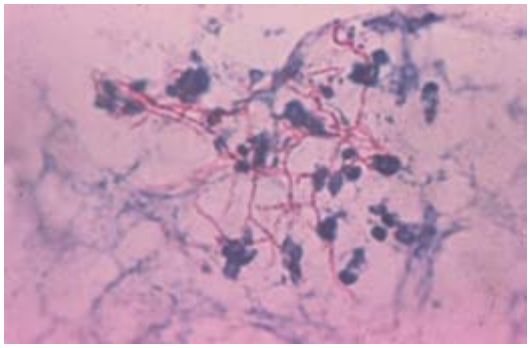

46. Acid fast stain of *Nocardia asteroides* (filamentous gram positive bacteria):
The cell wall of *Nocardia* contains mycolic acid, hence the acid-fastness of the bacteria. Unlike *Actinomyces*, it is aerobic. **(Id226)**

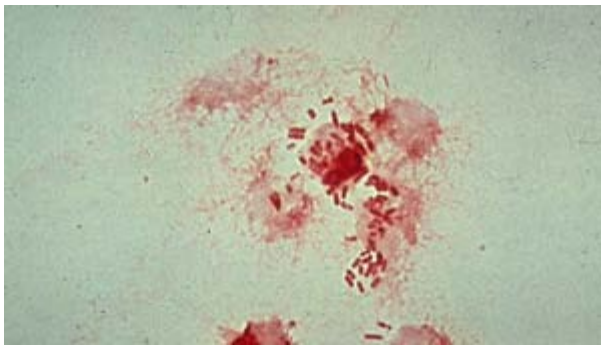

47. Gram negative rods in urine- *E. coli*:
Note the fat gram negative rods. It is the MCC of upper and lower urinary tract infections, sepsis and endotoxic shock in a hospitalized patient with an indwelling urinary catheter, and spontaneous peritonitis in patients with cirrhosis and ascites. **(Id246)**

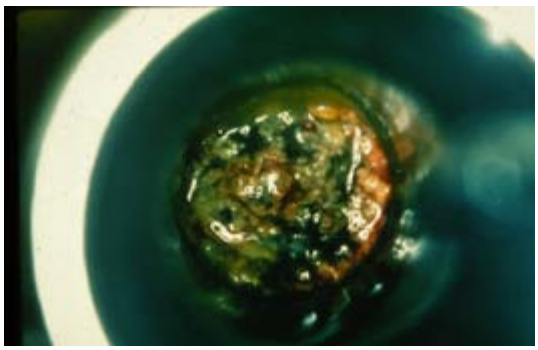

48. Necrotic pseudomembrane in the rectosigmoid in a patient with *Shigella sonnei* enteritis:
The pseudomembrane is easily mistaken for *C. difficile* and also the necrotic changes associated with ulcerative colitis. The enteritis is characterized by bloody diarrhea (definition of dysentery). **(Id038)**

49. Rose spots on abdomen in a patient with typhoid fever due to *Salmonella typhi*:
Salmonella is a facultative intracellular

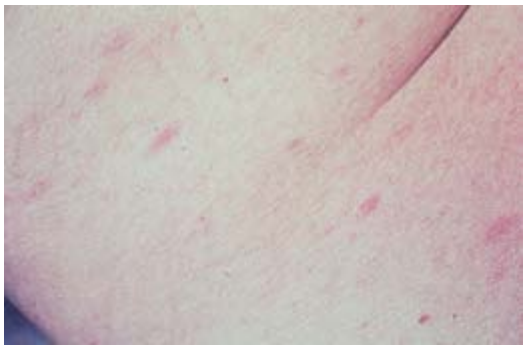

parasite, hence it hosts a mononuclear rather than neutrophil response in tissue. Like M. tuberculosis and bovis, it invades Peyer's patches in the terminal ileum. The first week is the bacteremic phase and the second is associated with a vasculitis producing the rose spots on the upper anterior trunk plus the classic triad of hepatosplenomegaly, bradycardia, and neutropenia. Humans are the reservoir for the bacteria. **(Id405)**

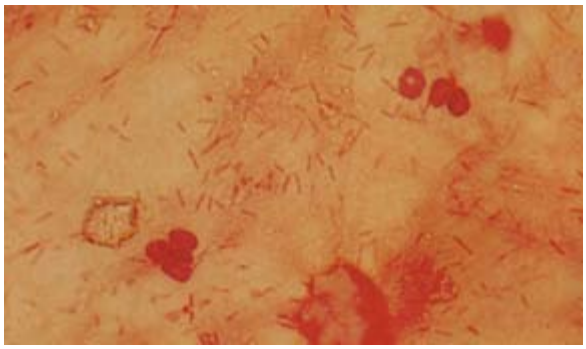

50. Fat gram negative rods in sputum of a patient with lobar pneumonia- *Klebsiella pneumoniae*: Pneumonia in alcoholics is commonly due to Klebsiella. The thick capsule often shows up on gram stain (see clearing around the bacteria) and is also apparent in sputum, which is often mucoid and bloody. Abscess formation commonly occurs. **(Id247)**

Previous | Next

Return to Top | Return to Image Index

Pathology II Images

Infectious Disease
Bacteria

It is against copyright laws to make *electronic or printed* copies of these slides!!

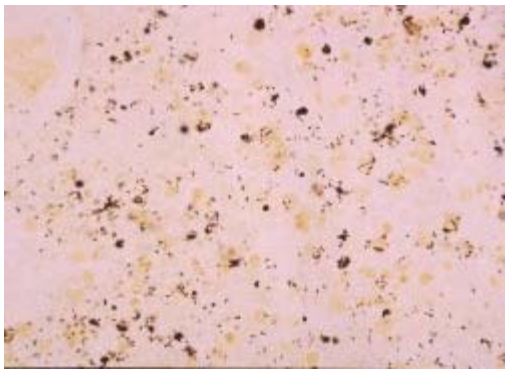

51. Silver stain of *Legionella pneumophila*:
Legionella organisms stain weakly gram negative, however, they are easily visualized with the Dieterle silver stain. They are facultative intracellular bacteria and are water loving. They produce an atypical type of pneumonia with high fevers. **(Id006)**

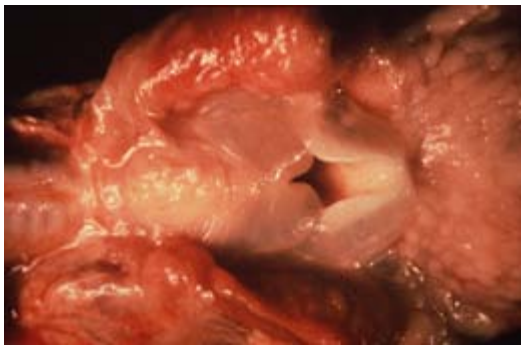

52. Edema of epiglottis due to *Hemophilus influenzae*:
Note the swelling of the epiglottis in this patient. The swelling on a lateral x-ray resembles a thumbprint. Inspiratory stridor is present. **(Id416)**

53. Painful penile ulcer of *Hemophilus ducreyi* (chancroid):
Unlike primary syphilis, the ulcer is painful rather than painless **(Id352)**

54. Gram stain showing gram negative rods with a "school of fish" orientation- *Hemophilus ducreyi* (chancroid):
Note how the bacteria orient themselves in the same direction **(Id373)**

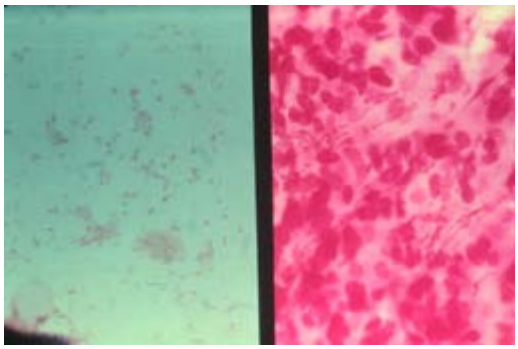

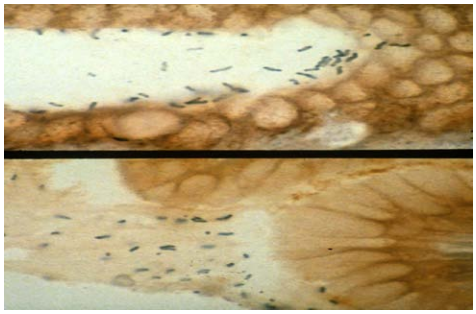

55. Silver stain of antrum of stomach with *Helicobacter pylori* in mucous layer:
These bacteria are urease producers, which convert urea into ammonia, which destroys the mucous barrier, hence predisposing to gastric and duodenal ulcers. Gastric adenocarcinoma and low-grade malignant lymphoma are also associated with the organism. **(Id464)**

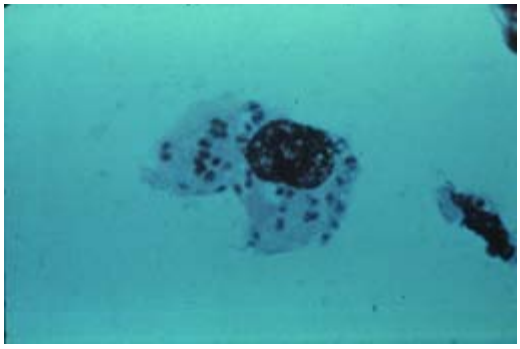

56. Macrophage with Donovan bodies in a patient with granuloma inguinale due to *Calymmato-bacterium granulomatis*:
The organisms resemble the yeast forms of Histoplasma and the leishmanial forms of leishmaniasis **(Id371)**

57. Creeping ulcers of granuloma inguinale due to *Calymmato-bacterium granulomatis*:
Unlike other STDs, granuloma inguinale is not associated with lymphadenopathy **(Id372)**

58. Cervical Pap smear with "clue cell" in patient with bacterial vaginosis due to *Gardnerella vaginalis*:
Note the granular appearance of the superficial squamous cell due to bacteria

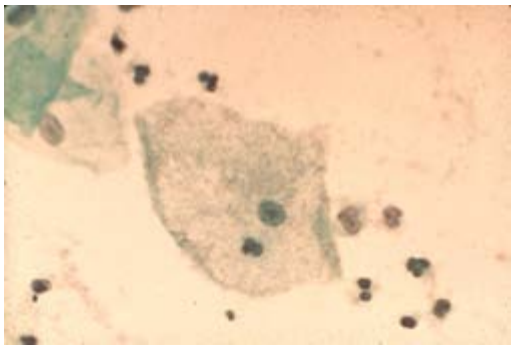

sticking to the surface of the cell. Bacterial vaginosis is not an infection but an alteration in the pH of the vaginal fluids to > 5.5. No inflammation is present except a malodorous vaginal discharge. Rx is metronidazole. **(Id356)**

59. Inflamed scratch site of a cat with subsequent development of cat scratch fever due to *Bartonella henselae*: Similar to *Legionella*, *Bartonella* organisms do not stain well with gram stain. Silver stains identify the organism. Bartonella henselae is also the cause of bacillary angiomatosis, a vascular inflammation only seen in AIDS. It simulates Kaposi's sarcoma. **(Id224)**

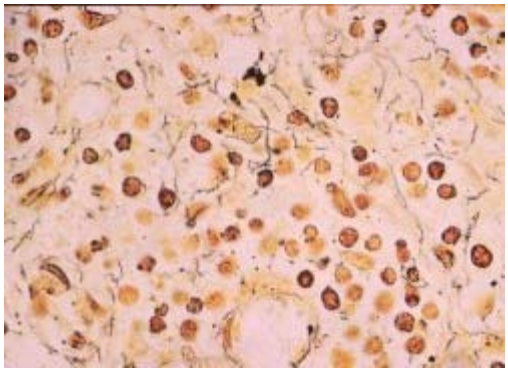

60. Silver stain of *Treponema pallidum*: Similar to Legionella and Bartonella henselae, treponemes visualize best with a silver stain. Note the corkscrew appearance of the organisms. These can penetrate intact skin. **(Id007)**

Previous | Next

Return to Top | Return to Image Index

Pathology II Images

Infectious Disease
Bacteria

It is against copyright laws to make *electronic or printed* copies of these slides!!

61. Dark field showing *Treponema pallidum*:
A dark field analysis of fluid from a lesion of primary or secondary syphilis is considered the gold standard for diagnosing syphilis **(Id370)**

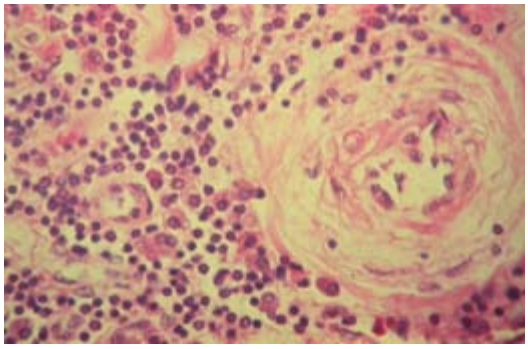

62. Endarteritis obliterans and plasma cell infiltrate in vasculitis due to *Treponema pallidum*:
The pathology of syphilis is related to a vasculitis involving small vessels. The vessel is to your right. The lumen is reduced owing to the inflammatory infiltrate around the vessel. Plasma cells are easily identified by looking for a peripherally oriented nucleus. Plasma cells are a key feature for the vasculitis of syphilis. **(Id397)**

63. Painless penile chancre in primary syphilis due to *Treponema pallidum*:
The ulcer is due to the endarteritis obliterans beneath the epidermis, which decreases blood flow causing ischemic necrosis of the overlying skin. Since nerves are around vessels, they are also destroyed, hence the painless features of the ulcer. **(Id355)**

64. Syphilitic chancre due to *Treponema pallidum* and discharge due to *Neisseria gonorrhoeae*:
This patient has two STDs, primary

syphilis and gonorrhea **(Id407)**

65. Erythematous palmar rash in secondary syphilis due to *Treponema pallidum*:
The rash of secondary syphilis may be generalized **(Id354)**

66. Condyloma latum of the labia in secondary syphilis due to *Treponema pallidum*:
Note the flat lesions around the labia. These lesions are often confused with condyloma acuminata due to HPV. **(Id353)**

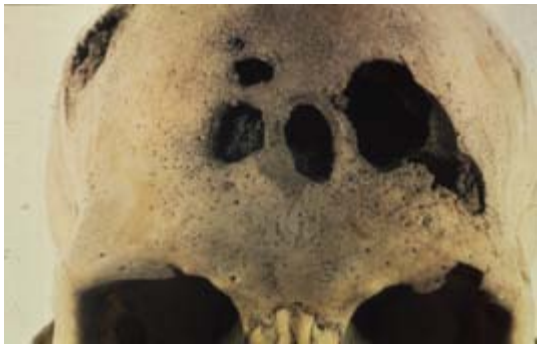

67. Gummas in skull in a patient with tertiary syphilis due to *Treponema pallidum*:
Gummas are very destructive, witness the fact that the bone in the skull has been destroyed leaving cystic spaces **(Id395)**

68. Pegged teeth and destruction of palate in congenital syphilis due to *Treponema pallidum*:
Congenital syphilis is vertically transmitted after 5 months **(Id357)**

69. Pegged teeth of congenital syphilis due to *Treponema pallidum*:
Note the notching of the incisors

(Hutchinson's teeth) **(Id240)**

70. Perioral scarring, saddle nose deformity of congenital syphilis due to *Treponema pallidum*:
Note collapse of the nasal septum producing a saddle nose deformity and the perioral scarring that raises the lip up **(Id358)**

Previous | Next
Return to Top | Return to Image Index

Pathology II Images

Infectious Disease
Bacteria

It is against copyright laws to make *electronic or printed* copies of these slides!!

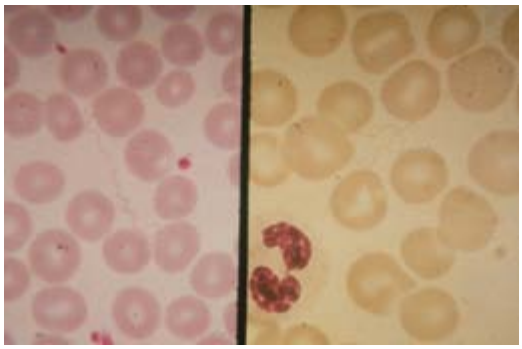

71. *Borrelia recurrentis* spirochetes in peripheral blood:
Borrelia recurrentis is the cause of relapsing fever. It is relapsing owing to the emergence of new antigen types, similar to what is seen in African sleeping sickness. Ticks and lice may transmit the disease. Note the loosely wound spirochetes in the blood. **(Id305)**

72. *Ioxides dammini* (tick) and erythema chronicum migrans in a patient with Lyme's disease due to *Borrelia burgdorferi*:
Note the concentric nature of the rash, which is pathognomonic of early Lyme's disease. The white tailed deer is the reservoir for the spirochete. *Ioxides* also carries *Babesia microti*, with is an intraerythrocytic parasite that produces a hemolytic anemia. **(Id366)**

73. Silver stain demonstrating the shepherd's crook appearing spirochete of *Leptospira interrogans*:
Dogs are the most important reservoir for the spirochete and infected urine is the primary source of the infection. Hepatitis and renal disease are common complications. **(Id250)**

74. Conjunctivitis associated with *Leptospira interrogans*:
Note the red conjunctiva in the eye on your right. Conjunctivitis with photophobia occurs during the septicemic phase of the disease. **(Id223)**

75. Gross of lung with abscess due to aspiration or oropharyngeal material-mixed aerobic and anaerobic bacteria:
The abscess cavity is in the posterior segment of the right upper lobe, therefore, the patient must have aspirated infected oropharyngeal material while lying on their right side. Oropharyngeal material contains aerobic and anaerobic organisms (e.g., Fusobacterium). **(Id340)**

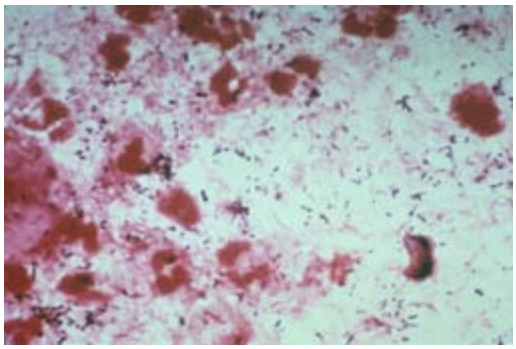

76. Gram stain with mixed aerobic and anaerobic bacteria:
Note the mixture of gram positive and negative organisms some of which are cocci and others rods **(Id415)**

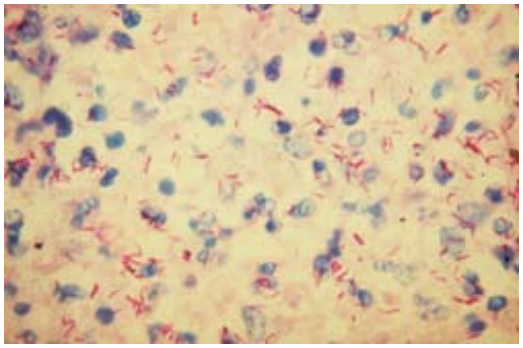

77. Granuloma with acid fast bacteria-*Mycobacterium tuberculosis*:
The organism is a strict aerobe and is an obligate intracellular organism. It is killed by activated macrophages (type IV hypersensitivity). Mycolic acid is responsible for its acid-fastness. **(Id306)**

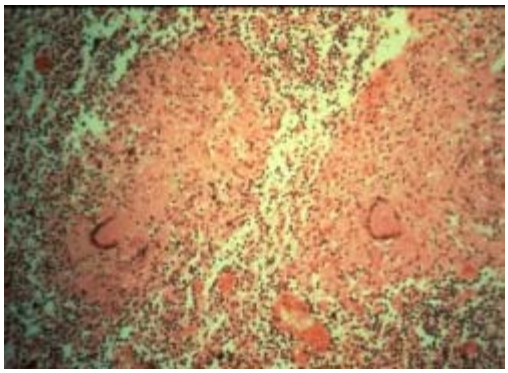

78. Granulomas in the lung due to *Mycobacterium tuberculosis*:
Note the well circumscribed, pink staining granulomas with multinucleated giant cells. Most of the pink staining cells are activated macrophages called epithelioid cells. Central areas of caseation are not present. **(Id008)**

79. Cavitary lesion with caseous necrosis in the lung apex-*Mycobacterium tuberculosis*:
Note the cheesy material in the cavitary

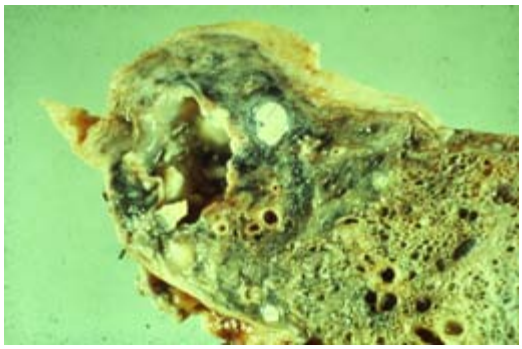

lesion representing caseous necrosis. Reactivation TB occurs in the apex of the lungs owing to the high O_2 concentration in the apex. **(Id348)**

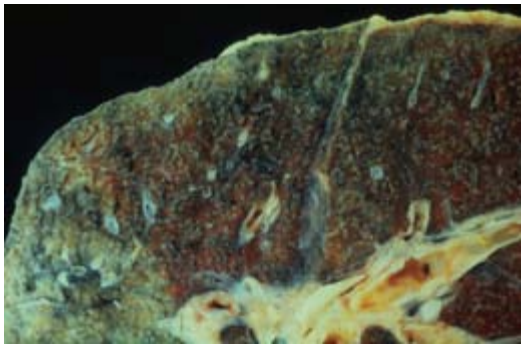

80. Gross of lung with miliary tuberculosis due to *Mycobacterium tuberculosis*:
Miliary TB may occur in primary or reactivation TB. Note the millet seed sized white granulomas in the parenchyma. **(Id220)**

Previous | **Next**

Return to Top | **Return to Image Index**

Pathology II Images

Infectious Disease
Bacteria

It is against copyright laws to make *electronic or printed* copies of these slides!!

81. Vertebral fracture due to *Mycobacterium tuberculosis* (Pott's disease):
Extrapulmonary spread of TB to the vertebral column is called Pott's disease. Note the vertebral fracture from destruction of one of the vertebra. **(Id010)**

82. Stricture of the terminal ileum in a patient with intestinal tuberculosis due to *Mycobacterium tuberculosis*:
Intestinal TB in the United States is due to swallowing TB from a primary site in the lungs. TB enters the lymphoid tissue in Peyer's patches in the terminal ileum (similar to Salmonella typhi) and spreads through the lymphatics, which are circumferentially oriented in the intestine. Reaction to injury is fibrosis, which produces a stricture resulting in obstruction. *M. bovis* from unpasteurized milk is the MCC in third world countries. **(Id410)**

83. Leonine face of a patient with lepromatous leprosy due to *Mycobacterium leprae*:
Note the nodular lesions in the face that give the patient a leonine appearance. Lepromatous leprosy exhibits a lack of cellular immunity, hence a negative lepromin skin test, the presence of organisms in tissue, and the absence of granuloma formation, which requires an intact cellular immunity. **(Id219)**

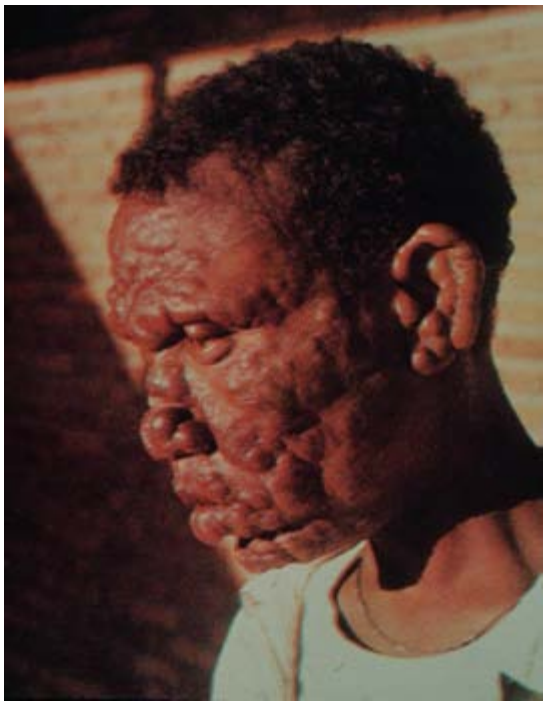

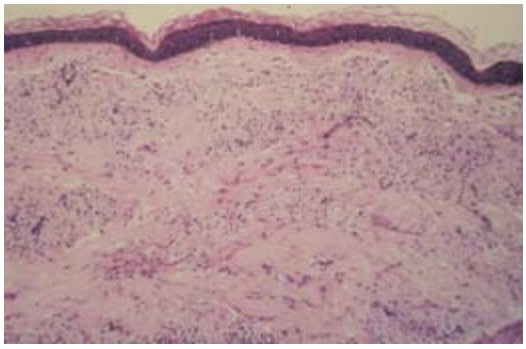

84. Skin biopsy in lepromatous leprosy demonstrating a Grenz zone and foamy macrophages with *Mycobacterium leprae*:
Due to the lack of cellular immunity in lepromatous leprosy, skin biopsies demonstrate organisms in macrophages. Note that the macrophages (pink staining cells) are located deep in the subcutaneous tissue. The zone directly beneath the basal cell layer is free of macrophages. This is called the Grenz zone. **(Id218)**

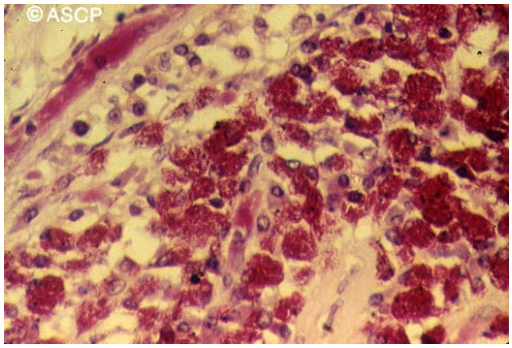

85. Microscopic section with acid-fast stain of foamy macrophages in lamina propria in a patient with Whipple's disease due to *Mycobacterium avium-intracellulare* (MAI):
Disseminated MAI, an atypical Mycobacterium, is the MC type of Mycobacterium in AIDS patients. Macrophages in the lamina propria of the small bowel are filled with the organisms. There is obstruction to lymphatic flow out of the small bowel leading to malabsorption. **(Id243)**

Previous | Next

Return to Top | Return to Image Index

Pathology II Images

Infectious Disease
Fungi

It is against copyright laws to make *electronic or printed* copies of these slides!!

1. Patient with tinea corporis due to *Trichophyton rubrum*:
Note the circular lesions with the red borders and pale centers. KOH preparations should be taken from scrapings from the red border. **(Id332)**

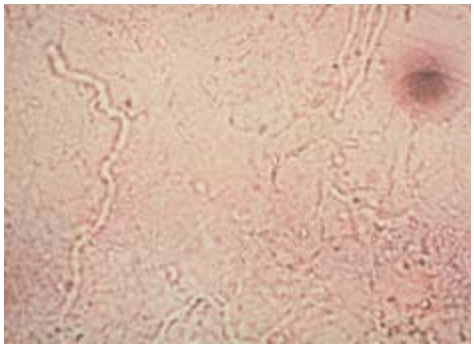

2. KOH preparation of yeast and hyphae of *Trichophyton rubrum* in a patient with tinea corporis:
Note the thread-like hyphae and occasional yeast forms **(Id331)**

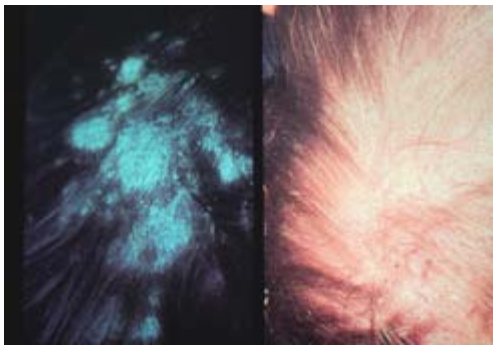

3. Tinea capitis with positive Wood's lamp due to *Microsporum canis*:
Note the green fluorescence on the left in an area of alopecia. The organism invades the outer sheath of the hair follicle, hence the positive Wood's lamp. *Trichophyton tonsurans* is the MCC of tinea capitis. It invades the inner hair shaft, hence a negative Wood's lamp. **(Id310)**

4. Tinea pedis due to *Trichophyton rubrum*:
Note the white area between the toes. **(Id309)**

5. Onychomycosis due to *Trichophyton rubrum*:
Note the nail discoloration. The finger on your left has a paronychial infection, most likely related to the fungus, however, it could also be due to *Staphylococcus aureus*. **(Id384)**

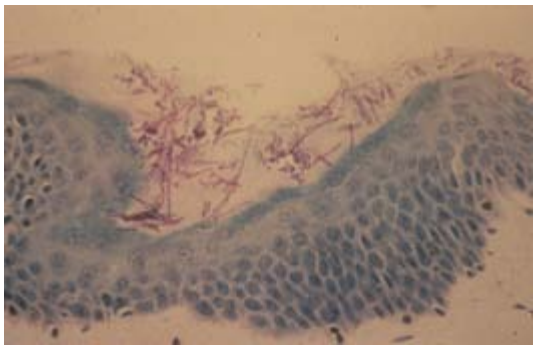

6. *Malassezia furfur* in stratum corneum in patient with tinea versicolor:
Note the spaghetti (hyphae) and meat ball (yeasts) in the stratum corneum layer of the skin. This is where all superficial dermatophyte infections are located. Topical imidazole compounds easily penetrate this layer. **(Id266)**

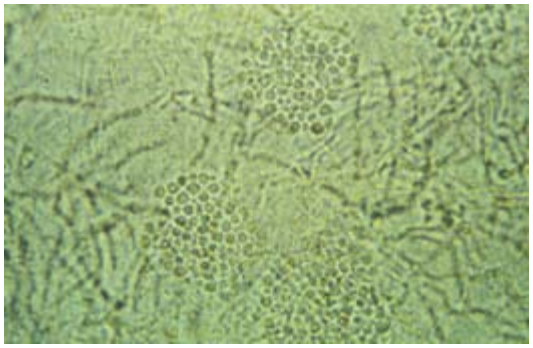

7. KOH preparation showing "spaghetti and meatballs" appearance of hyphae and yeasts of *Malassezia furfur*:
Malassezia infections include tinea versicolor and seborrheic dermatitis. It is disseminated in patient's with AIDS. **(Id330)**

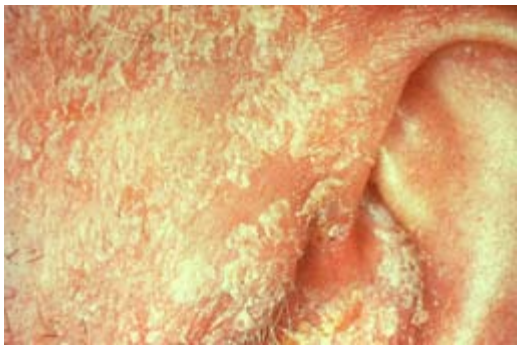

8. Patient with seborrheic dermatitis due to *Malassezia furfur*:
Note the flaky appearance of the skin. Seborrheic dermatitis on the scalp is called dandruff. **(Id307)**

9. Newborn with *Candida albicans* diaper rash:
Note the fiery red appearance of the skin **(Id329)**

10. Tongue of a patient with *Candida albicans* glossitis:
Note the white pseudomembrane covering the tongue. The patient was HIV positive. It is not AIDS-defining.
(Id350)

Previous | Next

Return to Top | Return to Image Index

Pathology II Images

Infectious Disease
Fungi

It is against copyright laws to make *electronic or printed* copies of these slides!!

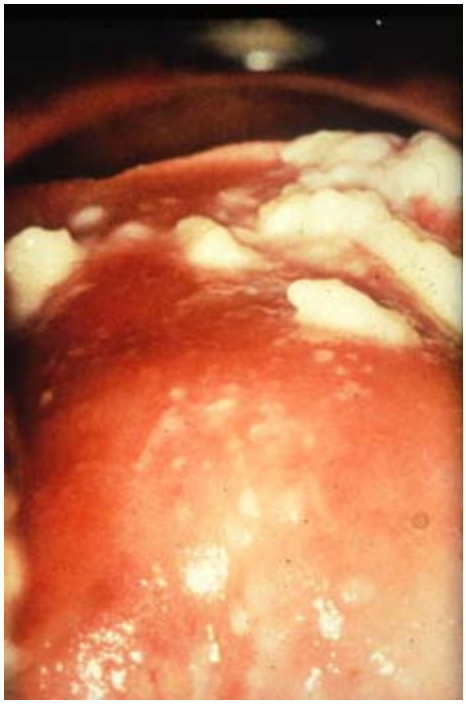

11. Cottage cheese discharge of vaginal infection with *Candida albicans*:
Note the white exudate and fiery red wall of the vagina **(Id367)**

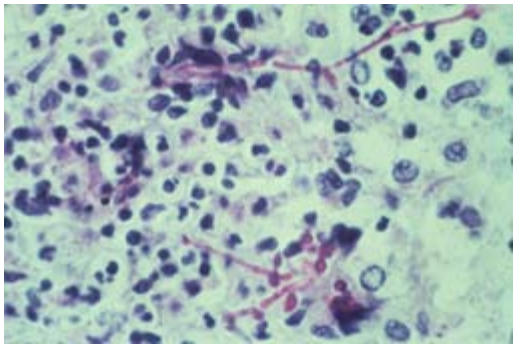

12. Pseudohyphae and yeasts of *Candida albicans* from a urine sample:
Presence of pseudohyphae indicates infection, while the presence of only yeasts is considered normal **(Id269)**

13. Cervical Pap smear with pseudohyphae and yeasts of *Candida albicans*:
Presence of pseudohyphae indicates infection, while the presence of only yeasts is considered normal **(Id308)**

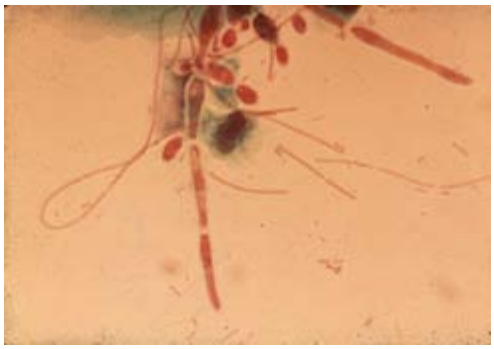

14. Patient with maduromycosis (mycetoma) of the foot due to *Pseudoallescheria boydii*:
This is a subcutaneous mycosis due to traumatic implantation. Note the numerous draining sinus tracts. Amputation is frequently necessary. **(Id386)**

15. Lymphocutaneous nodules of *Sporothrix schenckii*:
This is a subcutaneous mycosis due to traumatic implantation, in this case a thorn from a rose bush. Note the puncture mark below the second metacarpophalangeal joint. Lymphocutaneous nodules are located on the dorsum of the arm. The patient also has rheumatoid arthritis and osteoarthritis. **(Id324)**

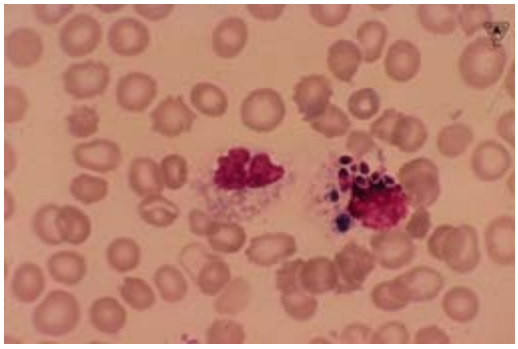

16. Gram positive yeasts in a monocyte in peripheral blood- *Candida albicans* sepsis:
The patient had a catheter in the subclavian vein. The fungus commonly produces metastatic abscesses and is a vessel invader that produces infarctions. **(Id265)**

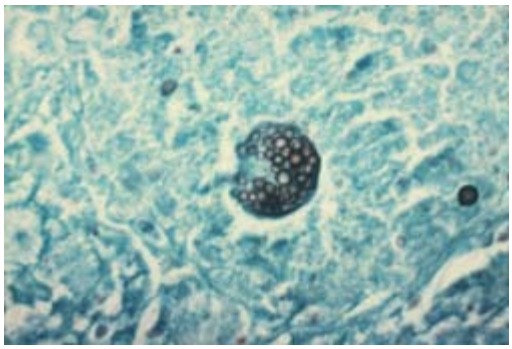

17. Silver stain of spherule in lungs containing endospores- *Coccidioides immitis*:
This fungus is common in the Southwest. Arthrospores are located in dust and are inhaled. **(Id264)**

18. Spherule in lung with endospores in a patient with *Coccidioides immitis* infection:
This fungus is common in the Southwest.

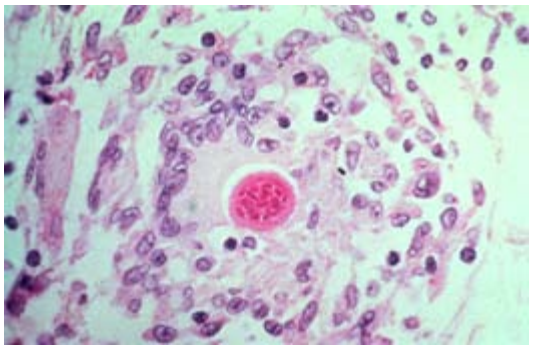

Arthrospores are located in dust and are inhaled. **(Id390)**

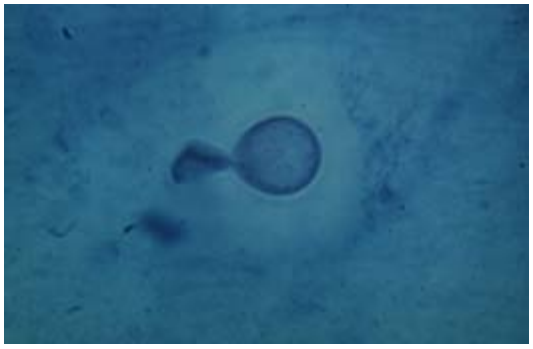

19. India ink preparation of *Cryptococcus neoformans*:
Clear area around the ink is the thick capsule. Note narrow-based bud. MC fungus in CNS in immunocompromised patient. **(Id268)**

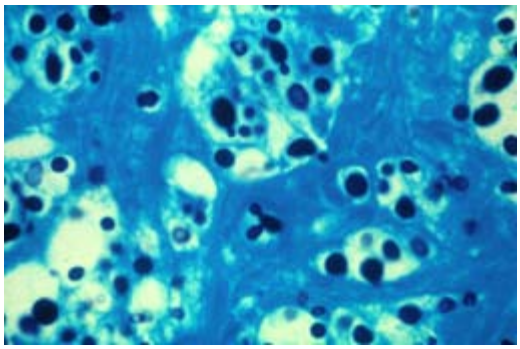

20. Silver stain showing narrow-based buds of *Cryptococcus neoformans* in the brain:
Some of the budding yeasts have a Mickey Mouse ears appearance. **(Id347)**

Previous | Next

Return to Top | Return to Image Index

Pathology II Images

Infectious Disease
Fungi

It is against copyright laws to make *electronic or printed* copies of these slides!!

21. Calcified granulomas in the lungs due to *Histoplasma capsulatum*:
MC systemic fungal infection. Associated with bats and Starlings. Located in Ohio-Tennessee valley and Mid-west. Simulates TB. Notorious for dystrophic calcification of granulomas. **(Id262)**

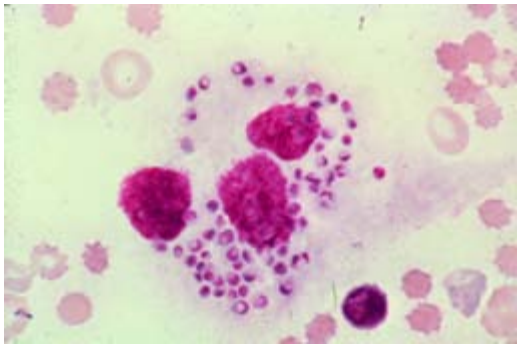

22. Monocytes in peripheral blood with phagocytosed yeast forms of *Histoplasma capsulatum*:
Only systemic fungus with yeast form located in monocytes or macrophages. Patient had disseminated disease. **(Id341)**

23. Alveolar macrophage with yeast forms of *Histoplasma capsulatum*:
Only systemic fungus with yeast form located in monocytes or macrophages. **(Id345)**

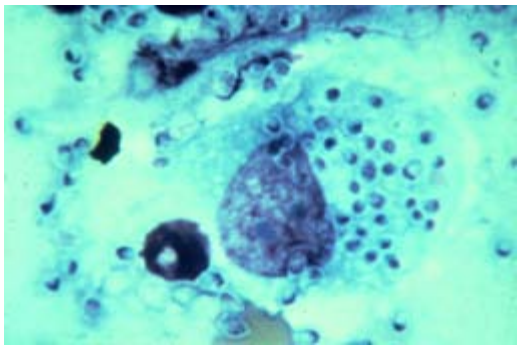

24. Facial lesion of *Blastomyces dermatitidis*:
Verrucoid appearance of the rash is confused with squamous cancer **(Id261)**

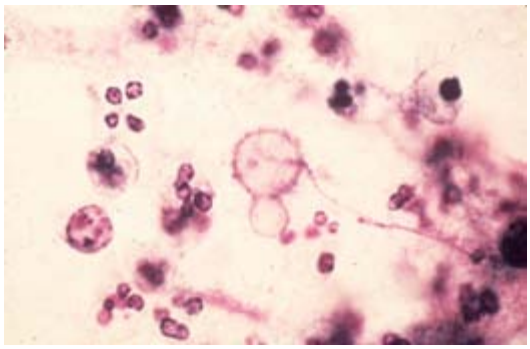

25. Yeast with broad-based bud in a section of lung- *Blastomyces dermatidis*:
Note the wide base of the bud **(Id342)**

26. Broad-based bud of *Blastomyces dermatidis*:
Note the wide base of the bud **(Id389)**

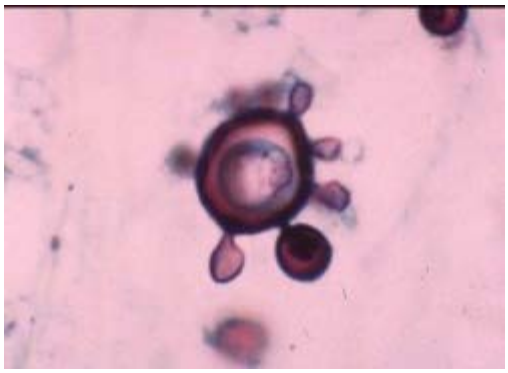

27. Silver stain showing "ship's wheel" configuration of yeast forms of *Paracoccidioides brasiliensis*:
Occurs in Central and South America **(Id012)**

28. Bilateral apical cavities with fungal invasion- *Aspergillus fumigatus*:
"Fungus balls" in old TB cavities. Note the hazy densities in the cavities. *Aspergillus* is

also associated with extrinsic asthma and hemorrhagic infarctions of the lungs (vessel invader). **(Id346)**

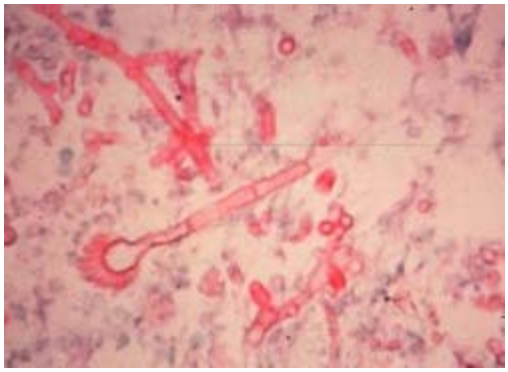

29. Corona and septate hyphae of *Aspergillus fumigatus*:
Fruiting body of *Aspergillus* looks like a crown **(Id014)**

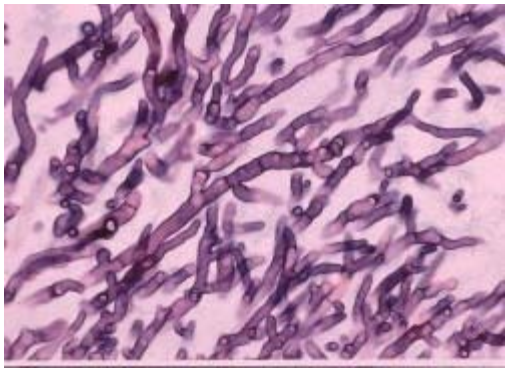

30. Silver stain showing arrow-angled, septate hyphae of *Aspergillus fumigatus* (Id015)

Previous | Next

Return to Top | Return to Image Index

Pathology II Images

Infectious Disease
Fungi

It is against copyright laws to make *electronic or printed* copies of these slides!!

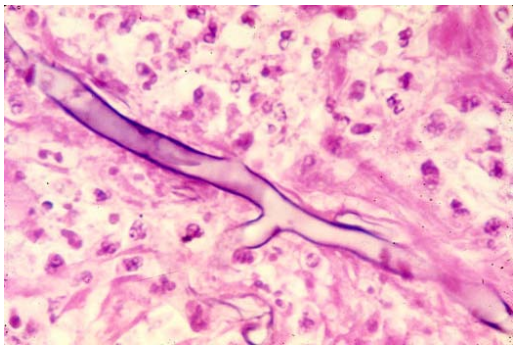

31. Frontal lobe of brain showing wide-angled, non-septate hyphae of *Mucor* species in a patient with diabetic ketoacidosis:
Rhinocerebral mucormycosis is unique to diabetic ketoacidosis. The fungus is a vessel invader. **(Id337)**

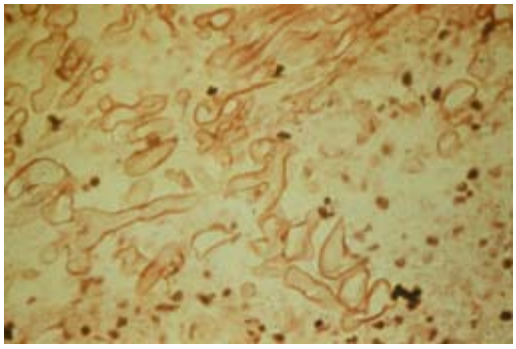

32. Wide-angled, non-septate hyphae of *Mucor* species (Id387)

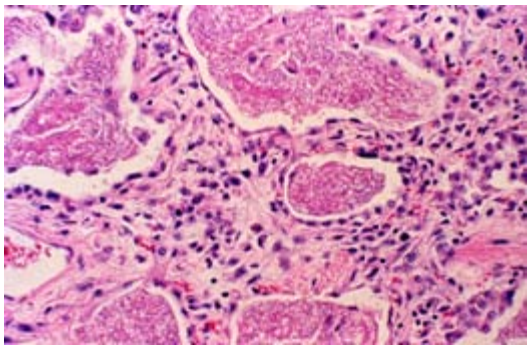

33. Histologic section of lung showing foamy alveolar infiltrate of *Pneumocystis carinii* pneumonia:
MC AIDS-defining opportunistic infection. Occurs with CD_4 T helper cell count is under 200 cells/ÂµL. Rx with trimethoprim/sulfamethoxazole. **(Id039)**

34. Silver stain of *Pneumocystis carinii*:
Note the crushed ping pong ball appearance **(Id257)**

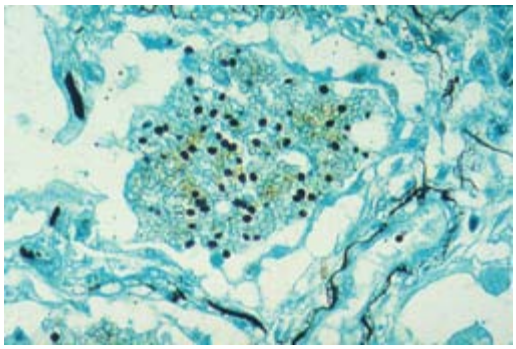

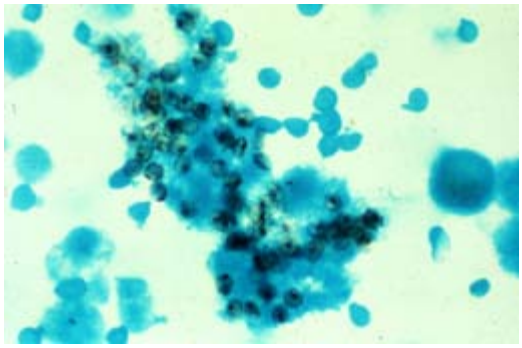

35. Silver stain showing *Pneumocystis carinii* cysts in the lungs:
Note the crushed ping pong ball appearance
(Id344)

Previous | Next

Return to Top | Return to Image Index

Pathology II Images

Syllabus | Lecture Schedule | Images - Pathology I | Images - Pathology II

Infectious Disease
Parasitology

1 | 2 | 3 | 4 | 5 | 6

It is against copyright laws to make *electronic or printed* copies of these slides!!

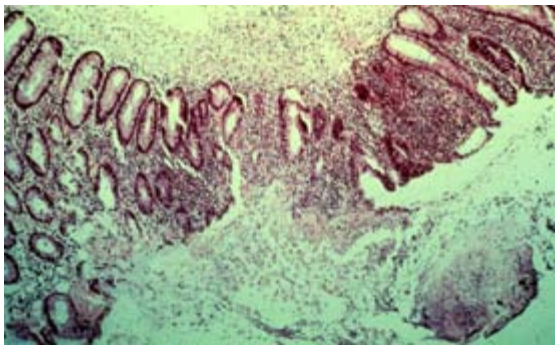

1. Flask shaped ulcer in cecum due to *Entameba histolytica*:
In the middle of the biopsy, there is defect in the mucosa and a stream of inflammatory cells extending out into the lumen of the bowel (bottom of the slide) and into the submucosa. Organisms are not visible at this magnification. **(Id440)**

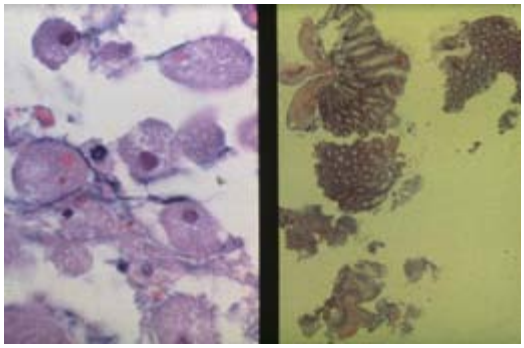

2. *Entameba histolytica* trophozoites with erythrophagocytosis and necrotic debris from ulcer in the cecum:
The red dots in the trophozoites represent RBCs **(Id302)**

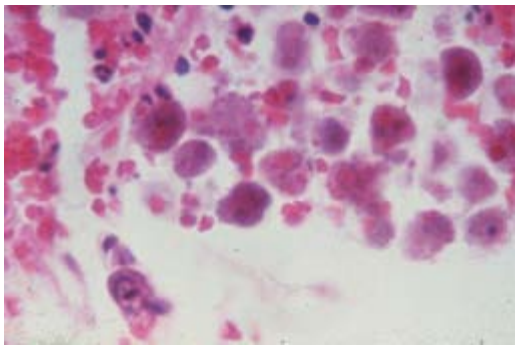

3. Cecal biopsy showing trophozoites of *Entameba* histolytica:
Note erythrophagocytosis **(Id429)**

4. Needle aspirate of liver abscess in a patient with amebiasis due to *Entameba histolytica*:
Note the brown discoloration of the aspirate fluid, which some have described as having an "anchovy paste" appearance **(Id424)**

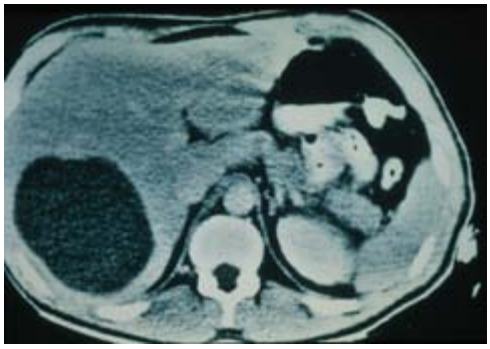

5. CT of liver showing an abscess due to *Entameba histolytica*:
Trophozoites gain entry into the portal vein tributaries draining the cecum. Most abscesses are in the right lobe. Rx is metronidazole. **(Id436)**

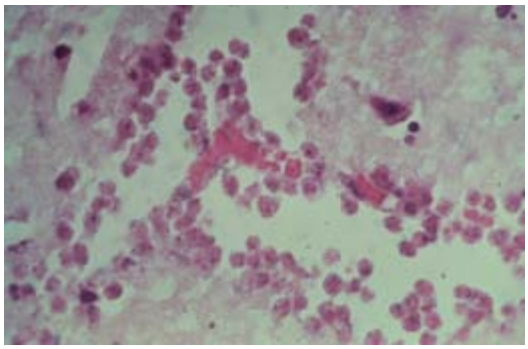

6. *Naegleria fowleri* in the brain:
Naegleria is an ameba. The infection is usually contracted from swimming in fresh water lakes that are stagnant. **(Id298)**

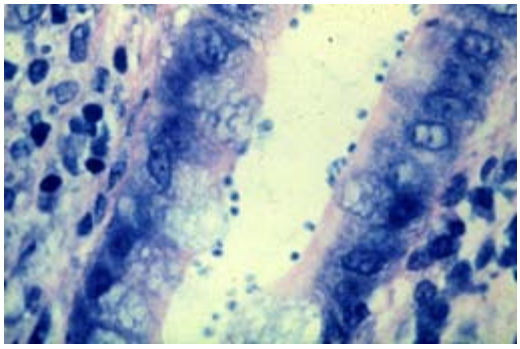

7. Small bowel biopsy showing *Cryptosporidium parvum* acid-fast oocysts in mucous layer:
Cryptosporidium is a sporozoan that is the MCC of diarrhea in patients with AIDS. It is a frequent contaminant of reservoirs and produces epidemics of diarrhea (e.g., Milwaukee). Entero-Test (string test) is positive. **(Id040)**

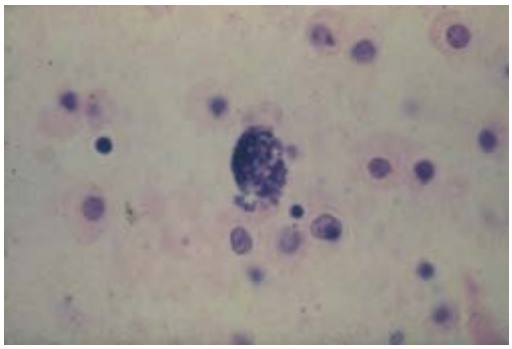

8. Brain with cyst of *Toxoplasma gondii*:
Toxoplasma is a sporozoan. It is the MCC of a space occupying lesion in the brain in a patient with AIDS. It generally occurs when the helper T cell count is < 100 cells/Âµ/L. Pregnant women should avoid changing cat litter. **(Id425)**

9. Multiple ring forms in RBCs in patient with *Plasmodium falciparum* infection:
Plasmodium species are sporozoans.

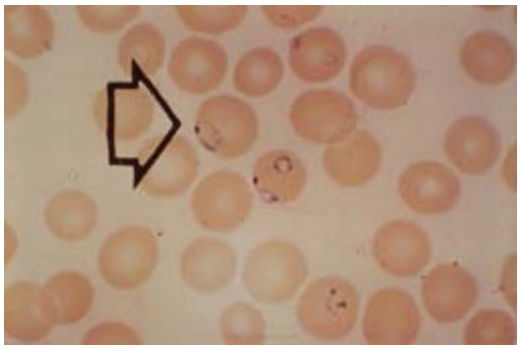

Falciparum malaria only has ring forms and gametocytes in the peripheral blood. Multiple infestation of RBCs by ring forms is a characteristic finding of this type of malaria. Fever and hemoglobinuria coincide with intravascular rupture of the RBCs. Extravascular hemolysis by macrophages also occurs. **(Id280)**

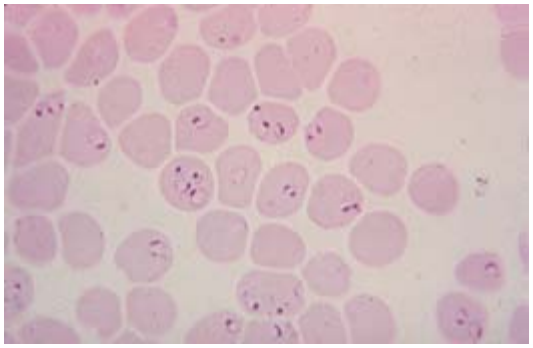

10. Peripheral blood with ring forms and multiple infestation of RBCs- *Plasmodium falciparum*:
Multiple infestation of RBCs by ring forms is a characteristic finding of this type of malaria. **(Id437)**

Previous | Next

Return to Top | Return to Image Index

Pathology II Images

Infectious Disease
Parasitology

It is against copyright laws to make *electronic or printed* copies of these slides!!

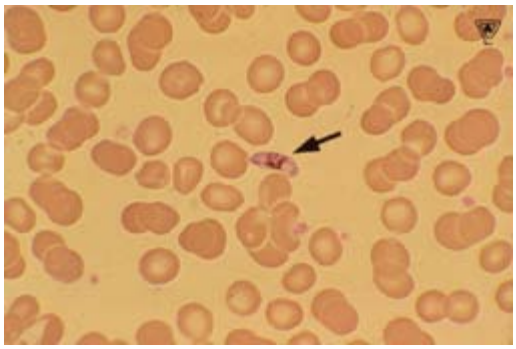

11. Peripheral blood with a banana-shaped gametocyte of *Plasmodium falciparum*:
No ring forms are noted in the slide. Note that the gametocyte is not located within an RBC. **(Id281)**

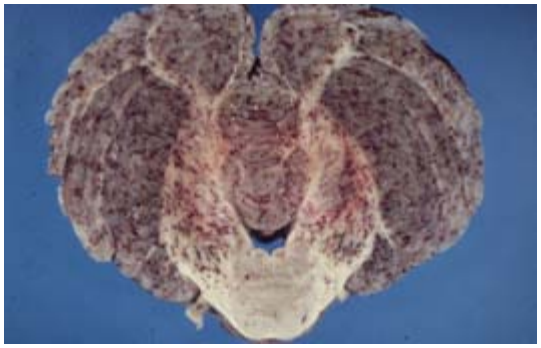

12. Pinpoint hemorrhages in cerebellum in a patient with cerebral malaria due to *Plasmodium falciparum*:
Cerebral malaria is associated with hemorrhage of the small vessels since infected RBCs agglutinate and stick to the wall of the blood vessels causing blockage to blood flow and eventual rupture. **(Id296)**

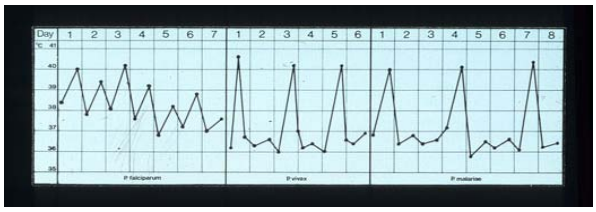

13. Fever patterns of *Plasmodium* species:
Fever coincides with intravascular hemolysis of the RBCs. *Plasmodium falciparum* (left side of the schematic) has a quotidian pattern, which refers to daily spikes of fever that persist for a few days and occasionally break every couple of days. *Plasmodium vivax* or *ovale* have a tertian pattern (middle of the schematic), which is fever q. 48 hrs. *Plasmodium malariae* has a quartan pattern (right of the schematic), which occurs q. 72 hrs. **(Id282)**

14. Colon biopsy demonstrating *Balantidium coli*:
Balantidium is a ciliate. It produces

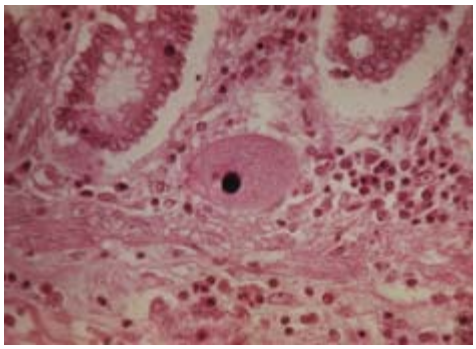

colonic ulcers leading to bloody diarrhea. **(Id434)**

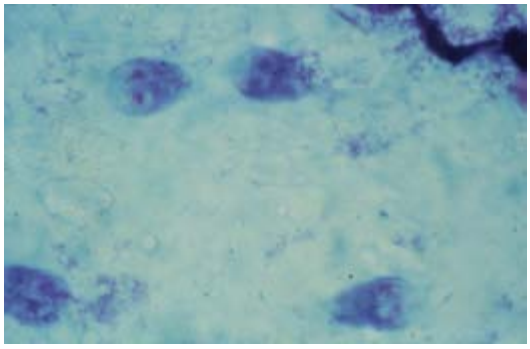

15. Duodenal aspirate showing trophozoites of *Giardia lamblia:*
Giardia is a flagellate. Note the owl eye appearance of the organism. It produces chronic diarrhea often associated with malabsorption. Entero-Test (string test) is positive. Rx is metronidazole. **(Id042)**

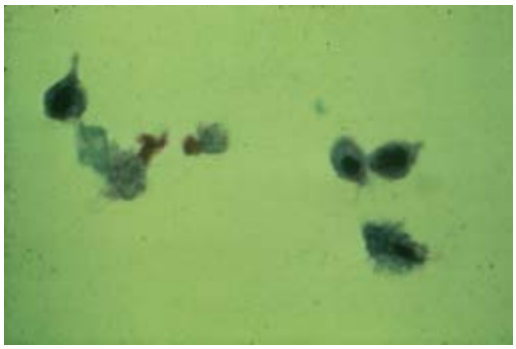

16. Hanging drop preparation of *Trichomonas vaginalis*:
Trichomonas is a flagellate. Note the pear shaped organisms. There are no cyst forms for this organism. **(Id351)**

17. Frothy greenish discharge of *Trichomonas vaginalis* vaginitis:
It is considered an STD. Rx patient and partner with metronidazole. **(Id368)**

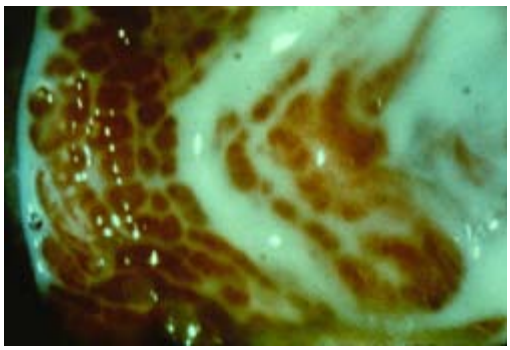

18. Vaginal vault in a patient with vaginitis due to *Trichomonas vaginalis*:
Note the intense erythema and pus of the mucosa **(Id369)**

19. Trypanosomal form in blood in

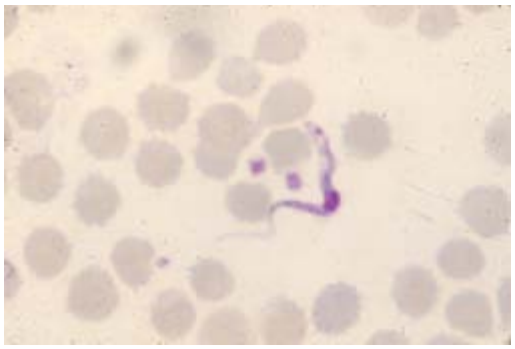

African sleeping sickness due to *Trypanosoma brucei* gambiense (hemoflagellate):
Only the extracellular form (trypanosomes) are present in this disease. The vector is the tsetse fly. Prominent posterior cervical lymphadenopathy is called Winterbottom's sign. Similar to relapsing fever due to Borrelia recurrentis, there is antigen variation. Death is by starvation. **(Id433)**

20. Reduvid bug:
Also called the "kissing bug" is the vector for the American trypanosomiasis due to *Trypanosoma cruzi* **(Id016)**

Previous | **Next**

Return to Top | **Return to Image Index**

Pathology II Images

Infectious Disease
Parasitology

It is against copyright laws to make *electronic or printed* copies of these slides!!

21. Romana's sign in girl- Chagas disease due to *Trypanosoma cruzi*:
Note the periorbital edema due to rubbing the eye when the Reduvid bug defecates in this area. Both trypanosomes (extracellular) and leishmanial forms (intracellular) are present in the disease. Xenodiagnosis is where a sterile Reduvid bug is allowed to bite the patient and then the bug is examined for the organism. **(Id277)**

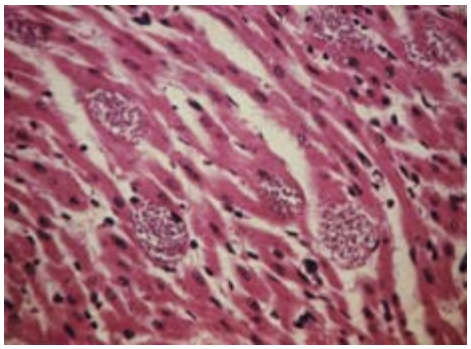

22. Leishmanial forms of *Trypanosoma cruzi* in cardiac muscle:
Chronic heart failure from myocarditis is a common cause of death in South and Central America. Leishmanial forms also destroy ganglion cells in the distal esophagus and rectum causing acquired achalasia and Hirschsprung's disease, respectively. **(Id276)**

23. Leishmanial forms of *Leishmania donovani* complex (visceral leishmaniasis) phagocytosed by a macrophage:
In leishmaniasis, only the leishmanial form is present in disease. Phlebotomus (sandfly) is the vector for the disease.

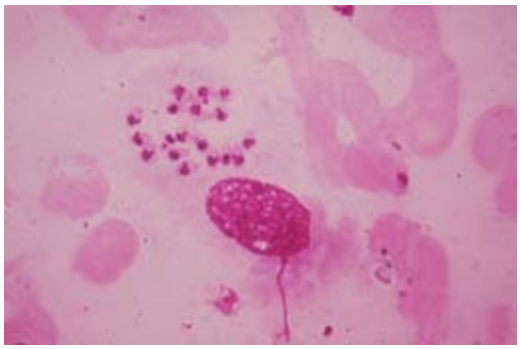

Visceral leishmaniasis is called kala azar and is characterized by massive splenomegaly and eosinophilia. Macrophages contain the leishmanial forms, which are very similar in appearance to the yeast forms of *Histoplasma* and the Donovan bodies in granuloma inguinale. **(Id289)**

24. Skin lesions of cutaneous leishmaniasis due to *Leishmania tropica complex*:
Note the circular sores on the arm. Common problem in the Gulf war in the Middle East. **(Id297)**

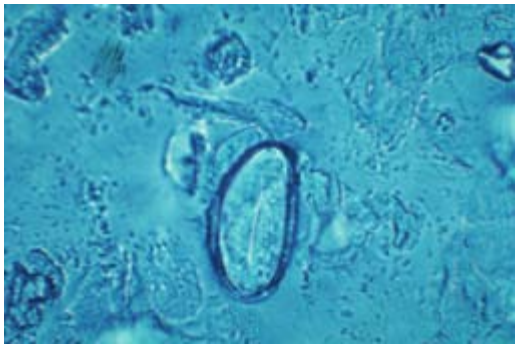

25. Scotch tape preparation taken from the perianal area showing egg of *Enterobius vermicularis* (pinworm, nematode):
Note the flat side to the embryonated egg. Anal pruritus is the key feature of the disease and is due to the adult worms laying eggs around the anus in the early morning hours. There is no eosinophilia, since it is non-invasive. Using two-sided tape and compressing it around the anus attaches to the eggs and allows for easy diagnosis under the microscope. Rx is albendazole **(Id275)**

26. Bowel with *Trichuris trichiura* (nematode):
Trichuris trichiura is also called the whipworm. Note the organisms attached to the cecum. Patients experience diarrhea and children may develop rectal prolapse. Rx is albendazole. **(Id018)**

27. Egg of *Trichuris trichiura*:
Note the characteristic egg with a plug at both ends **(Id422)**

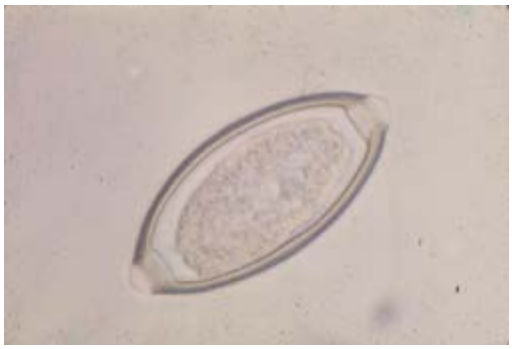

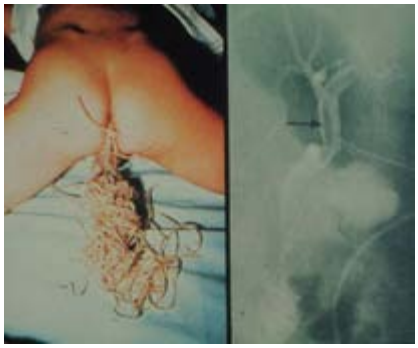

28. Child with passage of adult *Ascaris lumbricoides* worms (nematodes) and x-ray demonstrating location in the bowel:
Larval phase is in the lungs and produces cough, pneumonitis, and eosinophilia. Adults cause intestinal obstruction and are not invasive, hence no eosinophilia. **(Id045)**

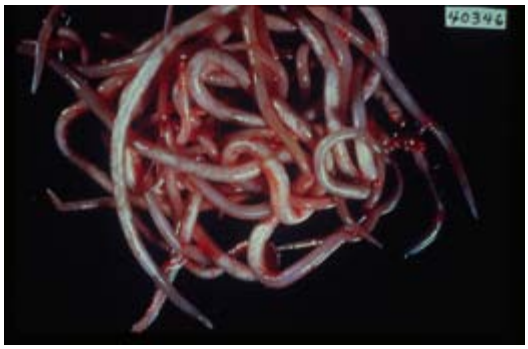

29. Adult worms of *Ascaris lumbricoides*:
Adults cause intestinal obstruction and are not invasive, hence no eosinophilia. Rx is albendazole or mebendazole. **(Id274)**

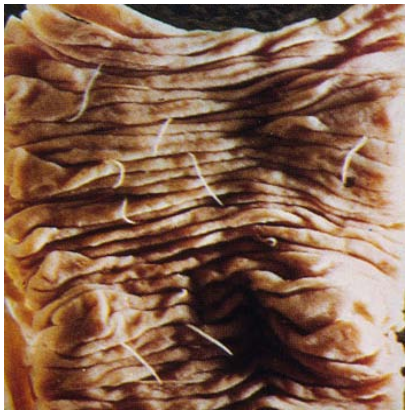

30. Gross of small bowel showing adult worms of *Necator americanus* (nematode) attached to villi:
Necator is also called a hookworm. The larval phase is in the lungs and is swallowed. The mouth parts of adults attach to the tips of villi leading to blood loss and iron deficiency anemia. Filariform larva produced from the eggs of adult worms infect the soil and can penetrate the feet. Rx is albendazole. **(Id043)**

Previous | Next

Return to Top | Return to Image Index

Pathology II Images

Infectious Disease
Parasitology

It is against copyright laws to make *electronic or printed* copies of these slides!!

31. Skin tracts of migrating larval forms ("creeping eruption") of *Ancylostoma braziliensis* (nematode):
Cutaneous larva migrans is caused by dog and cat hookworms. It is usually contracted by children playing on sandy beaches or sandy playgrounds where dogs and/or cats urinate. Larvae penetrate the skin and produce serpiginous tunnels in the skin which causes intense pruritus and scratching along with eosinophilia. Adults do not form in man (intermediate host), only in infected dogs and cats (definitive hosts). Rx is ethyl chloride spray and ivermectin. **(Id055)**

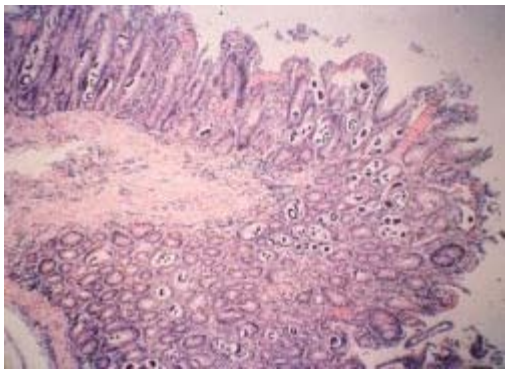

32. Bowel with *Strongyloides stercoralis* (nematode):
Infective filariform larvae in the soil penetrate the skin and migrate to the lungs. They are swallowed and develop into adult worms which burrow into the wall of the bowel, where they mate and lay eggs which hatch rhabditiform larvae, which enter the lumen and are passed into feces. In soil, they molt and produce the infective filariform larvae. Autoinfection and superinfection (especially in AIDS) may occur. Positive Entero-Test (string test). Rx is ivermectin or albendazole. **(Id019)**

33. Rhabditiform larva in stool preparation of *Strongyloides stercoralis*:
Note that this is the only worm that

does not normally pass eggs in the stool **(Id293)**

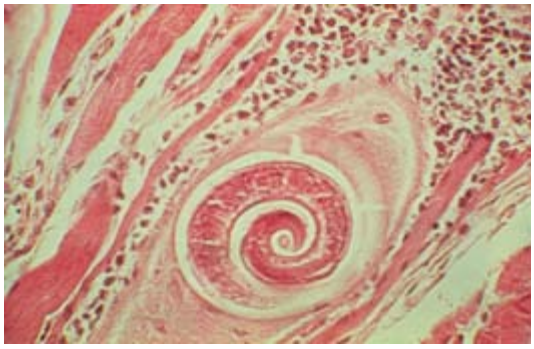

34. *Trichinella spiralis* (nematode) in skeletal muscle:
Contracted by eating poorly cooked pork containing the encysted larvae. Larva are released after digestion and develop into adult forms that mate and produce additional larvae. They penetrate the bowel mucosa and are hematogenously spread throughout the body, particularly skeletal muscle where they become encysted (often calcified). Rx is corticosteroids and albendazole. **(Id273)**

35. Eye swelling in patient with trichinosis due to *Trichinella spiralis*:
Periorbital edema due to larva **(Id287)**

36. Patient with lymphedema due to *Wucheria bancrofti* (nematode) infection:
Microfilaria of *Wucheria bancrofti* or *Brugia malayi* are the causative agents of filariasis. Vector is mosquitos. Microfilaria circulate in the bloodstream at night and enter into the lymphaticsg mature and produce an inflammatory reaction resulting in lymphedema (elephantiasis) of the legs, scrotum,

etc. Rx is ivermectin. **(Id272)**

37. Scrotal lymphedema due to lymphatic blockage by *Wucheria bancrofti*:
See above discussion **(Id435)**

38. Subcutaneous nodule on the head of a child with *Onchocerca volvulus* (nematode):
Microfilaria are transmitted to man via the bite of an infected blackfly (*Simulium*). Larva migrate into the skin and lymphatic tissue and differentiate into adults. Adults produce microfilaria that migrate across the eye and produce blindness, hence the name "river blindness." Microfilaria do not enter the bloodstream and there is no periodicity (night or day time rhythm). Rx is ivermectin and surgical removal of the nodules.

(Id303)

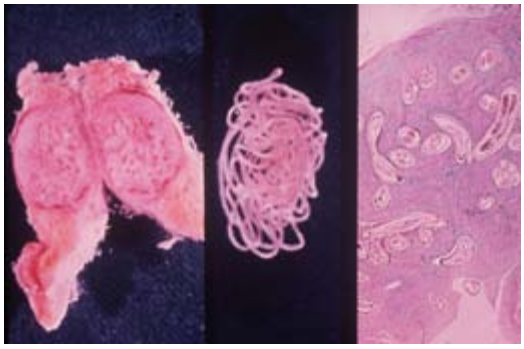

39. Adult worms of *Oncocerca volvulus* in subcutaneous tissue:
See above discussion **(Id301)**

40. Microfilaria of *Oncocerca volvulus* migrating across the eye (river blindness):
See above discussion **(Id418)**

Previous | Next

Return to Top | Return to Image Index

Pathology II Images

Infectious Disease
Parasitology

It is against copyright laws to make *electronic or printed* copies of these slides!!

41. Patient with *Dracunculus medinensis* (nematode):
Infective larvae of *Dracunculus medinensis* (guinea worm) are contracted by man after eating the fresh water crustacean Cyclops. Larvae migrate through the intestinal tract into deep subcutaneous tissue where they develop into migrating adults that attain great length (longest worm). Rx is surgical removal of pre-emergent worm + metronidazole. **(Id021)**

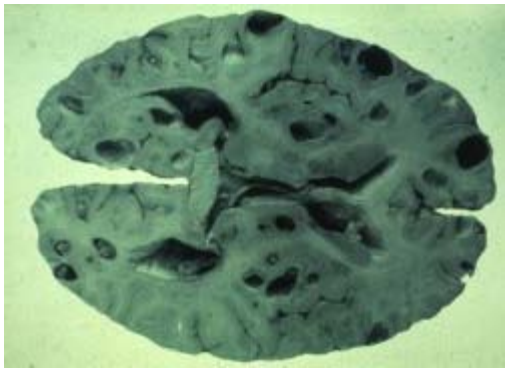

42. Brain with cysticercosis due to the larval form of *Taenia solium* (pork tapeworm, cestode):
Note multiple cyst cavities in the brain. In the adult worm infection in man, man contracts the disease by eating larvae in undercooked pork (man definitive host). Adult worms mate in the intestine to produce eggs. In cysticercosis, the patient eats the eggs from a human host which develop into larvae called cysticerci (man is the intermediate host), which disseminate throughout the body (e.g., eyes, brain) and produce cysticercosis. CNS lesions produce seizures. Rx is praziquantel. **(Id022)**

43. Liver cyst with scolices of *Echinococcus granulosus* (cestode):
The life cycle is as follows: sheep with larvae (intermediate host)g eaten by dog (develop adults who lay eggs, definitive host)g man ingests the egg (develops larvae which penetrate the liver, intermediate host). Note the fluid filled hydatid cysts that contain thousands of scolices (see next slide). Cyst fluid is highly antigenic and may produce an anaphylactic reaction if cyst fluid enters the peritoneum. Common disease in Greek and Basque sheepherders. Rx is percutaneous drainage

+ albendazole **(Id304)**

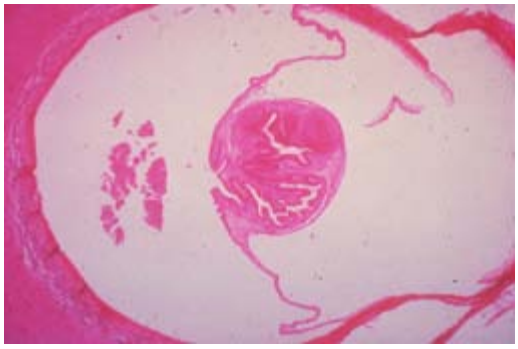

44. Scolex of *Echinococcus granulosus* (cestode):
Note the scolex, which has hooks for attachment if it ever developed into an adult, which it cannot do in man **(Id421)**

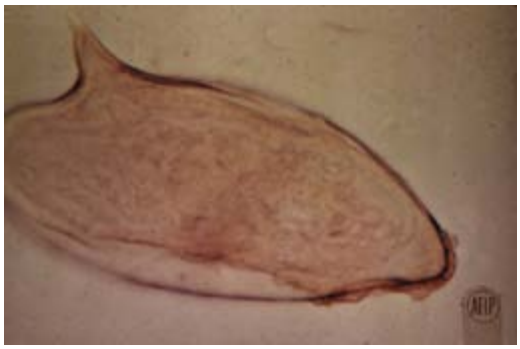

45. *Schistosoma mansoni* (trematode) egg:
Note the sharp lateral spine. Schistosomes have the following life cycle: egg (human)g ciliated miracidia larvaeg infect snails (1st intermediate host)g produce fork tailed cercaria larvaeg penetrate skin of humang produce disease **(Id271)**

46. Patient with hepatosplenomegaly, ascites, and esophageal varices (x-ray) due to pipestem cirrhosis secondary to *Schistosoma mansonii*:
S. mansonii favors the intrahepatic portal veins. Penetration of the skin by the larvae of *S. mansonii* produces pruritus ("swimmers itch"). Larvae develop into adult worms that travel against the portal vein circulation and deposit eggs, to which the host develops an inflammatory response marked by concentric fibrosis ("pipe stem cirrhosis") in the vessel wall (see next slide). This leads to portal hypertension with ascites (note abdominal distension, splenomegaly (note outline of enlarged spleen), and esophageal varices (note the barium study of the esophagus). Rx is praziquantel. **(Id047)**

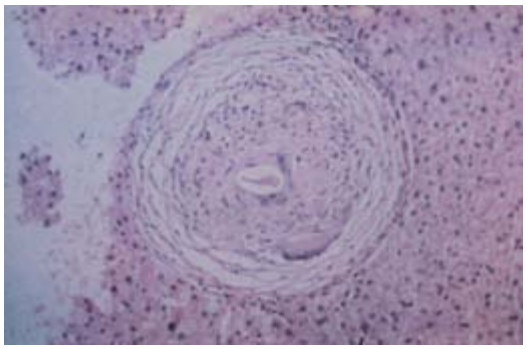

47. Liver biopsy with "pipestem cirrhosis" due to eggs of *Schistosoma mansonii*:
Note the concentric circles of fibrosis around the egg of *Schistosoma mansonii*. **(Id427)**

48. *Schistosoma hematobium* (trematode) egg in urine:
Note the nipple at one end of the egg **(Id270)**

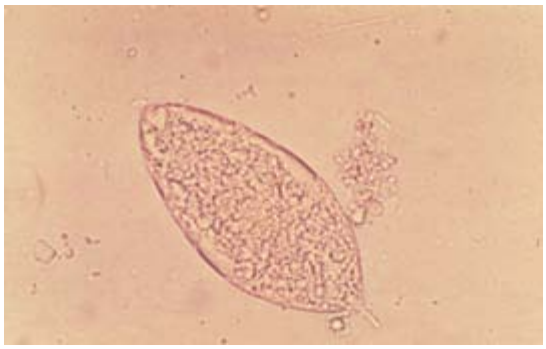

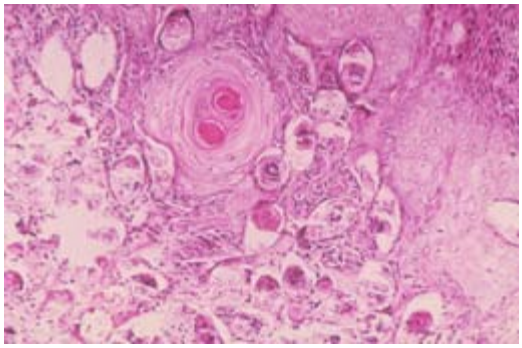

49. Urinary bladder with squamous metaplasia due to *Schistosoma hematobium*:
Note the numerous eggs in the submucosal venous plexus and the keratinization of the transitional epithelium just off center and to the left. Squamous cancer is a potential complication. Rx is praziquantel. **(Id430)**

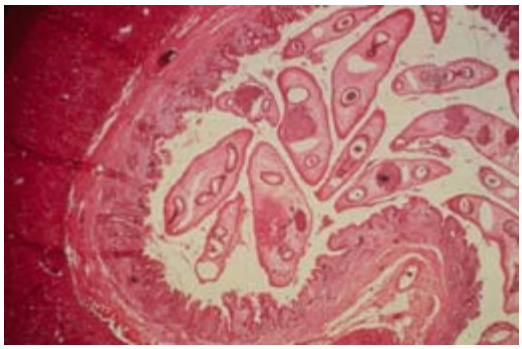

50. Common bile duct with *Clonorchis sinensis* (trematode):
The life cycle for non-schistosomal disease is as follows: 3. in non-schisto-somal disease, the cycle is as follows: egg (human) g ciliated miracidia larvae g infect snails (1st intermediate host) g produce fork tailed cercaria larvae g infect a 2nd intermediate host: â€¢ aquatic vegetation (*Fasciolopsis buski, Fasciola hepatica*), â€¢ fish (*Clonorchis sinensis*), â€¢ crabs (*Paragonimus westermani*) g form infective metacercaria g man ingests the 2nd intermediate host g disease. In clonorchiasis, the patient ingests larvae in fish (usually fish paste). Larvae ascend the bile ducts and enter the liver and gallbladder and become adults in the bile ducts (present in this slide). Jaundice and cholangiocarcinoma are potential complications. Rx is praziquantel. **(Id439)**

Previous | **Next**

Return to Top | **Return to Image Index**

Pathology II Images

Infectious Disease
Parasitology

It is against copyright laws to make *electronic or printed* copies of these slides!!



51. *Scorpion (arthropod)*:
Poisonous species capable of causing fatality live in Southwestern deserts (*Centruroides gertschi*). The poison is a neurotoxin. The bite site shows no initial reaction g increased sensation g no sensation in the area of the bite g whole extremity becomes numb g increased blood pressure g ascending motor paralysis g death. **(Id431)**

52. Intertriginous burrow in an adult with scabies due to the human itch mite (Sarcoptes scabies, arthropod):
The human itch mite causes tissue injury by adult females boring into the stratum corneum (see below). Burrows are visible as dark lines between the fingers, at the wrists, on the nipples, or on the scrotum. Females lays eggs at the end of the tunnel, which produces intense pruritus. In adults, the disease is limited to the webs between the fingers and other intertriginous areas and spares the soles, palms, face and head. In infants, there are no burrows and a rash occurs on the palms, soles, face and head (see below). Rx is permethrin cream or

lindane (alternative drug). **(Id292)**

53. Rash on hand in a child with scabies due to the human itch mite:
See above discussion **(Id291)**

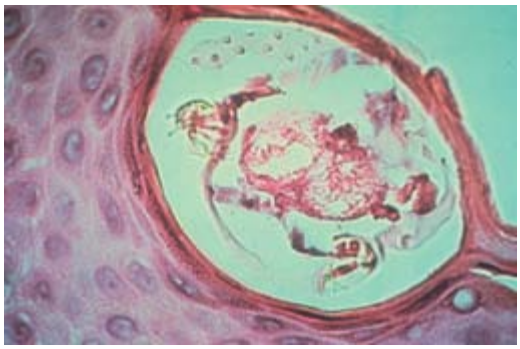

54. Microscopic of human itch mite imbedded in epidermis in a patient with scabies:
See above discussion **(Id295)**

55. Hair on scalp with *Pediculus humanis capitis* (head louse) and "nits-eggs" on the hair shafts:
The louse lays its "nits" (eggs) on hair shafts. Rx is permethrin (kills newly hatched lice) followed by lindane (Kwell), if the initial Rx is unsuccessful. Combs for removing the lice are available. Monkeys are outstanding for removal. **(Id056)**

Previous | Next

Return to Top | Return to Image Index

Pathology II Images

Syllabus | Lecture Schedule | Images - Pathology I | Images - Pathology II

Infectious Disease: Virus, Chlamydia, Rickettsia, Mycoplasma

1 | 2 | 3 | 4 | 5 | 6

It is against copyright laws to make *electronic or printed* copies of these slides!!

Virus

1. Hand-foot-mouth disease due to coxsackie virus:
Vesicular rash in these areas **(Id207)**

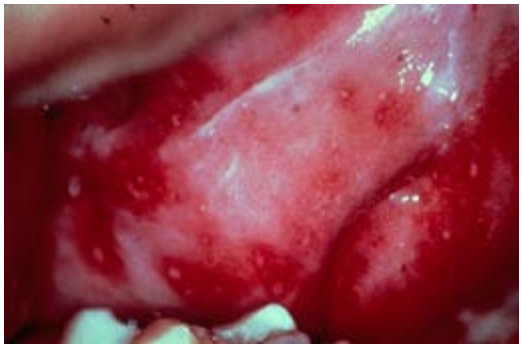

2. Buccal mucosa with lesions of herpangina due to coxsackie virus:
Note erythematous areas with white colored ulcers **(Id447)**

3. Herpangina due to coxsackie virus:
Note erythematous areas with white colored ulcers **(Id463)**

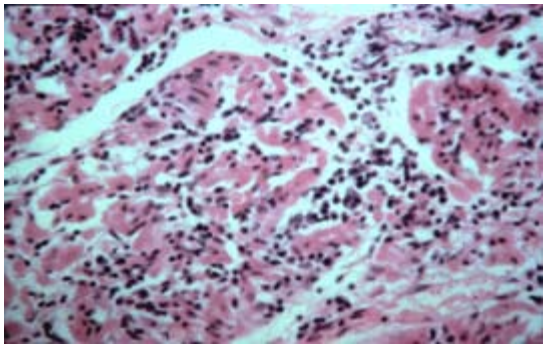

4. Myocarditis due to coxsackie virus:
Note the lymphocytic infiltrate with destruction of cardiac cells. MCC of myocarditis and common cause of congestive cardiomyopathy. **(Id448)**

5. Patient with verruca vulgaris on fingers due to human papilloma virus:
Note the verrucoid appearance of the lesion. They may also occur on the plantar surface of the foot. **(Id312)**

6. Condyloma acuminata (venereal wart) of the penis due to human papilloma virus:
Note the fern-like appearance of the lesion. Due to HPV 6, 11. **(Id363)**

7. Condyloma acuminata of shaft of penis due to human papilloma virus:
Note verrucoid appearance of lesions **(Id455)**

8. Condyloma acuminata of labia due to human papilloma virus:
These lesions could easily be confused with condyloma latum in secondary syphilis

(Id457)

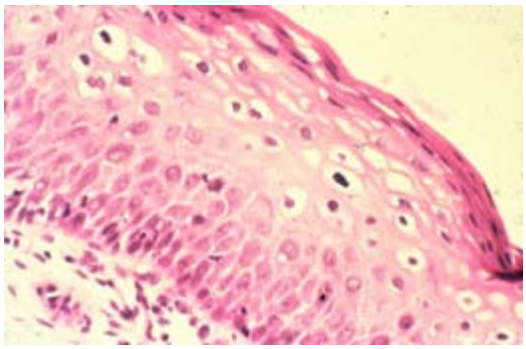

9. Cervical biopsy demonstrating koilocytosis of squamous cells due to human papillomavirus:
Note the squamous cells with spaces in the cytosol and pyknotic nuclei. These cells contain the virus. **(Id362)**

10. Child with gingivostomatitis due to *Herpes simplex*:
Primary herpes infections are systemic in that they have fever and painful lymphadenopathy. Infections usually occur in children and cause painful ulcerations on the lips and in the oral cavity. **(Id210)**

Previous | Next

Return to Top | Return to Image Index

Pathology II Images

Infectious Disease: Virus, Chlamydia, Rickettsia, Mycoplasma

It is against copyright laws to make *electronic or printed* copies of these slides!!

Virus

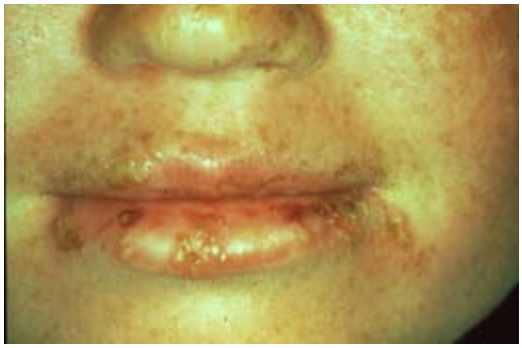

11. Patient with recurrent *Herpes simplex* involving the upper and lower lips:
Recurrent herpes is not systemic. Viruses remain latent in sensory ganglia and may recur at any time. **(Id052)**

12. Perianal vesicles in a male homosexual with *Herpes genitalis*:
Recurrent herpes in perianal area related to unprotected anal intercourse **(Id450)**

13. Genital ulcers of labia in a woman with *Herpes genitalis*: Recurrent herpes **(Id365)**

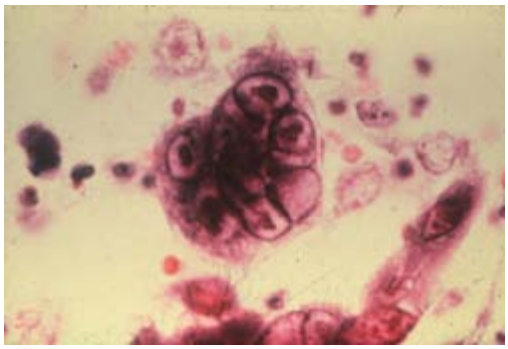

14. Tzanck prep with multinucleated squamous cell with intranuclear inclusions in a patient with *Herpes genitalis*:
Tzanck preps involve unroofing a vesicle and scrapping the base of the lesion. Herpes inclusions are intranuclear. Squamous cells are usually multinucleated. Varicella has similar inclusions. **(Id364)**

15. Temporal lobe necrosis due to *Herpes simplex* encephalitis:
Produces significant neurologic damage **(Id458)**

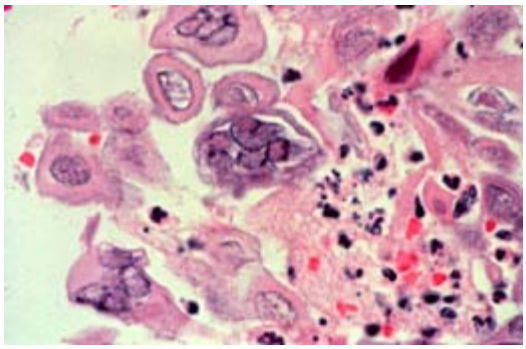

16. *Herpes simplex* esophagitis in a patient with AIDS:
Note multinucleated squamous cells with intranuclear inclusions. This is an AIDS-defining opportunistic infection and produces odynophagia. **(Id208)**

17. Finger with herpetic whitlow due to *Herpes simplex*:
Due to traumatic implantation. Common in dentists. **(Id209)**

18. Herpetic whitlow on finger due to *Herpes simplex*:
Due to traumatic implantation. Common in dentists. **(Id316)**

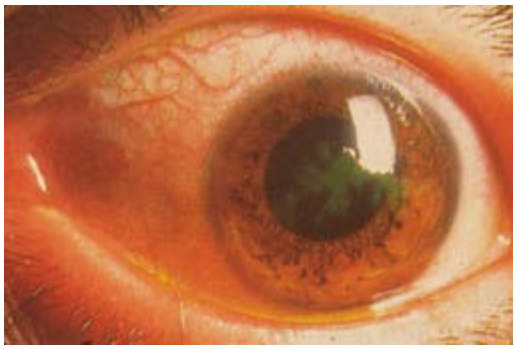

19. Dendritic ulcer of the eye due to *Herpes simplex*:
Note the root-like ulceration of the conjunctiva **(Id451)**

20. HIV positive patient with hairy leukoplakia due to Epstein Barr virus infection of the tongue:
The lesion is painless and leaves a bloody base when scrapped off. It is not AIDS-defining, however, it commonly occurs just prior to an AIDS-defining opportunistic infection. It is treated with acyclovir, but recurs once Rx is stopped. **(Id053)**

Previous | Next

Return to Top | Return to Image Index

Pathology II Images

Infectious Disease: Virus, Chlamydia, Rickettsia, Mycoplasma

It is against copyright laws to make *electronic or printed* copies of these slides!!

Virus

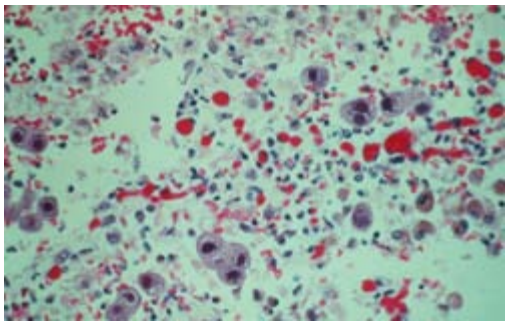

21. Basophilic intranuclear inclusions of cytomegalovirus in a lung biopsy:
Many of the cells are enlarged and contain nuclei with large basophilic intranuclear inclusions. Ganciclovir is the Rx of choice. **(Id206)**

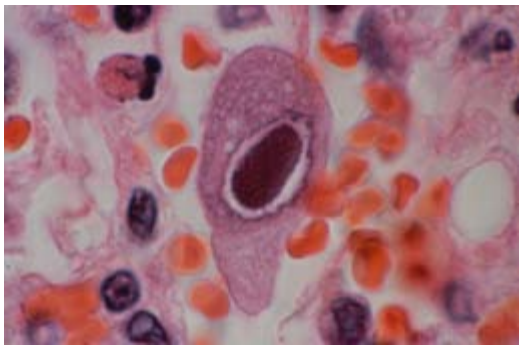

22. Lung biopsy showing cell with large basophilic intranuclear inclusion of cytomegalovirus:
Cell with large basophilic intranuclear inclusion **(Id050)**

23. Gross of periventricular calcification in the brain of a child with congenital cytomegalovirus infection:
CMV is the MC congenital infection. Urine is the best culture medium. **(Id214)**

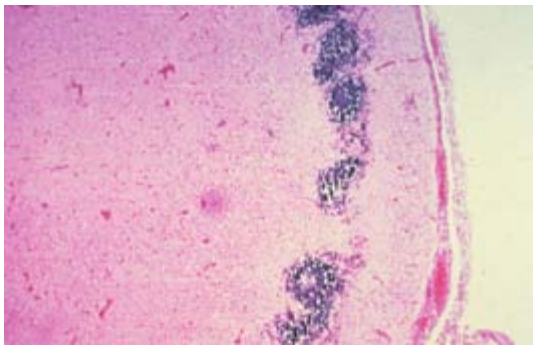

24. Microscopic of periventricular calcification in the brain of a child with congenital cytomegalovirus infection:
CMV is the MC congenital infection. Urine is the best culture medium. **(Id215)**

25. Patient with roseola (exanthem subitum) due to HSV-6:
Patients initially have very high fevers and then as the fever subsides a maculopapular rash appears as noted in this patient **(Id320)**

26. Vesicles and pustules of varicella:
Note that they are in different stages of development. There is an association with Reye syndrome if patients receive salicylates. **(Id315)**

27. *Herpes zoster* in outer ear canal (Ramsay Hunt syndrome):
Note the vesicles in the outer ear. This is the sensory division of CN VIII. The virus is

latent in cranial ganglion cells. **(Id313)**

28. *Herpes zoster* (shingles) involving the ophthalmic division of CN V:
Note also the irritation of the conjunctiva, whose afferent is CN V. **(Id314)**

29. *Herpes zoster* involving dermatome on lower back:
Vesicles follow a dermatome **(Id200)**

30. Patient with *Herpes zoster* involving shoulder:
Vesicles follow a dermatome **(Id326)**

Previous | Next

Return to Top | Return to Image Index

Pathology II Images

Infectious Disease: Virus, Chlamydia, Rickettsia, Mycoplasma

It is against copyright laws to make *electronic or printed* copies of these slides!!

Virus

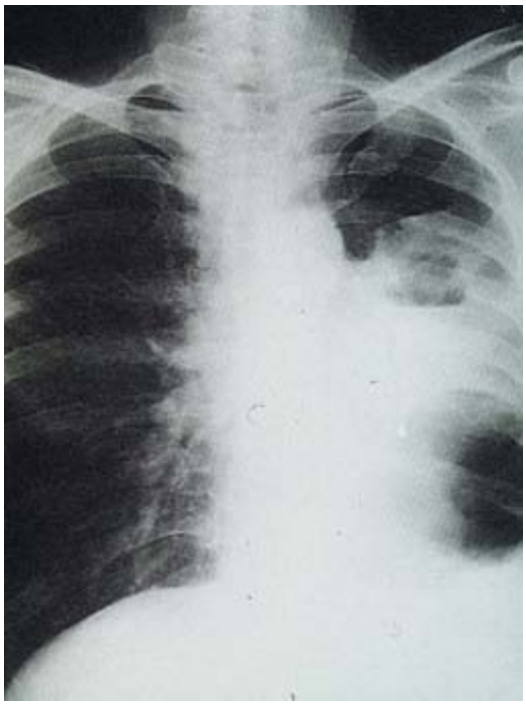

31. Influenza pneumonia with secondary bacterial pneumonia with abscess due to *Staphylococcus aureus*:
Influenza commonly produces a viral pneumonia that gets superinfected by a bacteria, usually Staphylococcus aureus. **(Id212)**

32. Child with mumps involving the parotid gland:
Note the bilaterally enlarged parotid glands. Serum amylase is elevated. **(Id031)**

33. Patient with mumps involving both parotid glands:
Note the bilaterally enlarged parotid glands. Serum amylase is elevated. **(Id049)**

34. Patient with mumps orchitis: Note the enlarged, red scrotal sac. Unilateral orchitis is the rule, hence infertility is uncommon. **(Id048)**

35. Child with rubeola (regular measles):
Note the runny nose and the maculopapular rash **(Id311)**

36. Koplik spots on buccal mucosa in rubeola:
Note the erythematous buccal mucosa and the white spots superimposed on the base. The rash follows these lesions. **(Id029)**

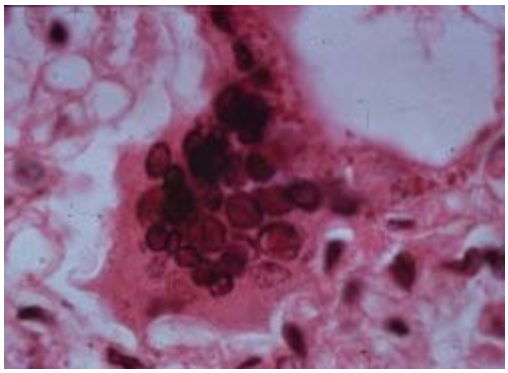

37. Warthin-Finkeldey multinucleated giant cell in rubeola: These are commonly found in lymphoid tissue (e.g., appendix) and in the lungs in measles pneumonia. **(Id030)**

38. Woman with rash of rubella: Note the maculopapular rash in this woman, who happens to be pregnant. Rubella is teratogenic unlike rubeola. Arthritis and painful postauricular lymphadenopathy are common findings. Sensorineural hearing loss is the MC complication of congenital rubella. **(Id322)**

39. Slapped face appearance of parvovirus: Also called fifth's disease (erythema infectiosum). Parvovirus also produces aplastic anemia, pure RBC aplasia, spontaneous abortions, and arthritis. **(Id028)**

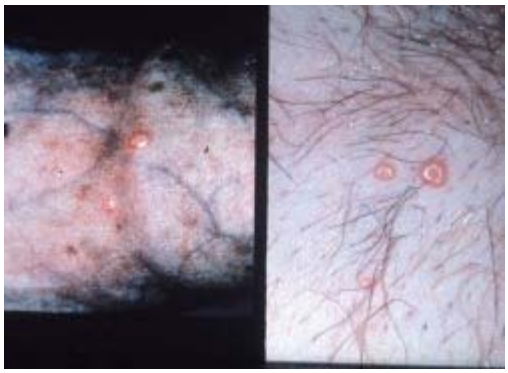

40. Molluscum contagiosum (Poxvirus): Note the umbilicated lesions with the granular material in the center. These resolve spontaneously in a few weeks to months. **(Id026)**

Previous | Next

Return to Top | Return to Image Index

Pathology II Images

Infectious Disease: Virus, Chlamydia, Rickettsia, Mycoplasma

It is against copyright laws to make *electronic or printed* copies of these slides!!

Virus

41. Molluscum contagiosum-poxvirus: Note the umbilicated lesions with the granular material in the center. These resolve spontaneously in a few weeks to months. **(Id328)**

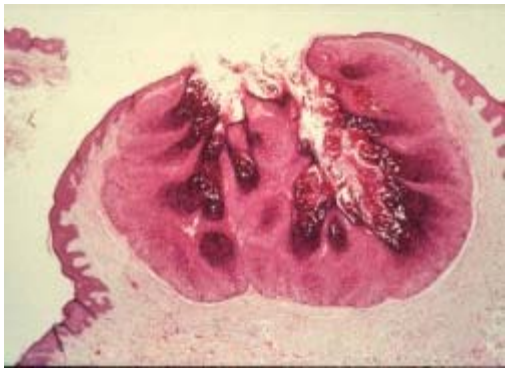

42. Histologic section of molluscum contagiosum: The crateriform appearance is apparent. The dark staining squamous cells contain molluscum bodies representing the virus. **(Id027)**

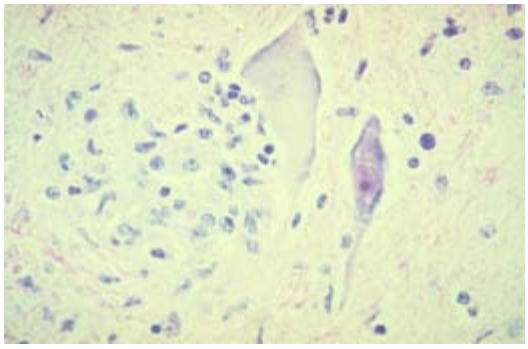

43. Neuronophagia of anterior horn cells by microglial cells in patient with polio: Patients develop paralysis, which may or may not resolve. The infection occurs in the summer months. **(Id205)**

44. Purkinje cell with Negri body in rabies: Note the eosinophilic intracytoplasmic inclusion of the virus. Skunks are the MCC of rabies in the United States. **(Id449)**

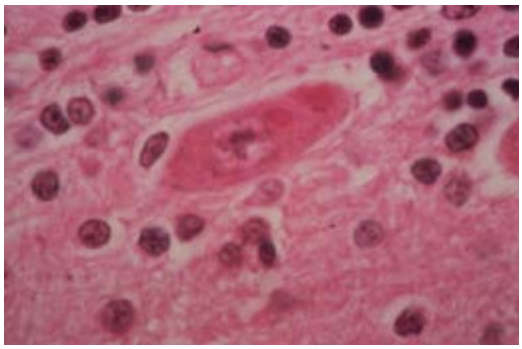

45. Needle tracks of arms in IV drug abuser with chronic hepatitis B:
The MC systemic infection in IV drug abuse is HBV. The MC infection transmitted by an accidental needle stick is also HBV owing to its high viral burden in the blood. **(Id460)**

Chlamydia

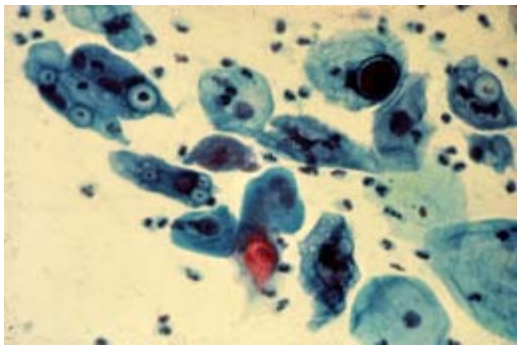

46. Cervical Pap smear showing vacuoles with elementary bodies (dots) in a patient with *Chlamydia trachomatis* infection:
Chlamydia trachomatis is the MC STD. Infection occurs during the second week after sexual exposure. In men, it is called nonspecific urethritis while in women it is called the acute urethral syndrome. **(Id361)**

47. Newborn with ophthalmia neonatorum due to *Chlamydia trachomatis*:
This infection is transmitted via contamination of the eyes by an infected endocervix during delivery. Erythromycin eye drops at birth help prevent this infection. **(Id378)**

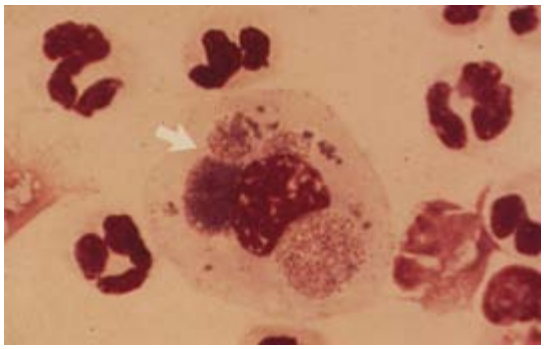

48. Elementary body of *Chlamydia trachomatis* in a conjunctival scrapping in a patient with trachoma:
Trachoma is the MCC of global blindness **(Id216)**

49. Patient with trachoma due to

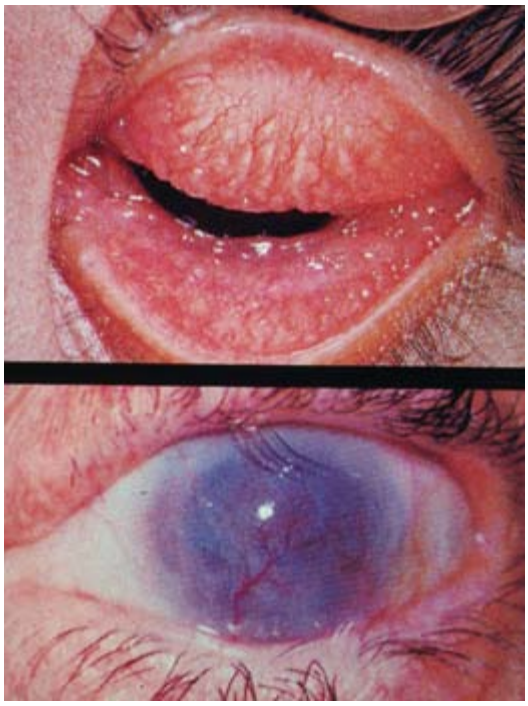

***Chlamydia trachomatis*:**
Note the cornea scarring **(Id217)**

50. Vulvar lymphedema in a patient with lymphogranuloma venereum due to a subtype of *Chlamydia trachomatis*:
LGV initially begins with papules (no ulcers) and then develops granulomatous microabscesses in the inguinal lymph nodes. Lymphatic strictures are common leading to lymphedema. **(Id377)**

Previous | Next

Return to Top | Return to Image Index

Pathology II Images

Infectious Disease: Virus, Chlamydia, Rickettsia, Mycoplasma

It is against copyright laws to make *electronic or printed* copies of these slides!!

Rickettsia

51. *Dermacentor andersoni* tick-vector for Rocky mountain spotted fever: (Id284)

52. Petechial hemorrhages on palms of hand in Rocky mountain spotted fever due to *Rickettsia rickettsii*: In RMSF, the petechial rash begins on the palms and spreads to the trunk **(Id454)**

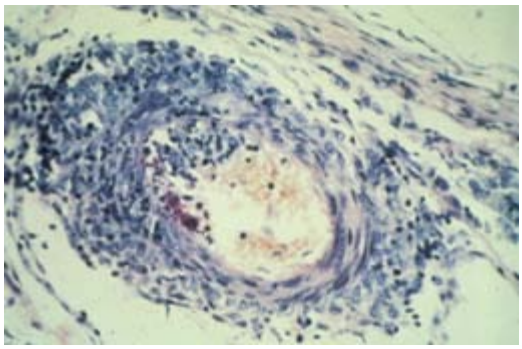

53. Vasculitis of *Rickettsia rickettsii* in Rocky mountain spotted fever: The rickettsial organisms invade the endothelial cells of small vessels producing a vasculitis, which is responsible for the petechial lesions. **(Id446)**

Mycoplasma

54. Chest x-ray with patchy infiltrates of *Mycoplasma pneumoniae* pneumonia: *Mycoplasma* are the smallest free living organisms and the MCC of atypical pneumonia. Note the interstitial

infiltrate in the chest x-ray. Bullous myringitis and a cold autoimmune hemolytic anemia due to anti-I antibodies are complications of this infection. **(Id445)**

Previous | Next

Return to Top | Return to Image Index